

## PAPER DETAILS

TITLE: Reversal of Severe Vasospasm Causing Transradial Angiogram Catheter Entrapment By  
Low Dose Sedation

AUTHORS: Ertugrul ZENCIRCI,Aleks DEGIRMENCIOGLU,Gültekin KARAKUL

PAGES: 110-112

ORIGINAL PDF URL: <http://journal.acibadem.edu.tr/en/download/article-file/1701554>

# Reversal of Severe Vasospasm Causing Transradial Angiogram Catheter Entrapment by Low Dose Sedation

Ertuğrul Zencirci<sup>1</sup>, Aleks Değirmencioğlu<sup>2</sup>, Gültekin Karakul<sup>1</sup>

<sup>1</sup>Acıbadem Maslak Hastanesi, Kardiyoloji Bölümü, İstanbul, Türkiye

<sup>2</sup>Acıbadem Üniversitesi Tıp Fakültesi, Kardiyoloji Anabilim Dalı, İstanbul, Türkiye

## ABSTRACT

One of the major disadvantages of the transradial approach during cardiac interventions is radial artery spasm. Severe vasospasm of the radial artery causing catheter entrapment is less frequently encountered and its management has rarely been reported. Herein, a 72-year-old female patient who was scheduled for an elective left heart catheterization due to exertional angina pectoris is reported. During transradial diagnostic coronary angiography, catheter entrapment occurred due to severe vasospasm of the radial artery. Reversal of severe vasospasm and release of entrapped catheter was not possible until low dose sedation with intravenous midazolam was given. This case report demonstrates that low dose sedation with intravenous midazolam could be used effectively to reverse resistant vasospasm of the radial artery during transradial interventions.

**Key words:** catheter entrapment, sedation, transradial approach

## TRANSRADYAL ANJIOGRAM KATETER TUZAKLANMASINA NEDEN OLAN ŞİDDETLİ VASOSPAZMİN DÜŞÜK DOZ SEDASYON İLE ÇÖZÜLMESİ

### ÖZET

Kardiyak girişimlerde transradyal yaklaşımın önemli dezavantajlarından biri radyal arter spazmidir. Kateter tuzaklanmasına neden olan şiddetli radyal arter vazospazmı daha az sıklıkla görülür ve tedavisi nadiren bildirilmiştir. Yazımızda efor anginası nedeniyle elektif sol kalp kateterizasyonu planlanan 72 yaşında bir kadın hasta bildirildi. Transradyal tanısal koroner anjiyografi esnasında radyal arterin şiddetli vazospazmına bağlı kateter tuzaklanması gelişti. İntravenöz midazolam ile düşük doz sedasyon uygulanana kadar şiddetli vasospazmın gerilemesi ve kateter tuzaklanmasının çözülmesi mümkün olmadı. Bu vaka intravenöz midazolam ile düşük doz sedasyonun transradyal girişimler esnasında oluşan dirençli radyal arter vasospazmının tedavisinde etkili olabileceğini göstermiştir.

**Anahtar sözcükler:** kateter tuzaklanması, sedasyon, transradyal yaklaşım

Radial arteries have become the most popular vascular access route for cardiac catheterizations. Transradial approach is safe and feasible with markedly decreased incidence of major access-related vascular complications compared to the transfemoral approach. However, one of the major disadvantages of radial approach is radial artery spasm (1,2). Radial artery spasm generally causes severe pain and access site crossover (1,3).

## Case report

A 72-year-old female with past medical history of hypertension and hyperlipidemia was admitted to our

hospital with an exertional angina pectoris. She was 165 cm tall and weighed 80 kg. She was scheduled for elective left heart catheterization. A Barbeau's test was performed. A 20-gauge open bore needle was used to enter the right radial artery. A 6Fr short (7 cm) hydrophilic sheath (Radiofocus Introducer II, Terumo, Tokyo, Japan) was introduced. 200 mcg nitroglycerin (NTG, 2 mg verapamil) and 5000 units heparin was injected through the side port of the sheath. Diagnostic universal 5Fr Tiger catheter (Terumo, Leuven, Belgium) was inserted through the sheath to the aortic root over a hydrophilic guidewire without difficulty. Left coronary angiogram was normal. While attempting to engage the right coronary artery, patient complained of severe right forearm pain distal

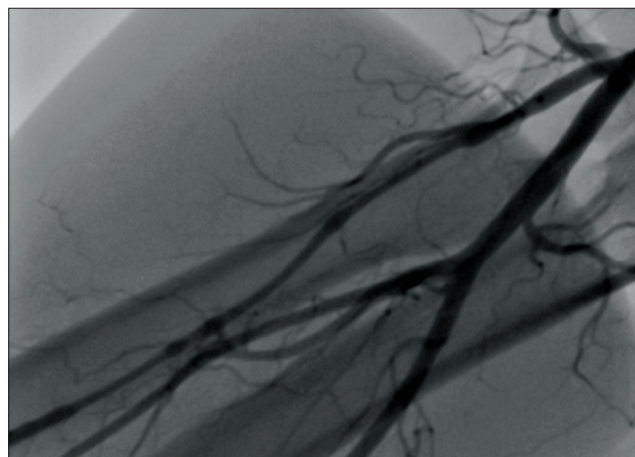
Gönderilme Tarihi: 09 Nisan 2014 • Revizyon Tarihi: 04 Ağustos 2014 • Kabul Tarihi: 11 Eylül 2014  
İletişim: Zencirci Ertuğrul • E-Posta: ertuzencirci@gmail.com

to antecubital fossa and thereafter further manipulation, neither advancement nor retraction of catheter was possible. Forearm angiogram was not possible due to the catheter tip being entrapped in the aortic root. On fluoroscopy, the catheter was found to be neither looped or kinked. It was realized that vasospasm of the radial artery was responsible for the catheter entrapment. Intravenous 200 mcg NTG, 5 mg verapamil and an additional sublingual isosorbiddinitrate (ISDN) 5 mg were all ineffective. Although we waited for 15 minutes, the vasospasm was not resolved. After sedation with intravenous 2 mg midazolam catheter manipulation was possible. We performed a right coronary angiogram revealing significant narrowing of the mid-portion of the right coronary artery (RCA). We then removed the catheter without difficulty. Finally, we performed a forearm angiogram showing only mild vasospasm of the radial artery that persisted after catheter removal (Figure 1). We decided to perform elective percutaneous coronary intervention to RCA. This case describes the successful reversal of rarely seen severe vasospasm causing catheter entrapment with a low dose sedation using intravenous midazolam.

## Discussion

Radial artery is particularly prone to vasospasm because of its muscular nature and  $\alpha$ -adrenoceptor-predominance. Circulating catecholamines mainly activate  $\alpha_1$ -adrenoceptor (4). Some of the patient related factor such as; small size and anomalous origin of the radial artery, female sex, younger age, short stature and anxiety were defined as predisposing factors for radial artery spasm during transradial approach (1,5). In the reported patient the risk factors were female gender and anxiety. Clinical radial artery vasospasm was defined as patient forearm pain during catheter manipulation and/or resistance to catheter manipulation as in our case (6). Various drugs have been extensively evaluated to prevent spasm of radial artery but there is currently no agreement on the optimal agents. Majority of previous reports advocated nitrate derivative and/or verapamil (1,5). In our center, a bolus of 200 mcg of NTG and 2 mg verapamil is routinely given.

Sedation has been suggested as a means to reduce the incidence of spasm because vasospasm can be triggered by procedure-related anxiety and pain. Recently, low doses of an opioid/benzodiazepine (fentanyl/midazolam) combination was reported to be associated with a substantial reduction in the rate of radial artery spasm. (7) But the routine use of sedation during transradial approach has not been a universal practice.



**Figure 1.** A final forearm angiogram visualizing diffuse but not severe vasospasm of radial artery that was still persistent even after catheter removal

Besides the sedative and analgesic action benzodiazepines also have direct vasoactive effects. Midazolam was shown to induce vasodilation and attenuate the vasoconstrictive response to adrenergic stimuli (8,9). Thereby midazolam might have a particular role in the prevention and reversal of vasospasm in the setting of adrenergic overactivation situations, such as cardiac catheterization related stress.

Severe vasospasm of the radial artery, causing catheter entrapment, is very rare. Management of the radial artery vasospasm causing catheter entrapment has not been precisely defined (10). Intraarterial injection of papaverine with lidocaine and general anesthesia were reported to be effective in reversing severe spasm causing catheter entrapment but midazolam was previously reported to be ineffective (11). In our case NTG, ISDN, and verapamil were given before midazolam. Although it is hard to determine which agent was most effective and combination effect might also exist here, we demonstrated that low dose sedation with intravenous midazolam could also be effectively used for the reversal of severe and resistant vasospasm.

## Conclusion

In case of resistant severe radial artery vasospasm causing catheter entrapment, low dose sedation with intravenous midazolam could be used effectively.

## References

1. Kiemeneij F, Vajifdar BU, Eccleshall SC, Laarman G, Slagboom T, van der Wieken R. Evaluation of a spasmolytic cocktail to prevent radial artery spasm during coronary procedures. *Catheter Cardiovasc Interv* 2003;58:281-4.
2. Ho HH, Jafary FH, Ong PJ. Radial artery spasm during transradial cardiac catheterization and percutaneous coronary intervention: incidence, predisposing factors, prevention, and management. *Cardiovasc Revasc Med* 2012;13:193-5.
3. Jolly SS, Amlani S, Hamon M, Yusuf S, Mehta SR. Radial versus femoral access for coronary angiography or intervention and the impact on major bleeding and ischemic events: a systematic review and meta-analysis of randomized trials. *Am Heart J* 2009;157:132-40.
4. He GW, Yang CQ. Characteristics of adrenoceptors in the human radial artery: clinical implications. *J Thorac Cardiovasc Surg* 1998;115:1136-41.
5. Varenne O, Jégou A, Cohen R, Empana JP, Salengro E, Ohanessian A, et al. Prevention of arterial spasm during percutaneous coronary interventions through radial artery: the SPASM study. *Catheter Cardiovasc Interv* 2006;68:231-5.
6. Rathore S, Stables RH, Pauriah M, Hakeem A, Mills JD, Palmer ND, et al. Impact of length and hydrophilic coating of the introducer sheath on radial artery spasm during transradial coronary intervention: a randomized study. *JACC Cardiovasc Interv* 2010;3:475-83.
7. Deftereos S, Giannopoulos G, Raisakis K, Hahalis G, Kaoukis A, Kossyvakis C, et al. Moderate procedural sedation and opioid analgesia during transradial coronary interventions to prevent spasm: a prospective randomized study. *JACC Cardiovasc Interv* 2013;6:267-73.
8. Colussi GL, Di Fabio A, Catena C, Chiuch A, Sechi LA. Involvement of endothelium-dependent and -independent mechanisms in midazolam-induced vasodilation. *Hypertens Res* 2011;34:929-34.
9. Borges AA, Gomes OM. Effects of midazolam on the contraction and relaxation of segments of thoracic aorta stripped of endothelium and stimulated by adrenaline-experimental study in rabbits. *Mol Cell Biochem* 2003;246:13-7.
10. Kallivalappil SC, Pullani AJ, Abraham B, Kumar MK, Ashraf SM. Entrapment of a transradial angiogram catheter because of severe vasospasm. *J Cardiothorac Vasc Anesth* 2008;22:428-30.
11. Pullakhandam NS, Yang ZJ, Thomas S, Wasenko J. Unusual complication of transradial catheterization. *Anesth Analg* 2006;103:794-5.