

## PAPER DETAILS

TITLE: Endometrial Polyp In Early Pregnancy Ending With Term Labor

AUTHORS: Belgin SELAM,Nuri DANISMAN,Süheyla EKEMEN,Ceyda BIRCAN

PAGES: 68-71

ORIGINAL PDF URL: <http://journal.acibadem.edu.tr/en/download/article-file/1701795>

# Endometrial Polyp in Early Pregnancy Ending with Term Labor

Belgin Selam<sup>1</sup>, Nuri Danışman<sup>1</sup>, Süheyla Ekemen<sup>2</sup>, Ceyda Bircan<sup>3</sup>

<sup>1</sup>Acıbadem University School of Medicine, Obstetrics and Gynecology, Istanbul, Turkey

<sup>2</sup>Acıbadem Hospital, Pathology, Istanbul, Turkey

<sup>3</sup>Acıbadem University School of Medicine, Istanbul, Turkey

Belgin Selam, M.D.  
Nuri Danışman, M.D.  
Süheyla Ekemen, M.D.  
Ceyda Bircan, M.D.

## ABSTRACT

Endometrial polyps may be detected by transvaginal ultrasonography (TVS) in early pregnancy. These pregnancies may end with fetal demise. There are not enough data in literature defining term labor in pregnancy with endometrial polyp. The current case describes in detail, the progress of a pregnancy with endometrial polyp including fetal growth, regression of polyp, assessment of placental pathology and postpartum follow-up. Giant endometrial polyp protruding into the uterine cavity adjacent to the gestational sac was detected by TVS in a 31 year-old-primigravida. She delivered a healthy baby and the polyp regressed completely by the end of the pregnancy. Polyps detected in early pregnancy may regress without any effect on the fetal demise or placental insufficiency. Close antenatal follow-up is advised for the prognosis of these pregnancies.

**Keywords:** Endometrial polyp, pregnancy, TVS

## TERM DOĞUMLA SONUÇLANAN GEBELİKTE ERKEN DÖNEMDE İZLENEN ENDOMETRİAL POLİP ÖZET

Endometrial polipler erken gebelikte ultrasonografi ile tespit edilebilir. Bu gebeliklerin fetal kayıpla sonuçlanabileceği düşünülmektedir. Endometrial polip izlenen gebeliklerde term doğumla ilgili literatürde yeterli veri bulunmamaktadır. Vaka sunumumuz, erken dönemde gebelikte izlenen endometrial poliple ilgilidir. Fetal büyüme, polipin gerilemesi, plasenta patolojisinin değerlendirilmesi ve doğum sonrası takip ile gebeliğin seyrini ayrıntılı olarak ele almaktadır. 31 yaşındaki primigravid hastada transvajinal ultrasonografi ile gestasyonel keseye bitişik uterus kavitesine uzanan dev endometrial polip tespit edildi. Hasta, termde sağlıklı bir bebek doğurdu ve polip gebeliğin sonuna kadar tamamen geriledi. Erken gebelikte tespit edilen polipler, fetus kaybı veya plasentada yetmezlik bulguları olmadan gerileyebilir. Bu gebeliklerde doğum öncesi yakın takip önerilir.

**Anahtar sözcükler:** Endometrial polip, gebelik, ultrasonografi

## Correspondence:

M.D. Belgin Selam

Acıbadem University School of Medicine,  
Obstetrics and Gynecology, Istanbul, Turkey

**Phone:** +90 216 649 46 20

**E-mail:** bselam@hotmail.com

**Received :** July 15, 2018

**Revised :** August 01, 2018

**Accepted :** August 02, 2018

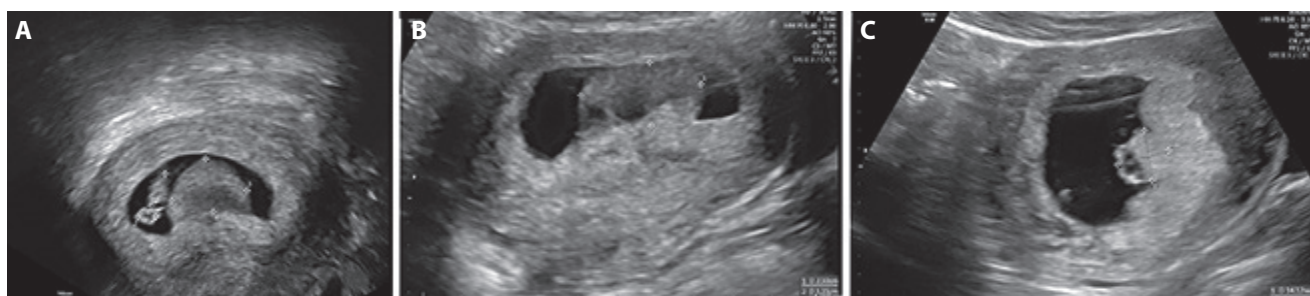Endometrial polyps are localized overgrowths of glands and stroma within the inner lining of the uterus. Cytogenetic modifications on chromosomes 6, 7, 12 and epigenetic factors involving enzyme and metabolic activities are suggested for the etiology (1). Endometrial polyps are more frequently observed in patients with endometriosis (2). They are common among women at reproductive ages. Heavy menstrual bleeding, spotting between menstrual periods, infertility and early pregnancy loss are common presentations (3). Most of the endometrial polyps are considered as benign lesions. Transvaginal ultrasonography (TVS) is considered the gold standard method for the detection of polyps. There are many reports in the literature regarding endometrial polyps identified with TVS in non-pregnant women as they may impair fertilization and embryo implantation (2,3).

Endometrial polyps in the first trimester of pregnancy may be associated with embryo demise (4). To our knowledge, there has been only one report in the literature defining ultrasonographic detection of endometrial polyps in early pregnancy (4). Submucous uterine fibroids, focal adenomyosis, complete hydatidiform mole, mesenchymal dysplasia of the placenta may be considered for the differential diagnosis of polyps in early pregnancy (4). The current case report describes a case of endometrial polyp diagnosed in early pregnancy which ended with term live birth. We describe the progress of the pregnancy in detail including fetal growth, regression of polyp, assessment of placental pathology and postpartum follow-up.

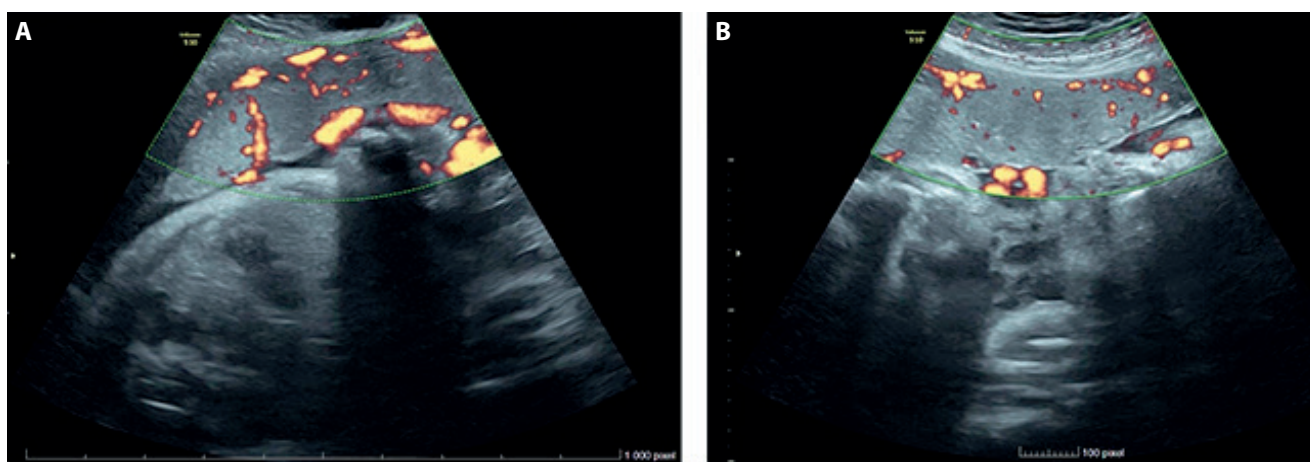
### Case report

A 31 year old woman, gravida 1, para 0, presented at 7 weeks after her last menstrual period for initial pregnancy examination. She had no complaint of pain or bleeding. She had no history of surgical procedures. TVS demonstrated 6 weeks and 4 days embryo with fetal heartbeat and a yolk sac of 3.9 mm diameter within the intrauterine gestational sac. A hyperechoic mass of 16x12 mm

originating from the anterior uterine wall was protruding into the uterine cavity adjacent to the gestational sac (Figure 1a). We did not observe any vascularity with Color and Power Doppler. The endometrial polyp was suspected. The polyp was not observed in the previous examinations before pregnancy. She was consulted with perinatology. The patient was informed about the possibility of fetal demise and was invited for a weekly follow-up. The hyperechoic structure was measured as 25x14 mm by 9 weeks of gestation (Figure 1b). The polyp regressed as a 14x14 mm hyperechoic structure at 10 weeks of gestation (Figure 1 c). Double screening test at 12 weeks of gestation was negative with risks below cut off levels. Free bhCG was 59.00 ng/ml (1.42 MoM) and PAPP-A was 6.04 mIU/ml (1.95 MoM) at the double screening. The polypoid structure was observed as a small irregularity at the corner of the placenta which inserted in the anterior wall of the uterus by 19 weeks of gestation. The placenta was thoroughly normal in appearance by 36 weeks of gestation (Figure 2a, b). Fetal growth was consistent with gestational age throughout the pregnancy. The patient delivered a healthy baby by cesarean section at 39 weeks of gestation. The uterine cavity was assessed carefully; we did not

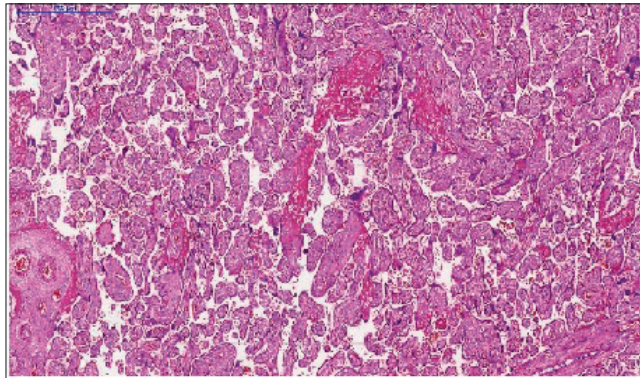


**Figure 1.** A. Endometrial polyp by TVS at 7 weeks of gestation. B. Endometrial polyp by TVS at 9 weeks of gestation. C. Endometrial polyp by TVS at 10 weeks of gestation.

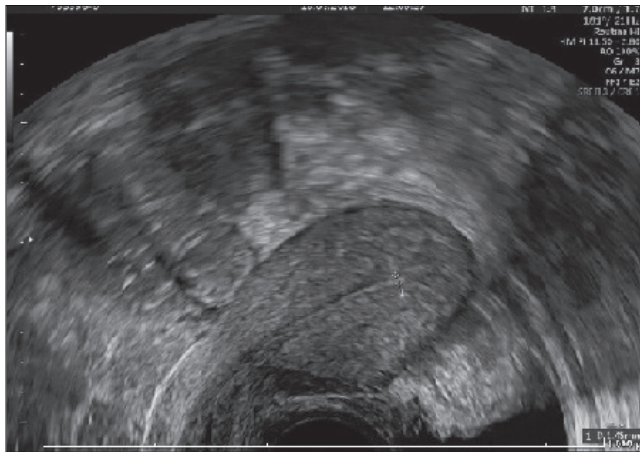


**Figure 2.** A, B. TVS examination of placenta by 36 weeks of pregnancy.

observe any sign of polypoid structure. Macroscopic and microscopic assessment of the placenta did not demonstrate any polyp structure (Figure 3). TVS examination of the patient did not demonstrate any polyp, 2 months after the delivery (Figure 4).



**Figure 3.** Postpartum placental examination, The histological structure of the placenta by light microscopy hematoxylin eosin staining, CaseViewerX10 magnification.



**Figure 4.** TVS examination of the uterine cavity postpartum, 2 months after the delivery.

## Discussion

Endometrial polyps are mostly benign incidental findings detected by TVS. Most of the endometrial polyps are located on the posterior uterine wall (5). The excision of polyps that are located at the utero-tubal junction significantly improves pregnancy rates (5). The polyp was

located on the anterior wall of the uterus in the current study and had no effect on the outcome of the pregnancy.

To our knowledge, there is only one case report concerning endometrial polyps that coexist with early pregnancy (4). Memtsa et al. report ten cases of polyps diagnosed in the first trimester of pregnancy which were followed-up during the perinatal period (4). Most of them had the diagnosis of polyp before pregnancy while four of them did not have a pre-conceptional polyp. Although half of the cases ended with fetal demise, the rest of the patients delivered healthy babies. In the current study, the patient had a normal antenatal course despite the large mass, which regressed in size during the follow-up. The patient had no history of endometrial polyp before conception. We did not observe any intrauterine fetal growth restriction during routine antenatal care. Placental examination after birth demonstrated normal findings without any polypoid structure. A postpartum scan did not demonstrate any polyp, 2 months after the delivery.

Small polyps may regress spontaneously in some cases (6, 7). Polyp regression rate was observed as 27% among women aged 45–50 years during 1 year of follow-up (6). To our knowledge, there are not enough data in literature describing the regression of endometrial polyp diagnosed in early pregnancy. The current case report is a novel observation describing the regression of the polyp by the progression of the pregnancy as term labor, including fetal growth, assessment of placental pathology and postpartum follow-up.

In conclusion, endometrial polyps may be detected by TVS during the first trimester of pregnancy. There are no clear data about pregnancy, abortion rates in patients with endometrial polyps; therefore, pregnancy is not terminated. Polyps may regress throughout the pregnancy. They may not impair implantation and placentation. Polyps in early pregnancy may not lead to early pregnancy failure or placental insufficiency. Routine antenatal follow-up should be arranged as pregnancies may end with normal term labor despite the presence of endometrial polyp in early pregnancy. A follow-up scan is necessary after the delivery, for the management of polyps.

## References

1. Tanos V, Berry KE, Seikkula J, Abi Raad E, Stavroulis A, Sleiman Z, et al. The management of polyps in female reproductive organs. *Int J Surg* 2017;43:7–16. [\[CrossRef\]](#)
2. Pérez-Medina T, Bajo-Arenas J, Salazar F, Redondo T, Sanfrutos L, Alvarez P, Engels V. Endometrial polyps and their implication in the pregnancy rates of patients undergoing intrauterine insemination: a prospective, randomized study. *Hum Reprod* 2005;20:1632–35. [\[CrossRef\]](#)
3. Afifi K, Anand S, Nallapeta S, Gelbaya TA. Management of endometrial polyps in subfertile women: a systematic review. *Eur J Obstet Gynecol Reprod Biol* 2010;151:117–21. [\[CrossRef\]](#)
4. Memtsa M, Jauniaux E, Wong M, Jurkovic D. Ultrasound diagnosis of endometrial polyps in pregnancy. *Ultrasound Obstet Gynecol* 2018;52:548–9. [\[CrossRef\]](#)
5. Yanaihara A, Yorimitsu T, Motoyama H, Iwasaki S, Kawamura T. Location of endometrial polyp and pregnancy rate in infertility patients. *Fertil Steril* 2008;90:180–82. [\[CrossRef\]](#)
6. Lieng M, Istre O, Sandvik L, Qvigstad E. Prevalence, 1-year regression rate, and clinical significance of asymptomatic endometrial polyps: cross-sectional study. *J Minim Invasive Gynecol* 2009;16:465–71. [\[CrossRef\]](#)
7. DeWaay DJ, Syrop CH, Nygaard IE, Davis WA, Van Voorhis BJ. Natural history of uterine polyps and leiomyomata. *Obstet Gynecol* 2002;100:3–7. [\[CrossRef\]](#)