

PAPER DETAILS

TITLE: AN INTRAABDOMINAL ABSCESS AND PLEURAL EFFUSION AFTER CYTOREDUCTIVE SURGERY AND HIPEC

AUTHORS: Bülent KAYA,Nuriye ESEN,Orhan BAT,Aziz SENER,Azime CEZİK

PAGES: 64-66

ORIGINAL PDF URL: <https://dergipark.org.tr/tr/download/article-file/419443>

AN INTRAABDOMINAL ABSCESS AND PLEURAL EFFUSION AFTER CYTOREDUCTIVE SURGERY AND HIPEC

Sitoredüktif cerrahi ve HIPEC sonrası gelişen bir intraabdominal apse ve plevral efüzyon olgusu

Bülent Kaya¹, Nuriye Esen², Orhan Bat¹, Aziz Şener¹, Azime Cezik¹

Kanuni Sultan Süleyman Training and Research Hospital, Department of General Surgery¹
Fatih Sultan Mehmet Training and Research Hospital, Department of General Surgery² İstanbul

Corresponding address: Dr. Bülent Kaya, drbkaya@yahoo.com

J Surg Arts (Cer San D), 2015(2): 64-66.

ABSTRACT

Cytoreductive surgery with hyperthermic intraperitoneal chemotherapy (HIPEC) has become a new treatment option in last years form any patients with peritoneal metastasis. In this case report, a 42 years old women was operated by gynecologists due to pelvic mass. On exploration, there was huge intraabdominal, omental mass with malignant appreance. There were multiple metastatic lesions on peritoneal surface sand in all colon mesentery. Subtotal colectomy, omentectomy, peritonectomy, splenectomy, cholecystectomy and resection of omentum minus were performed. After cytoreductive surgery, HIPEC with cisplatin was used. There were an intraabdominal abscess and pleural effusion which were treated hardly. In conclusion, CRS and HIPEC are becoming a more commonly performed treatment modalities in patients with peritoneal carcinomatosis. Pulmonary effusion and resistant intraabdominal infections can be important problems in postoperative period.

Key words: Cytoreductive surgery, HIPEC, complication.

ÖZET

Sitoredüktif cerrahi ve hipertermik intraperitoneal kemoterapi son yıllarda peritoneal metastazı olan hastalarda yeni bir tedavi seçeneği olmuştur. Bu olgu sunumunda 42 yaşında bayan hasta pelvik kitle nedeni ile kadın hastalıkları ekibi tarafından opere edilmisti. Eksplorasyonda karın içinde malign görünümlü büyük bir kitle tespit edildi. Kolon mezenter ve peritonda multipl metastatik lezyonlar mevcuttu. Subtotal kolektomi, omentektomi, peritonektomi, splenektomi, kolesistektomi ve omentum minus eksizyonu yapıldı. Sitoredüktif cerrahi sonrası HIPEC uygulandı. Postoperatif dönemde zorlukla tedavi edilen intraabdominal apse ve plevral efüzyon görüldü. Sonuçta sitoredüktif cerrahi ve HIPEC son yıllarda peritoneal karsinomatozada daha sık uygulanır hale gelmiştir. Plevral efüzyon ve intraabdominal apse gelişimi postoperatif dönemde önemli problemler olabilir.

Anahtar kelimeler: Sitoredüktif cerrahi, HIPEC, komplikasyon.

INTRODUCTION

Gastrointestinal and gynecological malignancies in advanced stages have the potential to metastasis in the peritoneal cavity. This condition is known as peritoneal carcinomatosis (PC). In most of the cases, treatment modalities are limited and PC is associated with poor prognosis. Cytoreductive surgery with hy-

perthermic intraperitoneal chemotherapy (HIPEC) has become a new treatment option in last years, for many tumors (like Apendiceal, ovarian, colon and gastric tumors) presented with PC. The first clinical study with HIPEC was reported by Spratt et al 1980 (1). Cytoreductive surgery was populirezed by Sugarbaker. It aims total or near total eradication of intraperi-

toneal metastasis. As a major surgical procedure, cytoreductive surgery and (HIPEC) is associated with some complications. Most of the complications are related with either cytoreductive surgery or intraperitoneal chemotherapy. In this case report, we presented a patient who was operated with PC due to ovarian carcinoma. Cytoreductive surgery and HIPEC was performed. An intraabdominal abscess and pleural effusion were detected as important complications after surgery.

Case

A 42 years old women was operated by gynecologists due to pelvic mass. On exploration there was huge intraabdominal, omental mass with malignant appearance (Figure 1). The frozen section was reported as carcinoma metastasis. There were multiple metastatic lesions on peritoneal surface and in all colon mesentery. The omentum minus and spleen was also invaded by metastatic lesions. The operation team was decided to perform cytoreductive surgery and HIPEC. Subtotal colectomy, omentectomy, peritonectomy, splenectomy, cholecystectomy and resection of omentum minus were performed. After cytoreductive surgery, HIPEC with cisplatin was done. The perioperative period was uneventful.

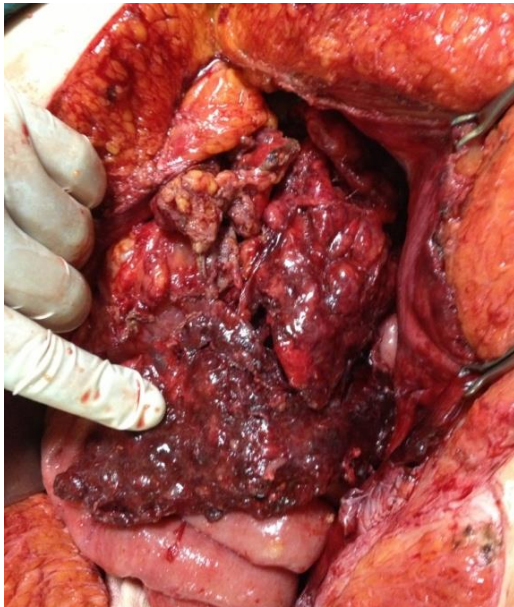


Figure 1: Intraabdominal appearance of omental metastasis before cytoreductive surgery.

In early postoperative period, the patient was followed in intensive care unit. In third postoperative day, a right pleural effusion was detected in both thorax graphy and computed tomography (CT) (Figure 2,3). Pleural drainage was performed and about 1000 ml serous fluid collection was drained (Figure 4). The patient was sent to our clinic in 5. Postoperative day. In this period, a fever about 38 to 38.5°C was seen. The abdominal CT was showed a left upper quadrant abscess approximately 4x3 cm in diameter in splenic-

tomy region. The abscess was percutaneously drained under BT guidance. In control CT, there was a minimum collection about 3x2 mm in diameter. The further intervention was not suggested by radiologists. The patient was followed up with antibiotherapy. There was also minimal pleural effusion with no clinical symptoms.

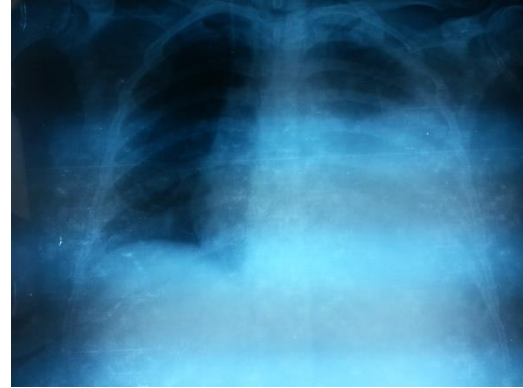

Figure 2: A left pleural effusion in thorax x-ray.

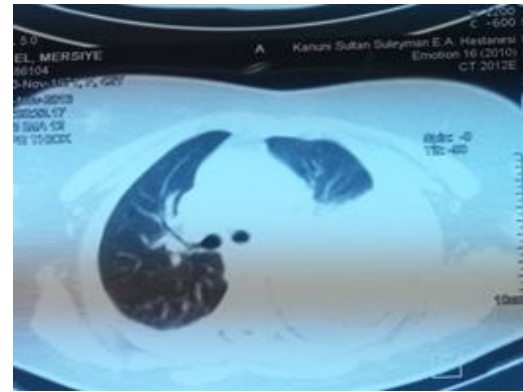


Figure 3: Left sidepleural effusion in thorax CT.

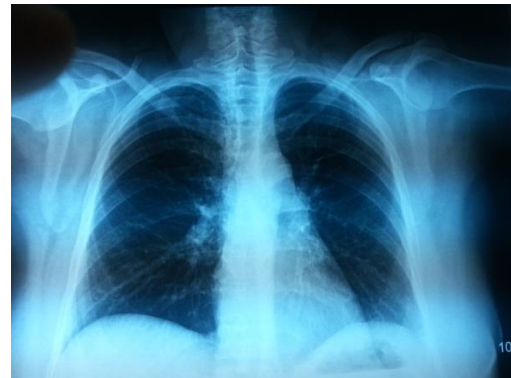

Figure 4: Treated effusion in thorax x-ray.

DISCUSSION

Today, CRS and HIPEC have become a treatment option for selected patients with PC. It has a 5-year survival rate of 73% in pseudomyxoma peritonei (2), 45% in PC of colon cancers (3), and 27% in PC of gastric malignancy (4). The most important preventive factor for wide usage of this modality is, its high morbidity and mortality rates. The mortality rate after CRS and HIPEC has been reported between 0.9% to

5.8% in different serials. The morbidity rates ranges from 12% to 52% (5).

Pleural effusion is a common complication after CRS and HIPEC. Resection of hemidiaphragm is an important predisposing factor for pleural effusion. Intraperitoneal chemotherapeutic solution can easily pass through weakened diaphragm. Preti et al studied pulmonary complications (respiratory distress, pleural effusion, and pneumonia) in 147 patient swith PC due to appendiceal and colorectal malignancy (6). This study was the most comprehensive serial about pulmonary complications after CRS and HIPEC and pulmonary complications were detected in 10% of patients. There were 10 patients with pleural effusion, 9 with respiratory distressand 7 with pneumonia. Three of the patients with pleural effusion was needed a chest tube insertion. Two patients with respiratory stress were managed with tracheostomy. Our patient was also treated with chest tube drainage after detection of pleural effusion.

CRS associated complications are postoperative ileus, anastomotic leakage, wound infection intra-abdominal abscess, bleeding, thromboembolic events. HIPEC can also cause to leucopenia, anemia, thrombocytopenia, solid organ toxicity and other side effects. Intractable splenic abscess was an important problem in ourpatient. Although this abscess was drained percutaneously there was a collection in follow up which was continued to treat by antibiotherapy. Splenic metastasis from ovarian carcinoma is rare clinical entity. Most of the time splenic metastasis are associated with widespread systemic disease. Hanprasertpong et al reported 6 patients who were treated with CRS and splenectomy due to ovarian carcinoma (7). There was no major morbidity or mortality in these patients. There was increased in thrombocyte count (above 1.000.000) in postoperative period in our patient which was treated with 250 mgr/day asetyl salicylic acid.

In conclusion, CRS plus HIPEC is becoming a more commonly performed treatment modality. It

has well-known complications. Pulmonary effusion and intraabdominal infections can be important problems in postoperative period.

REFERENCES

1. Spratt JS, Adcock RA, Muskovin M, Sherrill W, McKeown J. Clinical delivery system for intraperitoneal hyperthermic chemotherapy. *Cancer Res* 1980;40:256-60.
2. Elias D, Gilly F, Quenet F et al. Pseudomyxoma peritonei: a French multicentric study of 301 patients treated with cytoreductive surgery and intraperitoneal chemotherapy, *Eur J Surg Oncol*. 2010; 5:456-62.
3. Sugarbaker PH. Peritoneal surface oncology: review of a personal experience with colorectal and appendiceal malignancy, *Techniques in Colo-proctology* 2005;2:95-103.
4. Yonemura Y, Endou Y, Shinbo M et al. Safety and efficacy of bidirectional chemotherapy for treatment of patients with peritoneal dissemination from gastric cancer: selection for cytoreductive surgery, *J Surg Oncol*. 2009;4:311-6.
5. Chua TC, Yan TD, Saxena A, Morris DL. Should thetreatment of peritoneal carcinomatosis by cytoreductive surgery and hyperthermic intraperitoneal chemotherapy stil be regarded as a highly morbid procedure?: a systematic review of morbidity and mortality. *Ann Surg*. 2009;6:900-7.
6. Preti V, Chang D, Sugarbaker PH. Pulmonary complications following cytoreductive surgery and perioperative chemotherapy in 147 consecutive patients. *Gastroenterol Res Pract*. 2012;2012: 635314.
7. Hanprasertpong J, Ohishi R, Iwasa N, Nagao S, Okamoto K, Fujiwara K. Splenectomy during secondary cytoreductive surgery for epithelial ovarian cancer. *Asian Pac J Cancer Prev*. 2010;11: 413-6.