

## PAPER DETAILS

TITLE: Hand orf infection in a medical student after sacrifice feast

AUTHORS: Bülent GÜNERİ,Murat ÜZEL,Mustafa KINAS

PAGES: 168-170

ORIGINAL PDF URL: <https://dergipark.org.tr/tr/download/article-file/491401>

# Hand Orf infection in a medical student after Sacrifice Feast

## Tıp fakültesi öğrencisinde Kurban Bayramı sonrası elde Orf enfeksiyonu

Bülent Güneri,<sup>1</sup> Murat Üzel,<sup>1,2</sup> Mustafa Kınaş<sup>3</sup>

<sup>1</sup>Department of Orthopedics and Traumatology, Kahramanmaraş Sütçü İmam University Faculty of Medicine, Kahramanmaraş, Turkey

<sup>2</sup>Department of Hand Surgery, Kahramanmaraş Sütçü İmam University Faculty of Medicine, Kahramanmaraş, Turkey

<sup>3</sup>Department of Orthopedics and Traumatology, Dr. Selahattin Cizrelioğlu State Hospital, Şırnak, Turkey

### Abstract

Human orf infection – caused by Parapox virus – is an uncommon zoonotic infection transmitted from infected sheep and goats. We report an Orf lesion which occurred on the ring finger of a fifth-grade Medical student who had butchered a goat in Sacrifice Feast (also called Eid al-Adha). 23 year old male student in fifth-grade of Medical Faculty was diagnosed with hand orf infection after Sacrifice Feast. The patient reported accidental cut on his left ring finger while butchering a goat which was subsequently recognized to be infected. After occurrence of the Orf lesion, he had administered intervention with a sterile syringe needle to remove the scab for drainage due to false impression of abscess formation despite warnings. The patient was treated with daily wound care and regular outpatient visits. Although mild scarring remained owing to intervention administered by the patient, Orf lesion healed well after seven weeks from admission. The patient was complaint free after 18 months from admission. Finger posture, range of motion, sensation were normal. An Orf lesion developing on the hand skin of a medical student and his approach to a zoonotic infection raised the idea that further and detailed education for zoonotic infection prevention is required, particularly in communities which practice large numbers of slaughtering during Sacrifice Feast. Mode and control of zoonotic disease transmission as well as preventive measures and management should be emphasized not only in veterinarian education, but also in medical, nursing and public schools.

**Keywords:** Ecthyma contagiosum virus; poxvirus infections; zoonotic infections.

### Özet

Parapox virüsünden kaynaklanan insan Orf enfeksiyonu sık görülmeyen, enfekte koyun ve keçilerden bulaşan zoonotik bir hastalıktır. Bu yazıda Kurban Bayramı'nda keçi kesen beşinci sınıf Tıp Fakültesi öğrencisinin yüzük parmağında meydana gelen Orf lezyonu bildirilmektedir. Yirmi üç yaşındaki erkek, beşinci sınıf Tıp Fakültesi öğrencisi Kurban Bayramı'ndan sonra elde Orf enfeksiyonu nedeni ile başvurdu. Hastanın ifadesine göre enfekte olduğu sonradan anlaşılan keçiyi kurban ederken kazara sol el yüzük parmağını kesmesi sonucunda meydana gelmiş. Lezyonun ortaya çıkmasından sonra uyarılara rağmen parmağında abse oluştuğunu düşünerek, drenaj amaçlayarak steril enjektör ucu ile lezyonun üstündeki kabuğu kaldırmış. Başvurusundan sonra hasta günlük yara bakımı ve ayaktan takip ile tedavi edildi. Hastanın müdahalesine bağlı olarak gelişen hafif skar oluşumuna rağmen başvurudan sonraki yedi haftalık sürede Orf lezyonu sorunsuz olarak iyileşti. İlk başvurusundan 18 ay sonra yapılan kontrolünde şikayeti olmayan hastanın parmak hareketleri, duygusu ve duruşu doğal idi. Tıp fakültesi öğrencisinin elinde Orf enfeksiyonu meydana gelmesi ve zoonotik enfeksiyon oluşumu sonrası uygun olmayan yaklaşımı, bu enfeksiyonlara yaklaşımla ilgili olarak daha detaylı eğitimin özellikle de Kurban Bayramı'nda çok sayıda küçükbaş hayvan kesimi gerçekleştiren toplumlarda verilmesi gerektiğini işaret etmektedir. Zoonotik hastalık geçişinin kontrolü, alınması gereken önlemler ve tedavisi Veterinerlik Okulları'nın yanı sıra Tıp Fakülteleri, Hemşirelik ve Sağlık Meslek Okulları dahil olmak üzere diğer eğitim kurumlarında da iyi vurgulanmalıdır.

**Anahtar Sözcükler:** Bulaşıcı ektima virüsü; poksivirüs enfeksiyonları; zoonozlar.

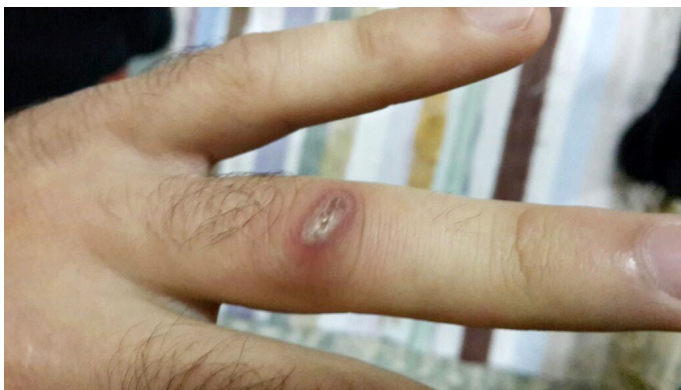Human orf infection is an uncommon zoonotic infection transmitted from infected sheep and goats. The causative agent is dermatropic Parapox virus. Although known as occupational infection, any person who directly contacts infected

animals, meat or materials is prone to acquire the disease (1-4). We report an Orf lesion which occurred on the finger of a fifth-grade Medical student who had butchered a goat in Sacrifice Feast (also called Eid al-Adha).

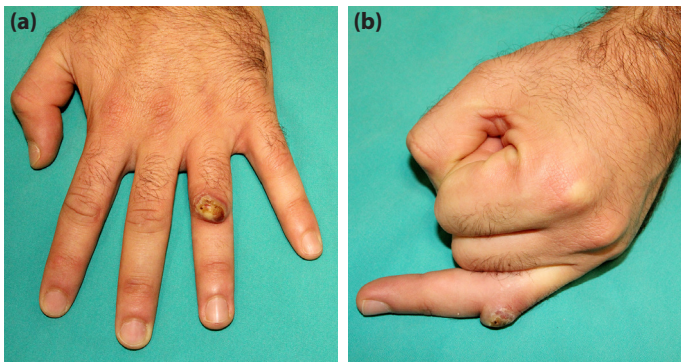


## Case Report

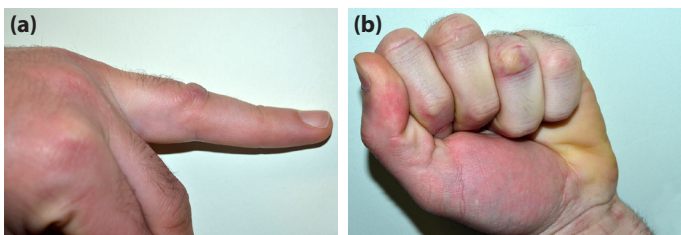
Twenty-three year old male student in fifth-grade of Medical Faculty, was admitted to the Hand Surgery Clinic due to a skin lesion on his left ring finger. The patient mentioned that 20 days before admission, he had slaughtered a goat with the help of two relatives on the first day of Sacrifice Feast, one of Muslim holidays. He reported an accidental cut on dorsal aspect of his left ring finger (Fig. 1). He had managed bleeding with mild compression, wrapped the wound with adhesive plaster after checking active finger motions which was normal and continued meat processing. He mentioned appearance of a dark brown colored, circular, bulging lesion on the wounded skin six days after the injury and no associated fever or lethargy. He had already applied to Dermatology and Infectious Disease



**Figure 1.** Skin cut on the day of injury. The photograph was taken by the patient with his phone camera.



**Figure 2.** Nodular, crusted Orf lesion of the left ring finger on admission. Dorsal view (a). Lateral view (b).



**Figure 3.** Final follow-up with full range of motion achieved despite mild scarring. Lateral view of the ring finger depicting full extension (a). Dorsal view of the fingers depicting excellent fist position (b).

Clinics for the painless, enlarging skin lesion. Although informed about the benign character of human orf lesion and instructed to carry out daily care of the lesion with regular outpatient visits, the patient had administered intervention with a sterile syringe needle to remove the scab for drainage due to false impression of abscess formation given by the lesion. He mentioned no drainage from the lesion with squeezing.

A nodular, crusted skin lesion approximately one cm in diameter with the appearance of dark brown-colored strawberry on the dorsal aspect of proximal interphalangeal joint of the left ring finger was detected on admission to Hand Surgery Clinic (Fig. 2). Range of motion as well as sensation of the finger were unaffected by the lesion. There was no axillary lymphadenopathy, erythema nor edema around the lesion. With regard to typical history and physical examination, hand orf infection was diagnosed. The patient was informed about the etiology, natural history and management of the disease. The treatment was arranged as daily wound care with sterile dressing for isolation of the once uncovered orf lesion and weekly regular outpatient visits. Each examination included evaluation of the lesion in terms of healing and infection signs as well as finger range of motion, active extension strength and sensation of the finger. Although mild scarring remained owing to intervention administered by the patient, Orf lesion healed well after seven weeks from admission. Subsequently, the patient visited Hand Surgery Clinic regularly every three months. At the last follow-up which was 18 months after admission, the patient was complaint free. Finger posture, range of motion, sensation were normal (Fig. 3).

## Discussion

Orf infection is both an animal and human health problem. Human orf disease develops after contact with infected small ruminants (i.e. sheep, goats). Despite being a preventable zoonotic disease, human orf infections still occur as sporadic cases.<sup>[1-4]</sup> Diagnosis is uncomplicated since history and physical examination are typical. Although not routinely appealed, electron microscopic or PCR analysis of lesion scab confirms the diagnosis of orf infection which can be misinterpreted as cutaneous anthracosis by the inexperienced clinicians.<sup>[2,3,5,6]</sup> Differential diagnosis includes milker's nodule, pyogenic granuloma and cowpox as well.<sup>[2,7]</sup> Generally, single orf lesion occurs on the previously damaged skin after an incubation period of two days to one week. However, multiple lesions have been reported.<sup>[7,8]</sup>

Human orf infection is generally managed by conservative measures such as lesion care, sterile dressing and heals uneventfully with healthy, scar-free skin. Regular visits during infection period and after healing are essential. Surgical intervention is unnecessary and contraindicated.<sup>[2]</sup> Although rare, complications such as extensor tendon rupture due to giant orf lesion on dorsal aspect of finger have been reported.<sup>[9]</sup>

Even though recognized to be an occupational zoonotic dis-

ease among farmers and butchers, any person who contacts with infected sheep or goat as well as contaminated meat or materials is at risk for developing Orf infection.<sup>[1-4]</sup> Human orf disease often occurs in Muslim population after Sacrifice Feast despite preventive regulations because large numbers of ruminants are slaughtered within three days of Sacrifice Feast. The preventive regulations include standards for animal care, veterinarian control, slaughtering and meat processing by professional employees who are trained for hand hygiene and barrier precautions against zoonotic infections.<sup>[3,4,7]</sup>

An Orf lesion developing on the hand skin of a medical student – to our knowledge, the first report on Orf infection occurring in a healthcare member – and his approach to a zoonotic infection raised the idea that further and detailed education for zoonotic infection prevention is required, particularly in communities which practice large numbers of slaughtering during Sacrifice Feast. Mode and control of zoonotic disease transmission as well as preventive measures and management should be emphasized not only in veterinarian education, but also in medical, nursing and public schools.

**Conflict of interest:** There are no relevant conflicts of interest to disclose.

## References

1. Nougairède A, Fossati C, Salez N, Cohen-Bacrie S, Ninove L, Michel F, et al. Sheep-to-Human Transmission of Orf Virus during Eid al-Adha Religious Practices, France. *Emerg Infect Dis* 2013;19:102–5.
2. Uzel M, Sasmaz S, Bakaris S, Cetinus E, Bilgic E, Karaoguz A, et al. A viral infection of the hand commonly seen after the feast of sacrifice: human orf (orf of the hand). *Epidemiol Infect* 2005;133:653–7.
3. Centers for Disease Control and Prevention (CDC). Orf virus infection in humans--New York, Illinois, California, and Tennessee, 2004–2005. *MMWR Morb Mortal Wkly Rep* 2006;55:65–8.
4. Centers for Disease Control and Prevention (CDC). Human Orf virus infection from household exposures - United States, 2009–2011. *MMWR Morb Mortal Wkly Rep* 2012;61:245–8.
5. Maki A, Hinsberg A, Percheson P, Marshall DG. Orf: contagious pustular dermatitis. *CMAJ: Canadian Medical Association Journal* 1988;139:971–2.
6. Gallina L, Dal Pozzo F, Mc Innes CJ, Cardeti G, Guercio A, Battilani M, et al. A real time PCR assay for the detection and quantification of orf virus. *J Virol Methods* 2006;134:140–5.
7. Al-Salam S, Nowotny N, Sohail MR, Kolodziejek J, Berger TG. Ecthyma contagiosum (orf)-report of a human case from the United Arab Emirates and review of the literature. *J Cutan Pathol* 2008;35:603–7.
8. Sasmaz S, Uzel M, Sener S, Ucmak H. Rare presentation of human orf as multiple lesions. *J Dermatol* 2011;38:825–6.
9. Uzel M, Sasmaz S, Ozkul A, Cetinus E, Bilgic E, Karaoguz A. Swan-neck deformity and paresthesia following giant orf. *J Dermatol* 2004;31:116–8.