

## PAPER DETAILS

TITLE: The Effect of Serum Igf-1,Igfbp-3 And Erythrocyte Transfusions on Development of Mild Retinopathy of Prematurity

AUTHORS: Davut BOZKAYA,Ebru ERGENEKON,Aysegul YUCEL,Sengul OZDEK,Ibrahim HIRFANOGLU,Ozden TURAN,Canan TURKYILMAZ,Esra ONAL,Esin KOC,Yildiz ATALAY

PAGES: 9-14

ORIGINAL PDF URL: <https://dergipark.org.tr/tr/download/article-file/676306>



# The effect of serum IGF-1, IGFBP-3 and erythrocyte transfusions on development of mild retinopathy of prematurity

## Serum IGF-1, IGFBP-3 düzeylerinin ve eritrosit transfüzyonunun prematüre retinopatisi üzerine etkisi

<sup>1</sup> Davut Bozkaya, <sup>2</sup> Ebru Ergenekon, <sup>2</sup> Ayşegül Yücel, <sup>3</sup> Şengül Özdek, <sup>4</sup> İbrahim Hirfanoğlu, <sup>2</sup> Özden Turan, <sup>2</sup> Canan Turkyılmaz, <sup>2</sup> Esra Önal, <sup>2</sup> Esin Koç, <sup>2</sup> Yıldız Atalay

<sup>1</sup>Department of Pediatrics, Gazi University Hospital, Ankara, Turkey

<sup>2</sup>Division of Newborn Medicine, Department of Pediatrics, Gazi University Hospital, Ankara, Turkey

<sup>3</sup>Department of Immunology, Gazi University Hospital, Ankara, Turkey

<sup>4</sup>Department of Ophthalmology, Gazi University Hospital, Ankara, Turkey

### Abstract

**Introduction:** Most important factors in retinopathy of prematurity (ROP) are prematurity and oxygen toxicity although blood transfusions, insulin like growth factor-1 (IGF-1), insulin like growth factor binding protein 3 (IGFBP-3) and vascular endothelial growth factor (VEGF) also have important roles. The objectives of this study were, to measure IGF-1 and IGFBP-3 levels in preterm newborns before and after blood transfusion and assess if the effect of transfusion in development of ROP is via these mediators, and to investigate whether IGF-1 and IGFBP-3 levels measured at 32 and 33 gestational age (GA) were different in preterm newborns with and without ROP.

**Methods:** Preterm newborns with gestational age  $\leq 34$  weeks were included and blood samples were obtained before and after red blood cell (RBC) transfusion.

**Results:** Thirty newborns were included, 17 of whom had ROP (stage 1: n=11, stage 2: n=5, stage 3: n=1). IGF-1 and IGFBP-3 levels did not change after RBC transfusion. Excluding the patient with stage 3 ROP all ROP patients were referred as mild ROP. No difference was observed between IGF-1 and IGFBP-3 levels of the patients with and without mild ROP. Patients with mild ROP had significantly more number of transfusions.

**Discussion and Conclusion:** Erythrocyte transfusion increased the frequency of ROP, whereas IGFBP-3 and IGF-1 were not associated of ROP.

**Keywords:** Retinopathy of prematurity; IGF-1; IGFBP-3; transfusion.

### Özet

**Amaç:** Prematüre retinopatisi (ROP) gelişmesinde en önemli faktör prematürite ve oksijen toksisitesi olmasına rağmen tekrarlayan kan transfüzyonları, insülin benzeri büyüme faktörü-1 (IGF-1), insülin benzeri büyüme faktörü bağlayıcı protein 3 (IGFBP-3) ve vasküler endotel büyüme faktörlerinin (VEGF) ROP gelişimi üzerine etkilerinin olduğu düşünülmektedir. Bu çalışmanın amacı, preterm yenidoğanlarda kan transfüzyonu öncesi ve sonrası IGF-1 ve IGFBP-3 seviyelerini ölçmek ve 32 ve 33 gebelik yaşlarında (GA) ölçülen IGF-1 ve IGFBP-3 düzeylerinin ROP olan ve olmayan preterm yenidoğanlarda farklı olup olmadığını araştırmak ve ROP gelişiminde transfüzyonun etkisinin bu mediatörler yoluyla olup olmadığını değerlendirmek ve IGF-1 ve IGFBP olup olmadığını araştırmaktır. 32 ve 33 gebelik yaşlarında (GA) ölçülen -3 seviyeleri, ROP olan ve olmayan preterm yenidoğanlarda farklıydı.

**Gereç ve Yöntem:** Gebelik yaşı  $\leq 34$  hafta olan erken doğmuş bebekler dahil edildi ve eritrosit (RBC) transfüzyonundan önce ve sonra kan örnekleri alındı.

**Bulgular:** 17'si ROP olan 30 yenidoğan dahil edildi (evre 1: n=11, evre 2: n=5, evre 3: n=1). IGF-1 ve IGFBP-3 seviyeleri, RBC transfüzyonundan sonra değişmedi. Evre 3 ROP hastası hariç tutulduğunda, tüm ROP hastalarına hafif ROP adı verildi. Hafif ROP olan ve olmayan hastaların IGF-1 ve IGFBP-3 düzeyleri arasında fark gözlenmedi. Hafif ROP'lu hastalarda anlamlı olarak daha fazla transfüzyon mevcuttu.

**Sonuç:** Eritrosit transfüzyonu ROP sıklığını arttırırken, IGFBP-3 ve IGF-1 ROP ile ilişkili değildi.

**Anahtar Sözcükler:** Prematüre retinopati; IGF-1; IGFBP-3; VEGF; eritrosit transfüzyon.



**R**etinopathy of prematurity (ROP) is one of the leading causes of blindness in children. Despite controlled use of oxygen the disease still continues to be a problem in babies <1000 birth weight particularly <750 g in the developed world possibly due to the increased survival of extremely low birth weight infants (ELBW).<sup>[1-3]</sup> It is even more frequent in the developing world in relatively larger newborns with birth weight 1500 g or above. This finding is thought to be due to especially controlled neonatal intensive care conditions particularly oxygen and transfusions in developing countries resulting in increased survival together with also increased morbidity.<sup>[3,4]</sup>

Currently, prematurity, oxygen toxicity and many other factors are also believed to be effective in the development of ROP including initially low insulin like growth factor-1 (IGF-1) levels, high retinal vascular endothelial growth factor (VEGF) levels, blood transfusions, hyperglycemia, hypercarbia, clustered hypoxic events, sepsis and finally genetic factors.<sup>[4-7]</sup> However, there is no study to investigate the IGF-1 and IGFBP-3 association with erythrocyte transfusion.

Recent research suggests that there are 2 phases of ROP during which completely different management is required.<sup>[8-12]</sup> Phase 1 of ROP is the time right after birth when the preterm is born to an oxygen rich environment resulting in a sudden decrease in VEGF levels in retina. Since VEGF is a hypoxia induced mediator, hyperoxia results in suppressed VEGF production. This is also a time when a sudden drop in IGF-1 levels occurs which normally come readily from placenta and amniotic fluid when the fetus is in the uterus. VEGF is known as an angiogenetic mediator which also is important in retinal vascularization. IGF-1 which is actually a growth factor has been shown to act as a permissive factor in angiogenetic effects of VEGF. Therefore when VEGF and IGF-1 levels fall after preterm birth retinal vascularization arrests temporarily although retinal cell metabolism and growth continues which later on result in relative tissue hypoxia and subsequent retinal VEGF stimulation. Then starts the phase 2 of ROP during which both the increase in retinal VEGF and serum IGF-1 work together for retinal neovascularization causing ROP. Therefore during phase 1 the hypoxic suppression of VEGF needs to be avoided together with the decrease in IGF-1 levels whereas in phase 2 both VEGF and IGF-1 effects need to be neutralized.<sup>8-12</sup> However there are other factors which are also effective in the development of ROP during these 2 phases. Blood transfusions have long been held responsible for ROP although the mechanism has not been clear. The iron load, free radicals and even the IGF-1 levels in packed red blood cells (PRBC) have been proposed as possible explanations for the effect of PRBCs on development of ROP.<sup>[13-16]</sup> In one study the insulin like growth factor binding protein 3 (IGFBP-3) has been shown to avoid proliferative ROP.<sup>[17,18]</sup> IGFBP-3 is the major binding protein for IGF-1 in the postnatal period and extends half life of IGF-1 from 30 minutes to 12-15 hours in the body.<sup>[17,18]</sup>

## Objectives

To measure IGF-1 and IGFBP-3 levels in preterm newborns at risk for ROP before and after PRBC transfusion thereby to as-

sess if the effect of PRBCs in development of ROP is via these mediators.

## Materials and Method

This study was prospectively conducted to Gazi University Faculty of Medicine Neonatal Intensive Care Unit between January 2005 and June 2007. Ethical approval was obtained from the Ethics Committee of Gazi University Faculty of Medicine, Ankara Turkey. The study adheres to the Declaration of Helsinki. Informed written consents were obtained from the families of newborns planned to be included in the study. The erythrocyte transfusion of the babies was performed according to the liberal transfusion procedure of the IOWA study.<sup>[19]</sup>

Infants with 24<sup>th</sup>-34<sup>th</sup> of GA who underwent blood transfusions on the first 3 days of life and examined of ROP were included.

We excluded the newborns with gestational age >34 weeks, hemodynamic significant PDA and higher stage (stage 3 and 4) intracranial hemorrhage and not examined of ROP.

Blood samples of 1 ml were collected for IGF-1 and IGFBP-3 assays before and 30 minutes after PRBC transfusion. Serum samples were taken from at least 2 transfusions from all patients. The first sample was taken after the 3<sup>rd</sup> day of life. Serum was separated by 3500 rpm centrifugation for 5 minutes and kept at -80°C till the time of measurement. PRBC transfusions were given based on the following criteria as well as the attending neonatologist's judgement;

- Transfuse if on the ventilator or severe heart disease with Hb <15 g
- Transfuse if on nasal CPAP with increased oxygen requirement with Hb <10 g
- Transfuse if on room air with Hb <7 g with symptoms which could be attributed to anemia

Irradiated and filtered PRBCs were given as 15 ml/kg over 3 hours.

**IGF-1 Measurements:** IGF-1 levels were measured by using commercial ELISA kit (Biosource Human IGF-1 Cytelisa, Biosource, Rue de l'Industrie 8, B-1400 Nivelles sensitivity: 4.9 ng/ml) according to the manufacturer's instructions. First 50 µl serum was mixed with extraction solution and centrifugated at 12000 rpm for 2 minutes. 100 µl supernatant was taken and after neutralization 25 µl of solution was added to ELISA plate to be mixed with 100 µl antiIGF-1 antibody for 90 minutes. After washing with the automatic ELISA washer for 3 times chromogen substrate was added to the plate. After 30 minutes the reaction was stopped with stop solution and the plates were read spectrophotometrically at 405 nm wavelength. The optical density (OD) values were assessed with the Microsta statistical program and by using the OD of standard solutions with known IGF-1 levels the IGF-1 concentrations of the samples were calculated.

**IGFBP-3 Measurements:** IGFBP-3 levels were measured by using commercial ELISA kit (Biosource Human IGFBP-3 Cytelisa,

Biosource, Rue de l'Industrie 8, B-1400 Nivelles sensitivity: 10.5 ng/ml) according to the manufacturer's instructions. 100 µl of serum and 100 µl of antiIGFBP-3 antibody were added on the ELISA plate. After 90 minutes at room temperature the plate was washed 3 times with automatic ELISA washer and chromogen substrate was added. The reaction was stopped 30 minutes later with stop solution and the plates were read spectrophotometrically at 405 nm wavelength. The optical density (OD) values were assessed with the Microsta statistical program and by using the OD of standard solutions with known IGFBP-3 levels the IGFBP-3 concentrations of the samples were calculated.

**ROP Examinations:** Newborns less than 32 weeks gestation or 1500 g birth weight or preterm newborns larger than 32 weeks but at risk for developing ROP for having had oxygen requirements or ventilatory support were examined by the ophthalmologist according to the American Academy of Pediatrics policy statement by indirect ophthalmoscopy.<sup>[20]</sup> Before examination pupils were dilated with half strength 1.25% phenylephrine and 5% cycloplegic and sedation with midazolam was given to the baby to avoid discomfort. ROP classification was made by the international classification of ROP according to the following criteria:<sup>[21]</sup>

Stage 1: Demarcation line

Stage 2: Ridge formation

Stage 3: Fibrovascular proliferation from the ridge towards vitreous.

Stage 4: Partial retinal detachment

Stage 5: Total retinal detachment

Plus disease: Simply the increased tortuosity of the vessels.

Patients were continuously monitored by pulse oximetry during their intensive care stay and oxygen saturation measured by pulse oximetry was aimed to be kept between 88–92% to avoid oxygen toxicity.

## Statistics

SPSS for windows 11.5 version was used for statistical analysis. Wilcoxon signed rank test was used to assess the difference between mediator levels before and after transfusion. Mann Whitney U test was used to assess the difference between GA, oxygen treatment duration, mediator levels and number of transfusions in the newborns with and without ROP. Backward logistic regression analysis was performed to assess the

effects of the factors on ROP separately. The results are expressed as mean±SD unless stated otherwise and  $p < 0.05$  is accepted significant.

## Results

Thirty newborns were included in the study; 9 female (30%), 21 male (70%), GA:  $29.82 \pm 2.52$  weeks range (26–34), BW:  $1236 \pm 428.12$  g range (613–2400), PRBC transfusions were given  $4 \pm 3$  range (1–13) times, the duration of mechanical ventilation:  $6.5 \pm 7.8$  days range (0–28), duration of oxygen therapy:  $29.9 \pm 30.3$  days range (0–109). ROP was diagnosed in 17 of the 30 patients (56.7 %); 11 with stage 1 ROP (64.7 % of total ROP), 5 with stage 2 ROP (29.4 % of total ROP) and 1 with stage 3 ROP (5.9 % of total ROP) was identified. For the ease of discussion the patients with stage 1 and 2 ROP are referred as mild ROP and 1 patient with stage 3 ROP was excluded from statistical analysis. First blood sampling for IGF-1 and IGFBP-3 levels were obtained on day  $12.86 \pm 10.49$  of life (Postconceptional age: 32 w) on all patients. Second sampling was obtained from 16 patients on the  $18.5 \pm 10.48$  days of life (Postconceptional age: 33 w).

Demographic and clinical data of the patients with and without ROP are presented in Table 1 and Figure 1. The patients with ROP had significantly lower GA, longer duration of ventilation and oxygen treatment, more episodes of infection, and more number of PRBC transfusions compared to the non-ROP group.

No statistically significant difference was found between pre-transfusion and postransfusion IGF-1 and IGFBP-3 levels in either of the 2 transfusion episodes when all patients were analyzed together.

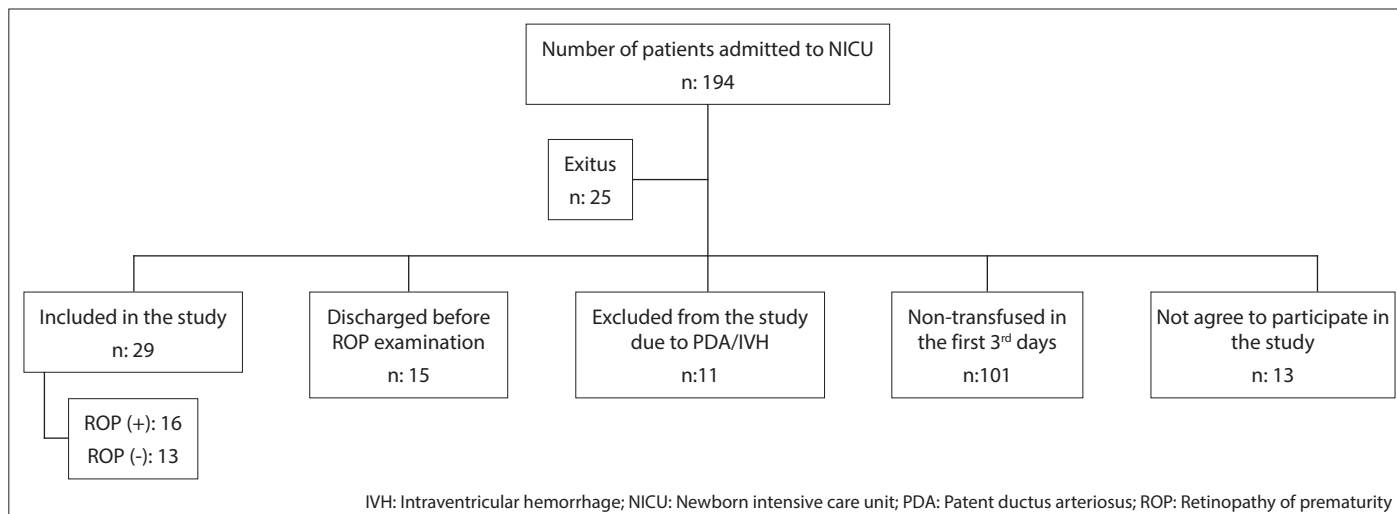
No statistically significant difference was found between the mediator levels of patients with and without ROP (Table 2), however statistics were made only for the 1<sup>st</sup> transfusion episode due to the limited number of samples during the 2<sup>nd</sup> transfusion from the patients without ROP. The mediator values of the ROP (+) patients were not statistically different before and after PRBC transfusions.

The results were also analyzed between stage 1 ROP and stage 2 ROP patients to be able to find whether stage 2 ROP patients had significantly different clinical or laboratory findings than the stage 1 ROP patients. Patients with stage 2 ROP had smaller GA, longer duration of ventilation and oxygen, more

**Table 1. Demographic and clinical data of patients with and without mild ROP**

ROP	Sex M/F	GA (w)	BW (g)	Number of transfusions	Sepsis	Days of ventilation	Days of oxygen
(-) n=13	9/4	$30.7 \pm 2.7$	$1452.33 \pm 504.61$	$3 \pm 2$	23%	$2.7 \pm 4.4$	$21.4 \pm 28.2$
(+) n=16	11/5	$29.1 \pm 2.2$	$1092.66 \pm 305.14$	$5 \pm 3$	58%	$9.4 \pm 8.6$	$39.6 \pm 28.9$
p		0.035	0.18	0.006	0.005	0.031	0.0001

ROP: Retinopathy of prematurity; GA: Gestational age; BW: Birth weight.



**Figure 1.** Distribution of infants less than 34 gestational weeks admitted to NICU between January 2005 and June 2007.

**Table 2. Serum IGF-1, IGFBP-3 levels pre and post PRBC transfusions in patients with and without mild ROP**

		ROP (+) n=16 Mean±SD	ROP (-) n=13 Mean±SD	p
1 <sup>st</sup> Transfusion n=29	Pre Transfusion IGF-1 (ng/ml)	33.59±45.27	31.61±101.5	0.29
Day of life 13	Post transfusion IGF-1 (ng/ml)	61.05±92.18	24.94±42.43	0.38
PCA:32w	Pre transfusion IGFBP-3 (ng/ml)	1271.46±707.34	914.94±263.9	0.26
	Post Transfusion IGFBP-3 (ng/ml)	1312.9±806	1314.09±302.76	0.85
2 <sup>nd</sup> transfusion n=16	Pre transfusion IGF-1 (ng/ml)	76.25±95.46	–	–
Day of life 18	Post Transfusion IGF-1 (ng/ml)	101.74±132.24	–	–
PCA: 33 w	Pre Transfusion IGFBP-3 (ng/ml)	1383.24±850.69	–	–
	Post Transfusion IGFBP-3 (ng/ml)	1027.24±565.87	–	–

IGF-1: Insulin growth factor 1; IGFBP-3: Insulin like growth factor binding protein 3; ROP: Retinopathy of prematurity; PRBC: Packed red blood cells; PCA: Post conceptional age.

number of transfusions, and more infections than the stage 1 ROP group. Despite lack of statistical significance, IGF-1 levels of patients with stage 2 ROP at postconceptional age 32 weeks tended to be lower (13.65 ng/ml vs 45.6 ng/ml) than the stage 1 ROP group with mean values below the 30 ng/ml which is considered to be critical during retinal vascularization.

Considering GA, number of transfusions, infections, duration of oxygen and ventilator treatment were all significantly different in patients with ROP, logistic regression analysis was done which showed that PRBC transfusions were the most effective parameter in our group and after the 3–4<sup>th</sup> transfusion each PRBC transfusion was associated with 1.61 times increased risk of ROP  $\beta=0.48$ ,  $p=0.033$ , OR:1.61 (1.03–2.51).

## Discussion

In this study, we showed that erythrocyte transfusion increases the possibility of ROP in premature infants. However, we have not found any statistically significant difference between pre and post transfusion levels of IGF-1 and IGFBP-3 in babies with and without ROP.

ROP continues to be a challenge for the neonatologists and

ophthalmologists taking care of preterm newborns despite technological advances in neonatal intensive care and ROP treatment. Although prematurity and oxygen toxicity are the 2 major reasons of ROP the mechanism is much more complicated. In their elegant research Hellstrom et al. have shown the 2 phases of ROP are completely diverse and require different approach. Phase 1 is a period of arrest of retinal vascularization due to decreased retinal VEGF and systemic IGF-1, whereas phase 2 is a period of neovascularization due to increased IGF-1 and retinal VEGF corresponding to postconceptional 34–35 weeks. If IGF-1 levels were below 30 ng/ml for a long time before this period the risk of proliferative ROP was higher.<sup>[8]</sup> Same group of authors have also shown that each 5 µg/l (5 ng/ml) increase in serum IGF-1 levels during 30–33 weeks postconceptional age decreased the risk of proliferative ROP by 45%.<sup>[22]</sup> Postnatal head growth deficit among preterm infants have also been found to go parallel to development of ROP and IGF-1 deficit.<sup>[23]</sup> Therefore there is little doubt that IGF-1 plays a major role in ROP together with VEGF. Although it is required for retinal vascularization VEGF can not stimulate retinal vascular development without IGF-1, for IGF-1 is necessary for the maximum stimulation of MAPK pathway by



VEGF which is important for cell proliferation.<sup>[8,11,24,25]</sup> However the timing of rise in IGF-1 levels is important as summarized above. On the other hand inflammation is a known inhibitor of IGF-1 which might explain the increased incidence of ROP in preterms with sepsis.<sup>[26]</sup>

IGFBP-3 the major binding protein of IGF-1 has recently been shown to suppress ROP by inhibition of oxygen induced vessel loss. Lofqvist et al. have measured IGFBP-3 levels in preterm newborns and have found low IGFBP-3 levels (802 ng/ml) at 30–35 weeks postconceptional age in infants with ROP compared to the ones without ROP (974 ng/ml).<sup>[17]</sup> Therefore IGFBP-3 together with IGF-1 seems to be important in the prevention of ROP.

The effect of blood transfusions on ROP has been studied even longer than the effect of mediators with the research revealing conflicting results. Hesse et al have found increased risk of ROP with blood transfusions but have not been able to relate this finding to increased iron load.<sup>[14]</sup> However Dani et al. have shown that PRBCs might contain significant amount of iron (0.48 mg/ml) which could increase free iron in the preterm newborn.<sup>[13]</sup> Free iron might catalyze fenton reactions producing free hydroxyl radicals and injure retinal cells. Hirano et al. have supported the same mechanism by showing increased free iron after blood transfusion.<sup>[5]</sup>

Perhaps the most interesting possible explanation for the effect of PRBC transfusions on ROP has come from Hubler et al. measuring IGF-1 levels in the transfused PRBCs. They have found that the IGF-1 in RBC transfusions corresponds to a single dose of 1 µg/kg IGF-1 treatment which the authors suggest might lead to increased VEGF induced retinal neovascularization if given at the critical period for proliferative ROP.<sup>[16]</sup>

In our study we have not found any statistically significant difference between pre and post transfusion levels of IGF-1 and IGFBP-3 in babies with and without ROP. Since proliferative ROP was observed in only 1 patient, the statistical analyses were done excluding that patient comparing patients without ROP and patients with mild ROP (stage 1, 2). As expected patients with mild ROP had lower GA, longer duration of oxygen and ventilation treatment, more episodes of infection and more number of PRBC transfusions compared to the non-ROP group. However we did not observe any difference of IGF-1, IGFBP-3 levels between the 2 groups at the time corresponding to 32 postconceptional age. This finding might be due to lack of proliferative ROP in the compared group since in other studies investigating the role of these mediators focus has mostly been on proliferative ROP. However IGF-1 levels tended to be lower (13.65 ng/ml <30 ng/ml) in our patients with stage 2 ROP at postconceptional 32 weeks although the difference did not reach significance, which could be due to the small number of patients.

PRBC transfusions were found to be a major factor for development of mild ROP in our study in addition to GA and oxygen. After the 3–4<sup>th</sup> PRBC transfusion each new transfusion increased the risk of mild ROP by 1.61 times. This finding might

suggest that together with well controlled oxygen therapy, well controlled transfusion strategies are also important in the prevention of mild ROP. Considering that although mostly regresses spontaneously mild ROP is still an important morbidity making the patient prone to other retinal problems in late childhood or adulthood, this effort is well worth to try.

The most important limitation of our study is the low numbers of ROP in the higher stage (stage 2 and over).

## Conclusion

Our results suggest that; PRBC transfusions play an important role in the development of mild ROP. Therefore, controlled erythrocyte transfusion in the neonatal period will help prevent ROP development. However, in order to investigate the role of RBC transfusion on IGF-1 and IGFBP-3, which needs studies further stage large series of ROP.

**Acknowledgment:** This study was supported by Gazi University Hospital, Department of Pediatrics, Division of Newborn Medicine,

**Conflict of interest:** There are no relevant conflicts of interest to disclose.

## References

1. Good WV, Hardy RJ, Dobson V, et al. Early treatment for retinopathy of prematurity cooperative group. The incidence and course of retinopathy of prematurity: Findings from the early treatment of retinopathy of prematurity study. *Pediatrics* 2005;116(1):15-23.
2. Mathew MR, Fern AI, Hill R. Retinopathy of prematurity: Are we screening too many babies? *Eye* 2002;16(5):538-542.
3. Bas AY, Demirel N, Koc E, Ulubas Isik D, Hirfanoglu IM, Tunc T; TR-ROP Study Group. Incidence, risk factors and severity of retinopathy of prematurity in Turkey (TR-ROP study): a prospective, multicentre study in 69 neonatal intensive care units. prospective, multicentre study in 69 neonatal intensive care units. *Br J Ophthalmol*. 2018 Mar 8.
4. Smolkin T, Steinberg M, Sujov P, et al. Late postnatal systemic steroids predispose to retinopathy of prematurity in very low birth weight infants: a comparative study. *Acta Paediatrica* 2008;97(3):322-326.
5. Bizzarro MJ, Hussein N, Jonsson B, et al. Genetic susceptibility in retinopathy of prematurity. *Pediatrics* 2006;118(5):1858-1863.
6. Coleman R, Beharry KD, Brock RS, et al. Effects of brief, clustered versus dispersed hypoxic episodes on systemic and ocular growth factors in a rat model of oxygen induced retinopathy. *Pediatr Res* 2008;64(1):50-55.
7. Zhang S, Zhou R, Li B, et al. Caffeine preferentially protects against oxygen-induced retinopathy. *FASEB J*. 2017 Aug;31(8):3334-3348.
8. Hellstrom A, Perruzzi C, Ju M, Engstrom E. Low IGF-1 suppresses VEGF-survival signaling in retinal endothelial cells: Direct correlation with clinical retinopathy of prematurity. *PNAS* 2001;98(10):5804-5808.
9. Chen J, Smith LE. Retinopathy of prematurity. *Angiogenesis* 2007;10(2):133-140.
10. Smith LE. Pathogenesis of retinopathy of prematurity Growth Hormone and IGF. *Growth Horm IGF Res* 2004;14:S140-S144.
11. Smith LE. Pathogenesis of retinopathy of prematurity. *Semin Peri-*

- natol 2003;8(6):469-473.
12. Yeung MY. Somatotrophic axis derangement as an underlying factor in the genesis of retinopathy of prematurity. *Acta Paediatrica* 2006;95(11):1334-1340.
  13. Dani C, Reali MF, Bertini G, et al. The role of blood transfusions and iron intake on retinopathy of prematurity. *Earl Hum Dev* 2001;62(1):57-63.
  14. Hesse L, Eberl W, Schlaud M, et al. Blood transfusion iron load and retinopathy of prematurity. *Eur J Pediatr* 1997;156(6):465-470.
  15. Azami M, Jaafari Z, Rahmati S, Farahani AD, Badfar G. Prevalence and risk factors of retinopathy of prematurity in Iran: a systematic review and meta-analysis. *BMC Ophthalmol*. 2018 Apr 2;18(1):83.
  16. Hübner A, Knotte K, Kauf E, et al. Does insulin-like growth factor 1 contribute in red blood cell transfusions to the pathogenesis of retinopathy of prematurity during retinal neovascularization? *Biol Neonate* 2006;89(2):92-98.
  17. Lofqvist C, Chen J, Connor KM, et al. IGFBP3 suppresses retinopathy through suppression of oxygen-induced vessel loss and promotion of vascular growth. *PNAS* 2007;104(25): 10589-10594.
  18. Rajah R, Valenitis B, Cohen P. Insulin-like growth factor binding protein-3 induces apoptosis and mediates the effects of transforming growth factor beta 1 on programmed cell death through a p53 and IGF independent mechanism. *J Biol Chem* 1997; 272(18):12181-12188.
  19. Kirpalani H, Whyte RK, Andersen C, Asztalos EV, Heddle N, Blajchman MA, et al. The premature infants in need of transfusion (PINT) study: a randomized controlled trial of restrictive (low) versus liberal (high) transfusion threshold for extremely low birth weight infants. *J Pediatr* 2006; 149: 301-307.
  20. American Academy of Pediatrics, American Academy of Ophthalmology, American Association for Pediatric Ophthalmology and Strabismus. Screening examination for premature infants for retinopathy of prematurity. Policy Statement. *Pediatrics* 2013 Jan;131(1):189-95.
  21. International committee for the classification of retinopathy of prematurity. The international classification of retinopathy of prematurity revisited. *Arch Ophthalmol* 2005;123(7):991-999.
  22. Hellstrom A, Engstrom E, Hard AL, et al. Postnatal insulin-like growth factor deficiency is associated with retinopathy of prematurity and other complications of premature birth. *Pediatrics* 2003;112(5):1016-1020.
  23. Lofqvist C, Engstrom E, Sigudsson J, et al. Postnatal head growth deficit among premature infants parallels retinopathy of prematurity and insulin-like growth factor deficit. *Pediatrics* 2006;117(6):1930-1938.
  24. Modanlou HD, Gharraee Z, Hasan J et al. Ontogeny of VEGF, IGF-1, and GH in neonatal rat serum vitreous fluid, and retina from birth to weaning. *Invest Ophthalmol Vis Sci* 2006;47(2):738-744
  25. Hellstrom A, Carlsson B, Niklasson A, et al. IGF-1 is critical for normal vascularization of the human retina. *J Clin Endocrinol Metab* 2002; 87(7):3413-3416.
  26. Hansen-Pupp IH, Hellstrom-Westas L, Cilio CM, et al. Inflammation at birth and the insulin-like growth factor system in very preterm infants. *Acta Paediatrica* 2007;96(6): 830-836.