

PAPER DETAILS

TITLE: Ultrasound-guided intermediate cervical plexus block for postoperative analgesia in patients undergoing carotid endarterectomy under general anesthesia: a case-control study

AUTHORS: Onat BERMEDE, Volkan BAYTAS

PAGES: 261-265

ORIGINAL PDF URL: <https://dergipark.org.tr/tr/download/article-file/2167268>



Ultrasound-Guided Intermediate Cervical Plexus Block for Postoperative Analgesia in Patients Undergoing Carotid Endarterectomy Under General Anesthesia: A Case-Control Study

Genel Anestezi Altında Karotis Endarterektomi Uygulanan Hastalarda Postoperatif Analjezi İçin Ultrason Eşliğinde İntermediate Servikal Pleksus Bloğu: Vaka Kontrol Çalışması

Onat Bermede¹, Volkan Baytaş¹

¹Ankara University Faculty of Medicine, Department of Anesthesiology and Reanimation, Ankara, Turkey

Abstract

Aim: The aim of this study is to compare intravenous analgesia (IVA) and intermediate cervical plexus block (ICPB) in terms of acute pain scores and opioid consumption in patients undergoing carotid endarterectomy (CEA) under general anesthesia.

Materials and Method: Following the induction of anesthesia, dexketoprofen trometamol 50 mg was administered before the surgical incision, and paracetamol 1 g was given at the end of the surgery and continued at 6 hour intervals for group IVA. Whereas, ultrasound-guided intermediate cervical plexus block was performed in ICPB group. VAS scores, morphine consumption, length of stay, and patient satisfaction status were compared.

Results: A total of 109 patients (57 in the IVA group and 52 in the ICPB group) between January 2015 and June 2021 were enrolled. The mean VAS score after extubation was significantly lower in the ICPB group (4.1 ± 1.4 vs 1.2 ± 0.8 , $p=0.005$). Total morphine consumption was found to be significantly lower in the ICPB group (13.1 ± 4.4 mg vs 3.9 ± 2.4 mg, $p<0.001$). The hospital stay was 3.1 ± 1.3 days in the IVA group, while it was 2.2 ± 0.9 days in the ICPB group ($p=0.0014$). The patients in the ICPB group were found to be significantly more satisfied (3.4 ± 1.4 vs 1.2 ± 0.8 , $p<0.001$).

Conclusion: Intermediate cervical plexus block provides lower acute pain scores and lower opioid consumption compared to intravenous analgesia in patients undergoing CEA under general anesthesia. In addition, this combined technique shortens the ICU and hospital length of stay and improves patient satisfaction.

Keywords: Carotid endarterectomy, intermediate cervical plexus block, analgesia

Öz

Amaç: Bu çalışmanın amacı, genel anestezi altında karotis endarterektomi (KEA) uygulanan hastalarda intravenöz analjezi (IVA) ve intermediate servikal pleksus bloğunu (ICPB) akut ağrı skorları ve opioid tüketimi açısından karşılaştırmaktır.

Gereç ve Yöntem: Anestezi indüksiyonunu takiben, Grup IVA'ya cerrahi kesi öncesi dexketoprofen trometamol 50 mg, operasyon bitiminde 1 gr parasetamol verildi ve 6 saat arayla devam edildi. ICPB grubuna ise ultrason eşliğinde ara servikal pleksus bloğu yapıldı. VAS skorları, morfin tüketimi, hastanede kalış süresi ve hasta memnuniyeti karşılaştırıldı.

Bulgular: Ocak 2015 ile Haziran 2021 arasında toplam 109 hasta (IVA grubunda 57 ve ICPB grubunda 52) dahil edildi. Ekstübasyon sonrası ortalama VAS skoru ICPB grubunda anlamlı olarak daha düşüktü ($4,1 \pm 1,4$ 'e karşı $1,2 \pm 0,8$, $p=0,005$). Toplam morfin tüketimi ICPB grubunda ($13,1 \pm 4,4$ mg vs $3,9 \pm 2,4$ mg, $p<0,001$) anlamlı olarak daha düşük bulundu. Hastanede kalış süresi IVA grubunda $3,1 \pm 1,3$ gün iken, ICPB grubunda $2,2 \pm 0,9$ gündü ($p=0,0014$). ICPB grubundaki hastaların anlamlı olarak daha fazla memnun oldukları bulundu ($3,4 \pm 1,4$ 'e karşı $1,2 \pm 0,8$, $p<0,001$).

Sonuç: İntermediate servikal pleksus bloğu, genel anestezi altında KEA uygulanan hastalarda, intravenöz analjeziye kıyasla daha düşük akut ağrı skorları ve daha düşük opioid tüketimi sağlar. Ayrıca bu kombine teknik, yoğun bakım ve hastanede kalış süresini kısaltır ve hasta memnuniyetini artırır.

Anahtar Kelimeler: Karotis endarterektomi, intermediate servikal pleksus bloğu, analjezi

Corresponding (İletişim): Onat BERMEDE, Assistant Professor, M.D., Ankara University School of Medicine Department of Anesthesiology and ICU, Ankara, Turkey

E-mail (E-posta): onatbermede@hotmail.com

Received (Geliş Tarihi): 30.12.2021 **Accepted (Kabul Tarihi):** 01.02.2022



INTRODUCTION

Carotid endarterectomy (CEA), which was first described by Eastcott et al. in 1954, continues to be performed frequently.

^[1] Although carotid artery stenting is an alternative, there are studies indicating that the rate of periprocedural stroke is higher.^[2] Therefore, it has not completely replaced endarterectomy. According to current guidelines, symptomatic internal carotid artery stenosis greater than 50% and asymptomatic internal carotid artery stenosis greater than 60% are stated as indications for CEA.^[3]

The anesthesia techniques used for CEA are still controversial. Although general anesthesia and cervical plexus blocks are the most commonly used methods, their superiority to each other has not been proven yet. While cervical plexus blocks provide effective neurological follow-up during surgery, general anesthesia provides airway safety and ventilation control.^[4] In addition, general anesthesia may be somewhat advantageous in terms of patient satisfaction.^[5] On the other hand, cervical plexus blocks may provide effective postoperative analgesia and stable hemodynamics.^[6] However, in almost all of these comparisons, analgesia was provided with oral and/or intravenous medications in the general anesthesia groups.

In this context, the aim of this study is to compare intravenous analgesia and intermediate cervical plexus block (ICPB) in terms of acute pain scores and opioid consumption in patients undergoing CEA under general anesthesia. The secondary objective is to compare length of stay and patient satisfaction.

MATERIAL AND METHOD

Ethics Committee was obtained from Ankara University, Faculty of Medicine, Clinical Research Ethics Committee (Date: 09.09.2021, Decision No: 2021/317). All procedures were carried out in accordance with the ethical rules and the principles of the Declaration of Helsinki.

The records of patients who underwent CEA under general anesthesia between January 2015 and June 2021 were evaluated. Patients who could not use patient-controlled analgesia and could not cooperate for pain assessment were excluded. In addition, patients whose all data could not be accessed due to deficiencies in the registration system were excluded from the study.

The patients were taken to the operating room without any premedication. In addition to routine anesthesia monitoring, bispectral index (BIS) and bilateral cerebral near infrared spectroscopy (NIRS) monitoring was performed. Anesthesia induction was provided with lidocaine 1 mg/kg, propofol 3 mg/kg, remifentanyl 1 µg/kg and rocuronium 0.6 mg/kg. After tracheal intubation, anesthesia was maintained with sevoflurane 1-2% and remifentanyl 0.1 - 0.2 µg/kg/min to keep the BIS between 50-60. Invasive radial artery monitoring was performed in all patients for close hemodynamic follow-up. Patients were placed in a supine position with the head facing the opposite side of the surgery.

In intravenous non-opioid analgesia (IVA) group, dexketoprofen trometamol (Metadem, IE Ulagay-Menarini, Turkey) 50 mg was administered before the surgical incision, except for patients with chronic renal failure. In addition, Paracetamol (Partemol, Vem Ilac, Ankara, Turkey) 1 g was given 30 minutes before the end of the surgery and continued at 6 hour intervals. Whereas, ultrasound-guided intermediate cervical plexus block was performed in ICPB group, according to the technique described by Choquet et al.^[7] The ultrasound probe was placed in the transverse plane at the level of the fourth cervical vertebra using GE Vivid T8 portable US machine (GE Healthcare, Fairfield, CT, USA) with a 3 to 8 MHz linear probe. Then, a 22 gauge 50 mm needle (Stimuplex A, B-Braun, Melsungen, Germany) was advanced in-plane with a posterior approach, from the posterior border of the sternocleidomastoid muscle to the posterior cervical space. After hydrodissection to test the appropriate injection site, 10 mL of 0.025% bupivacaine was injected under ultrasound control. 5 mL of the same local anesthetic solution was injected in the same plane while the needle was withdrawn (**Figure 1**). Finally, the last 5 mL was injected into the subcutaneous tissue at the posterior border of the sternocleidomastoid muscle.

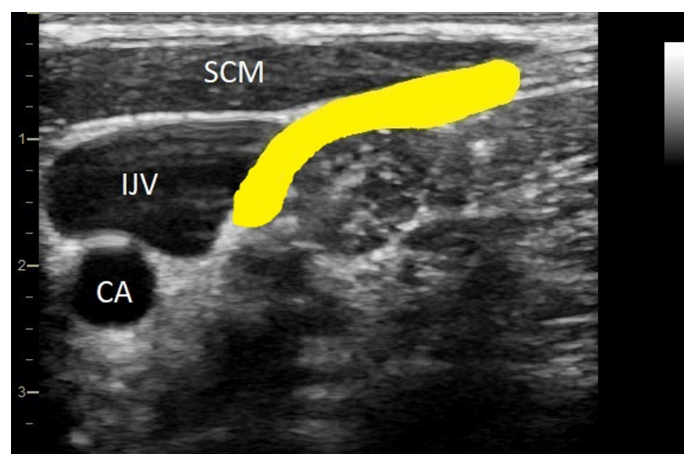


Figure 1. Transverse axis sonogram of the lateral side of the neck at the level of the fourth cervical vertebra. The yellow area shows the local anesthetic infiltrated area for ICPB. CA: carotid artery; IJV: internal jugular vein; SCM: sternocleidomastoid muscle.

After the surgery, the patients were extubated and transferred to the cardiovascular surgery intensive care unit (ICU) for close follow-up. Patient-controlled analgesia was set as a 1 mg bolus of intravenous morphine and a five-minute lock out time without a continuous rate. Visual Analogue Scale (VAS) from 0 to 10 (0=no pain and 10=the worst pain imaginable), which was explained to the patients before surgery, was used for self-assessment of postoperative pain. Morphine requirement and VAS scores were recorded every 15 minutes for the first four hours after surgery. Then, 30-minute follow-ups were taken. Patients with a VAS score below 4 and who were deemed appropriate by the surgical team to go to ward were transferred. Patient satisfaction status was measured on a 5-point scale before discharge (1, very satisfied; 2, satisfied; 3, average; 4, poor; 5, very poor).

Statistics

In the analyzes performed using IBM SPSS 20.0 software, the distribution of the data was evaluated with the Kolmogorov-Smirnov test. Normally distributed variables were compared using Student's t-test, while non-normally distributed variables were evaluated with Mann-Whitney U-test. Intergroup categorical data were compared using the Pearson chi-square test. Variables specified as mean \pm SD, if indicated. P values of less than 0.05 were regarded as statistically significant.

RESULTS

A total of 109 patients, 57 in the IVA group and 52 in the ICPB group, were enrolled. There was no difference between groups in terms of demographic data. Surgical sides were also similar between the groups ($p=0.17$). The duration of surgery was 136 ± 31 minutes in the IVA group, while it was 144 ± 34 minutes in the ICPB group ($p=0.31$) (Table 1).

Table 1. Demographic and surgical data

	IVA (n: 57)	ICPB (n: 52)	p value
Age, y, mean \pm SD	67.1 \pm 7.3	65.8 \pm 8.5	0.52
Sex (M/F), n	33/24	31/21	0.36
Body mass index, kg/m ² , mean \pm SD	23.6 \pm 3.2	24.1 \pm 2.9	0.47
ASA II / III, n (%)	24 (42.1)/33 (57.9)	18 (34.6)/34 (65.4)	0.41
Comorbidities, n (%)			
Hypertension	46 (80.7)	43 (82.6)	0.51
Diabetes mellitus	15 (26.3)	12 (23)	0.32
Coronary artery disease	18 (31.5)	16 (30.7)	0.44
COPD	7 (12.2)	6 (11.5)	0.39
Chronic renal failure	5 (8.7)	4 (7.6)	0.27
Side of surgery (L/R), n	30 / 27	28 / 24	0.37
Duration of surgery (min), mean \pm SD	136 \pm 31	144 \pm 34	0.31

IVA: intravenous analgesia; ICPB: intermediate cervical plexus block; COPD: chronic obstructive pulmonary disease.

The mean VAS score after extubation was significantly lower in the ICPB group (4.1 ± 1.4 vs 1.2 ± 0.8 , $p=0.005$). In addition, VAS scores at the first, second and sixth hours were significantly lower in the ICPB group than in the IVA group. On the other hand, there was no difference between VAS scores after 24 hours (1.4 ± 0.4 vs 0.7 ± 0.3 , $p=0.134$). Moreover, total morphine consumption was found to be significantly lower in the ICPB group (13.1 ± 4.4 mg vs 3.9 ± 2.4 mg, $p<0.001$) (Table 2).

While the length of stay in the ICU was 5.7 ± 1.9 hours in the IVA group, it was 2.4 ± 1.1 hours in the ICPB group ($p<0.001$). Similarly, the hospital stay was 3.1 ± 1.3 days in the IVA group, while it was 2.2 ± 0.9 days in the ICPB group ($p=0.0014$). Furthermore, considering the patient satisfaction score, the patients in the ICPB group were found to be significantly more satisfied (3.4 ± 1.4 vs 1.2 ± 0.8 , $p<0.001$) (Table 3).

Table 2. Visual analog scale (VAS) scores [0-10], total morphine consumption (mg)

	IVA (n: 57)	ICPB (n: 52)	p value
VAS scores, mean \pm SD			
After extubation	4.1 \pm 1.4	1.2 \pm 0.8	0.005
1 st hour	3.8 \pm 1.1	0.9 \pm 0.6	0.004
2 nd hour	3.7 \pm 1.6	1.0 \pm 0.6	0.004
6 th hour	3.1 \pm 2.1	1.1 \pm 0.5	0.006
24 th hour	1.4 \pm 0.4	0.7 \pm 0.3	0.134
Total morphine consumption (mg), mean \pm SD	13.1 \pm 4.4	3.9 \pm 2.4	<0.001

IVA: intravenous analgesia; ICPB: intermediate cervical plexus block; VAS: visual analog scale.

Table 3. Length of ICU and hospital stay, and patient satisfaction scores

	IVA (n: 57)	ICPB (n: 52)	p value
Length of ICU stay (hour), mean \pm SD	5.7 \pm 1.9	2.4 \pm 1.1	< 0.001
Length of hospital stay (day), mean \pm SD	3.1 \pm 1.3	2.2 \pm 0.9	0.014
Patient satisfaction score (1-5), mean \pm SD	3.4 \pm 1.4	1.2 \pm 0.8	< 0.001

IVA: intravenous analgesia; ICPB: intermediate cervical plexus block; ICU: intensive care unit.

DISCUSSION

ICPB resulted in lower acute pain scores and lower opioid consumption compared to intravenous analgesia in patients undergoing CEA under general anesthesia. In addition, ICPB provided shorter intensive care and hospital stays and higher patient satisfaction.

CEA continues to be practiced frequently, but there are uncertainties regarding the superiority of anesthesia techniques applied for this surgery.^[8] Although regional techniques come to the fore, general anesthesia is also frequently applied due to the preferences of both the physicians and the patients.^[9] After the GALA trial, which could not find a difference between local anesthesia and general anesthesia, many studies have been carried out on this subject.^[10] Cervical plexus blocks have become popular and applied by anesthesiologists frequently. Hasde et al. stated that there was no difference between regional anesthesia and general anesthesia in terms of mortality and cerebral complications in CEA. On the other hand, they emphasized that regional anesthesia is more advantageous in terms of hemodynamic stabilization, postoperative pulmonary complications and length of hospital stay.^[11] In addition, Kim JW et al. determined that since awake neurological monitoring can be performed under regional anesthesia, it reduces the rate of shunt usage, and also shortens operation time and the length of hospital stay.^[12] However, the general anesthesia methods used in all these studies are not standard and show differences. These differences may be important in terms of hemodynamics and postoperative outcomes. There are also deficiencies in techniques used for effective pain control, which have a serious impact on perioperative complications. Therefore, in order to demonstrate an enhanced general anesthesia technique, we aimed to reveal the difference of regional block used in combination for analgesia in patients who underwent standardized general anesthesia for CEA.

A wide range of nerve blocks are used for the treatment of acute pain in anesthesia practice. The effectiveness of nerve blockades applied in combination in patients undergoing general anesthesia has been demonstrated. It is recommended to be applied because it both contributes to a more balanced anesthesia and provides a serious reduction in acute pain scores.^[13] In recent years, especially USG guided deep, intermediate or superficial cervical plexus blocks has been widely used for CEA. Alilet et al. compared the efficacy of superficial and intermediate cervical plexus blocks for CEA, but could not find a significant difference between these two techniques.^[14] Whereas, Kavaklı et al. stated that ultrasound-guided combined deep and superficial cervical plexus block resulted in less additional analgesic use and lower pain scores compared to the ICPB.^[15] Samanta et al. applied this blockade, which is used for regional anesthesia, as a combination therapy in a patient who underwent CEA under general anesthesia and noted that they encountered a better hemodynamic response and improved postoperative outcome.^[16] Based on this, we used ICPB as a combination therapy in patients undergoing CEA under general anesthesia.

Acute pain is one of the most important factors affecting hemodynamics and patient comfort after CEA. Opioids are often used in the treatment to avoid any complications caused by pain. Even when ultrasound did not enter anesthesia practice that much, cervical block was used using the landmark technique to reduce opioid consumption. Messner et al. demonstrated that superficial cervical plexus block with the landmark technique decreased opioid consumption in patients who underwent CEA under general anesthesia in 2006.^[17] In fact, Cherprenet et al. stated that even local anesthetic wound infiltration before closure reduces opioid consumption and decreases pain scores.^[18] In a more recent study, Do et al. mentioned that ultrasound-guided cervical plexus block leads to both a more stable hemodynamic and lower pain scores compared to general anesthesia.^[19] As expected, in our study, patients who had ICPB in addition to general anesthesia presented with lower acute pain scores and reduced opioid consumption. Based on this, we think that it would be more appropriate to review the standardization of general anesthesia techniques for CEA in the literature and to make comparisons accordingly.

The effective use of health resources is very important in today's medicine, as it has become a current issue again during the pandemic period. Shortening the length of stay of patients in intensive care or hospital is one of the most important parts of this perspective. There are studies indicating that the anesthesia technique used for CEA is a feature that makes difference in terms of hospital stay. Lobo et al. stated shorter length of stay in patients who underwent locoregional anesthesia when compared with general anesthesia.^[20] In line with this data, Güner et al. mentioned that the duration of hospitalization is shorter in surgery completed under local anesthesia.^[21] However, it

is controversial how general anesthesia is standardized in these studies. In our study, we found that the addition of ICPB shortened the hospital stay in patients who underwent general anesthesia. Therefore, we think that it should be kept in mind that effective analgesia methods are effective on this period. In addition, it is known that the patient satisfaction is higher than regional anesthesia in patients who underwent CEA under general anesthesia.^[22] Our study, in which both groups were under general anesthesia, revealed that the addition of ICPB further increased patient satisfaction.

This study has some limitations. First, randomization could not be done because the study plan was retrospective. Second, the sociocultural and educational levels of the patients may have created a difference in the perception of pain, but no record was kept for this subject. Third, postoperative complications and the long term results of the applied techniques on the patients could not be examined. It can be described as a deficiency in order to reveal the effects of nerve blocks on chronic pain. Better planned and large-scale studies are needed to reveal the effectiveness and differences of anesthesia and analgesia methods applied in patients who have undergone carotid endarterectomy.

CONCLUSION

Intermediate cervical plexus block provides lower acute pain scores and lower opioid consumption compared to intravenous analgesia in patients undergoing CEA under general anesthesia. In addition, this combined technique shortens the ICU and hospital length of stay and improves patient satisfaction. Better standardized studies are needed to reveal the effect of anesthesia techniques on CEA outcomes..

ETHICAL DECLARATIONS

Ethics Committee Approval: Ethics Committee was obtained from Ankara University, Faculty of Medicine, Clinical Research Ethics Committee (Date: 09.09.2021, Decision No: 2021/317).

Informed Consent: Because the study was designed retrospectively, no written informed consent form was obtained from patients.

Referee Evaluation Process: Externally peer-reviewed.

Conflict of Interest Statement: The authors have no conflicts of interest to declare.

Financial Disclosure: The authors declared that this study has received no financial support.

Author Contributions: All of the authors declare that they have all participated in the design, execution, and analysis of the paper, and that they have approved the final version.

REFERENCES

1. Eastcott HH, Pickering GW, Rob CG. Reconstruction of internal carotid artery in a patient with intermittent attacks of hemiplegia. *Lancet* 1954;267(6846):994-6.
2. Sastry RA, Pertsch NJ, Sagaityte E, Poggi JA, Toms SA, Weil RJ. Early Outcomes After Carotid Endarterectomy and Carotid Artery Stenting: A Propensity-Matched Cohort Analysis. *Neurosurgery* 2021;nyab250. doi:10.1093/neuros/nyab250.
3. Brott TG, Halperin JL, Abbara S, et al. 2011 ASA/ACCF/AHA/AANN/AANS/ACR/ASNR/CNS/SAIP/SCAI/SIR/SNIS/SVM/SVS guideline on the management of patients with extracranial carotid and vertebral artery disease. *Stroke* 2011;42(8):e464-e540.
4. Kuru V, Aksun M, Karahan N, et al. Comparison of General Anesthesia and Regional Anesthesia on Carotis Endarterectomy Operation Patients in terms of Their Perioperative Complications. *GKD Anest Yoğ Bak Dern Derg* 2015;21(3):134-41.
5. Mracek J, Kletecka J, Holeckova I, et al. Patient Satisfaction with General versus Local Anesthesia during Carotid Endarterectomy. *J Neurol Surg A Cent Eur Neurosurg* 2019;80(5):341-4.
6. Gassner M, Bauman Z, Parish S, Koenig C, Martin J, Hans S. Hemodynamic changes in patients undergoing carotid endarterectomy under cervical block and general anesthesia. *Ann Vasc Surg* 2014;28(7):1680-5.
7. Choquet O, Dadure C, Capdevila X. Ultrasound-guided deep or intermediate cervical plexus block: the target should be the posterior cervical space. *Anesth Analg* 2010;111(6):1563-4.
8. Harky A, Chan JSK, Kot TKM, et al. General Anesthesia Versus Local Anesthesia in Carotid Endarterectomy: A Systematic Review and Meta-Analysis. *J Cardiothorac Vasc Anesth* 2020;34(1):219-34.
9. Mracek J, Kletecka J, Mork J, et al. Indications for General versus Local Anesthesia during Carotid Endarterectomy. *J Neurol Surg A Cent Eur Neurosurg* 2019;80(4):250-4.
10. GALA Trial Collaborative Group, Lewis SC, Warlow CP, et al. General anaesthesia versus local anaesthesia for carotid surgery (GALA): a multicentre, randomised controlled trial. *Lancet* 2008;372(9656):2132-42.
11. Hasde AI, Baran Ç, Özçınar E, Karakaya HÇ, et al. The effect of anesthesia technique in carotid endarterectomy: Regional versus general anesthesia. *Turk J Vasc Surg* 2021;30(1):42-8.
12. Kim JW, Huh U, Song S, Sung SM, Hong JM, Cho A. Outcomes of Carotid Endarterectomy according to the Anesthetic Method: General versus Regional Anesthesia. *Korean J Thorac Cardiovasc Surg* 2019;52(6):392-9.
13. Kumar K, Kirksey MA, Duong S, Wu CL. A Review of Opioid-Sparing Modalities in Perioperative Pain Management: Methods to Decrease Opioid Use Postoperatively. *Anesth Analg* 2017;125(5):1749-60.
14. Alileit A, Petit P, Devaux B, et al. Ultrasound-guided intermediate cervical block versus superficial cervical block for carotid artery endarterectomy: The randomized-controlled CERVECCHO trial. *Anaesth Crit Care Pain Med* 2017 Apr;36(2):91-95. doi:10.1016/j.accpm.2016.03.007.
15. Sait Kavaklı A, Kavrut Öztürk N, Umut Ayoğlu R, Sağdıç K, Çakmak G, İnanoğlu K, Emmiler M. Comparison of Combined (Deep and Superficial) and Intermediate Cervical Plexus Block by Use of Ultrasound Guidance for Carotid Endarterectomy. *J Cardiothorac Vasc Anesth* 2016;30(2):317-22.
16. Samanta S, Samanta S, Panda N, Halder R. A unique anesthesia approach for carotid endarterectomy: Combination of general and regional anesthesia. *Saudi J Anaesth* 2014;8(2):290-3.
17. Messner M, Albrecht S, Lang W, Sittl R, Dinkel M. The superficial cervical plexus block for postoperative pain therapy in carotid artery surgery. A prospective randomised controlled trial. *Eur J Vasc Endovasc Surg* 2007;33(1):50-4.
18. Cherprenet AL, Rambourdin-Perraud M, Laforêt S, et al. Local anaesthetic infiltration at the end of carotid endarterectomy improves post-operative analgesia. *Acta Anaesthesiol Scand* 2015;59(1):107-14.
19. Do W, Cho AR, Kim EJ, Kim HJ, Kim E, Lee HJ. Ultrasound-guided superficial cervical plexus block under dexmedetomidine sedation versus general anesthesia for carotid endarterectomy: a retrospective pilot study. *Yeungnam Univ J Med* 2018;35(1):45-53.
20. Lobo M, Mourão J, Afonso G. Carotid endarterectomy: review of 10 years of practice of general and locoregional anesthesia in a tertiary care hospital in Portugal. *Braz J Anesthesiol* 2015;65(4):249-54.
21. Güner O, Yapıcı F, Yapıcı N, Özler A, Işık Ö. Comparison between local and general anesthesia for carotid endarterectomy: early and late results. *Vasc Endovascular Surg* 2012;46(2):131-8.
22. Mracek J, Kletecka J, Holeckova I, et al. Patient Satisfaction with General versus Local Anesthesia during Carotid Endarterectomy. *J Neurol Surg A Cent Eur Neurosurg* 2019;80(5):341-4.