

PAPER DETAILS

TITLE: Orbital invazyon gösteren ve endonazal endoskopik olarak tedavi edilen dev etmoid osteom vakasi

AUTHORS: Eda SIMSEK,Zlkf KAYA,Mustafa Sitki GZELER,Cneyt KUCUR

PAGES: 0-0

ORIGINAL PDF URL: <https://dergipark.org.tr/tr/download/article-file/53794>

CASE REPORT / OLGU SUNUMU

A case of giant ethmoidal osteoma with orbital invasion treated via endonasal endoscopic approach

Orbital invazyon gösteren ve endonazal endoskopik olarak tedavi edilen dev etmoid osteom vakası

Eda Şimşek, Zülküf Kaya, M. Sıtkı Gözeler, Cüneyt Kucur

ABSTRACT

Osteomas are the most common benign bone tumors of paranasal sinuses. In general, they are small and asymptomatic. They may lead to local symptoms such as nasal obstruction, headache and facial pain when they become large, besides more severe signs and symptoms due to orbital and cranial expansion. The treatment in symptomatic and rapidly-growing cases is surgery. In treatment of paranasal sinus osteomas, endoscopic or open surgical techniques, which may be applied according to mass dimensions and localization, are available. Endoscopic endonasal resection is a safe method with successful results and low morbidity. It causes no cosmetic problems. In this study, a giant ethmoidal sinus osteoma invading orbital wall and extending to skull base was reported. It was totally resected by endonasal endoscopic approach.

Key words: Paranasal sinus, giant osteoma, endoscopic endonasal resection

ÖZET

Osteomlar, paranazal sinüslerin en sık görülen iyi huylu kemik tümörleridir. Genellikle küçük ve asemptomatik olup büyük boyutlara ulaştıklarında burun tıkanıklığı, baş ve yüz ağrısı gibi lokal semptomların yanında orbital ve kranial yayılıma bağlı daha ağır semptom ve bulgulara yol açabilmektedir. Semptomatik ve hızlı büyüyen vakaların tedavisi cerrahidir. Paranasal sinüs osteomlarının tedavisinde kitlenin boyutuna ve bulunduğu bölgeye göre uygulanabilen endoskopik ya da açık cerrahi teknikler mevcuttur. Endoskopik endonazal rezeksiyon, uygun vakalarda başarılı sonuçlar veren, morbiditesi düşük, kozmetik sorun oluşturmeyen, güvenli bir yöntemdir. Bu çalışmada, kafa tabanına dayanan, orbital invazyon gösteren ve endonazal endoskopik yaklaşımla total olarak başarılı bir şekilde rezekte edilen dev bir etmoid sinüs osteomu olgusu sunulmuştur.

Anahtar kelimeler: Paranasal sinüs, dev osteom, endonazal rezeksiyon

INTRODUCTION

Osteomas are the most common and slowly progressing benign bone tumors of paranasal sinuses. They most frequently occur in frontal sinus, maxillary sinus and ethmoid sinus. Sphenoid sinus localization is rare [1-4].

Osteomas generally remain asymptomatic and are incidentally found during radiologic investigations. Local symptoms may occur due to mass effect and if the tumor extrudes from nasal cavity, symptoms and signs of surrounding structures may occur. Mostly, unilateral headache, facial pain and deformity, sinusitis, ocular symptoms such as exophthal-

mos due to intraorbital invasion, dislocation of eyeball, ophthalmoplegia, loss of vision and diplopia, and severe clinical conditions such as meningitis due to intracranial invasion, cerebral abscess, and intracranial mucocoele [1-3]. The common opinion for small and asymptomatic cases is follow up of the tumor growth. In the treatment of symptomatic cases, endoscopic endonasal approach, open surgical techniques such as osteoplastic frontal sinusotomy, external fronto ethmoidectomy, lateral rhinotomy or combination of endoscopic and open approaches are commonly used techniques. Developments in endoscopic sinus surgery enabled endoscopic approach as a safe technique in the treat-

Erzurum Bölge Eğitim ve Araştırma Hastanesi KBB Kliniği, Erzurum, Türkiye

Yazışma Adresi /Correspondence: Eda Şimşek,

Erzurum Bölge Eğitim ve Araştırma Hastanesi KBB Kliniği, Erzurum, Türkiye Email:hekimeda@hotmail.com

Geliş Tarihi / Received: 10.06.2014, Kabul Tarihi / Accepted: 08.12.2014

Copyright © Dicle Tıp Dergisi 2014, Her hakkı saklıdır / All rights reserved

ment of paranasal sinus diseases under direct vision without cosmetic problems when compared to open surgical techniques. It has also low morbidity [4-6].

CASE REPORT

A 40 year old male patient admitted to our hospital Ear-Nose-Throat (ENT) outpatient clinic with complaints of headache, nasal obstruction, left facial pain, and pressure sensation in the left eye. In the last two years, the patient received several treatments at external centers for his nasal obstruction and headache symptoms with the diagnosis of sinusitis. Operation with open surgical technique had been recommended at an external center but the patient had refused the surgery. For the last 2 to 3 months, headache episodes increased, left facial pain and sense of pressure around his eye were added. There was no history of head or facial trauma. Head, neck and eye examination revealed no facial deformity, limitation in the eye movements, globe protrusion, loss of vision or diplopia.

Endoscopic nasal examination revealed natural appearance of mucosa, nasal septum deviation and stiff, bony mass pushing middle concha to medial side at the middle meatus. Other physical examinations showed no significant finding. Coronal plane paranasal sinus computerized tomography (CT) showed a 4x3 cm calcified mass consistent with osteoma which occupied left ethmoid cellulae and frontal recess, compressed and eroded the left lamina papyracea, invading orbital wall in the vicinity of middle skull base (Figure 1).

As the patient is symptomatic, operation was planned after obtaining informed consent. Under general anesthesia, mucosal decongestion was obtained and then local injections were made to points before the uncinate process starting from the attachment point of middle concha to lateral wall. Ossified mass was exposed in the middle meatus. The mass was dissected from surrounding tissues, lamina papyracea and skull base with the help of 0° and 30° endoscope. After deciding its full freedom, the mass was held by Takahashi forceps and totally removed. Lamina papyracea destruction was observed due to mass compression. After bleeding control, operation was completed without complications. Postoperative follow up showed no Cerebrospinal Fluid (CSF) rhinorrhea or orbital compli-

cations. Complaints of headache and eye pressure feeling reduced. Pathologic examination verified diagnosis of osteoma. Six months after the operation, patient had no clinical complaints and paranasal CT showed no residual or recurrence (Figure 2).

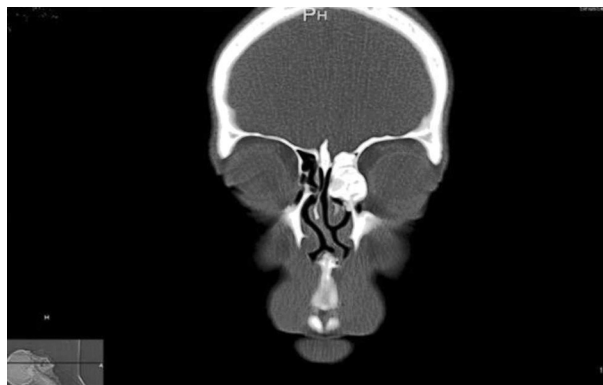


Figure 1. Coronal plane paranasal sinus computerized tomography (CT) showed a 4x3 cm calcified mass consistent with osteoma which occupied left ethmoid cellulae and frontal recess, compressed and eroded the left lamina papyracea, invading orbital wall in the vicinity of middle skull base.

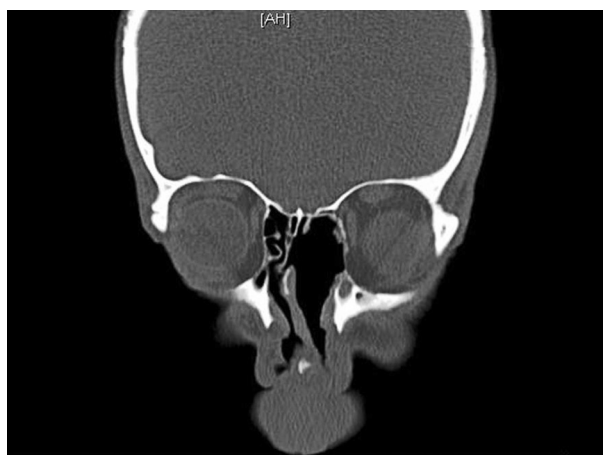


Figure 2. Six months after the operation, patient had no clinical complaints and paranasal CT showed no residual or recurrence.

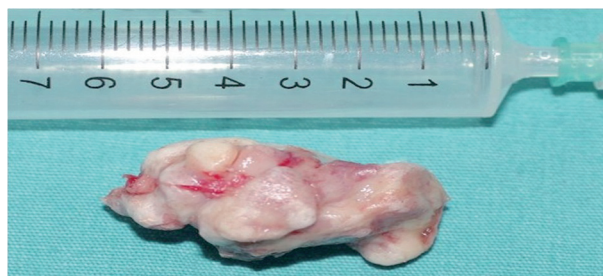

Figure 3. Totally excised mass of ethmoidal osteoma

DISCUSSION

Osteomas are slowly progressing benign tumors of bone and mostly affect skull, paranasal sinuses, mandible, temporal bone and mastoid bone. They occur most frequently in frontal sinus followed by maxillary sinus and ethmoid sinus. Sphenoid sinus localization is rare. It is more common in males and in the 2nd and 4th decades [2,4]. Microscopic structure may be stiff cortical, spongiotic or mixed. Differential diagnosis includes fibrous dysplasia which is rare, and bony lesions such as ossified fibroma [2,4,6-8].

Various theories have been suggested to explain the etiology of osteomas. Facial trauma, sinus infections and embryonic reasons were considered but none of these reasons were sufficient to explain the exact mechanism [4]. We failed to find any significant etiology in our patient.

Computerized tomography is the most convenient imaging method which can be used to diagnose osteomas and show the dimensions of mass and anatomic relations. It also is used during follow up period after treatment. Although conventional x-rays may identify osteomas, they are insufficient in showing the details for a safe surgical intervention. Magnetic resonance imaging is limited to show bone structures [1,4]. In our patient, CT was quite sufficient for pre-operative assessment and post-operative follow-up.

Paranasal sinus osteomas are generally small and asymptomatic. Masses bigger than 3 cm are accepted as giant tumors [1]. The most common symptom of sinus osteomas is localized headache resulting from mass effect and blockage of sinus drainage due to compression. Osteomas, go beyond their borders, lead to intracranial and orbital symptoms and signs. The most common ocular signs are exophthalmos, compression to extraocular muscles, optic disc edema, blurred vision and orbital infections. Intracranial spreading may lead to subdural abscess, meningitis, intracranial mucocele, pneumatocele [1,2,7]. The leading complaints in our patient were frontal headache and sensation of pressure around eye and face. There were no other associated ocular or systemic symptoms.

Although the debate has been continuing on treatment of osteomas, general opinion recommends close follow up for asymptomatic patients.

Surgery is recommended for sphenoid sinus osteomas even if they are asymptomatic, as they may cause optic nerve compression and blindness. Treatment of choice is surgery for symptomatic patients. Endoscopic or open surgical approaches such as osteoplastic frontal sinusotomy, fronto-ethmoidectomy and lateral rhinotomy are most commonly used techniques [1,6]. When planning the surgery, protection of optic nerve and skull base structures, full resection of the mass and minimal deformity should be taken into consideration. Endoscopic approach is preferred in diagnosis and treatment of paranasal sinus diseases, as it has advantages such as low morbidity, low risk of cosmetic deformity, early mobilization and lesser postoperative pain. Combination of both methods should be required in rare cases with difficult-to-reach anatomic regions [6].

In this case, we recommended surgery to the patient because he had severe symptoms. Endoscopic endonasal resection was the preferred method and we could excise the mass totally with a careful surgery (Figure 3). Patient was discharged immediately after the operation. No complication or cosmetic problem occurred during postoperative period. Complaints of the patient completely resolved.

In conclusion, paranasal sinus osteomas are usually small and asymptomatic. They rarely become giant sizes. In such case intracranial and intraorbital clinical conditions may be very important. Endoscopic endonasal surgery is safe and efficient method, which provides better cosmetic results with lower morbidity in treatment of symptomatic paranasal sinus osteomas.

REFERENCES

1. Müderris T, Bercin S, Sevil E, et al. Endoscopic Removal of a Giant Ethmoid Osteoma with Orbital Extension. *Acta Inform Med* 2012; 20: 266-268.
2. Özcan C, Görür K, Ünal M. Endonasal Endoscopic Fronto-ethmoid Osteom Resection. *K.B.B. ve Baş Boyun Cerrahisi Dergisi* 2000; 8: 216-218.
3. Menezes Co, Davidson Tm. Endoscopic resection of a sphenothmoid osteoma: a case report. *Ear Nose Throat J* 1994; 73: 598-600.
4. Koivunen P, Löppönen H. The growth rate of osteomas of the paranasal sinuses. *Clin Otolaryngol* 1997;22:111-114.
5. Bertolotti F, C. B. Bertolini, et al. Giant osteoid osteoma of ethmoid sinus: role of functional endoscopic sinus surgery. *Acta Otorhinolaryngologica Italica* 2004;24:297-301.
6. Acar A, Ünsal E, Dursun G. Paranasal sinus osteomas. *K.B.B. ve BBC Dergisi* 2001;11:110-113.
7. Earwaker J. Paranasal sinus osteomas: a review of 46 cases. *Skeletal Radiol* 1993;22:417-423.
8. Karakaş E, Kılıçaslan N, Karakaş Ö, et al. Osteoma located in the external ear canal. *J Clin Exp Invest* 2013;4:221-222.