

PAPER DETAILS

TITLE: Brucella melitensis'in neden olduđu tiroid bezi apsesi

AUTHORS: Hasan KARSEN,Hayrettin AKDENİZ,Remzi ERTEN,Mahmut SÜNNETÇIOĞLU,Ayhan YILDIZ,Mehmet BAYRAKTAR

PAGES: 225-227

ORIGINAL PDF URL: <https://dergipark.org.tr/tr/download/article-file/54206>

Thyroid gland abscess due to *Brucella melitensis* *Brucella melitensis*'in neden olduğu tiroid bezi apsesi

Hasan Karsen¹, Hayrettin Akdeniz², Remzi Erten³, Mahmut Sünnetçioğlu², Ayhan Yıldız⁴,
Mehmet Bayraktar⁵

¹Harran University Medical Faculty, Department of Infectious Diseases, Şanlıurfa, Turkey

²Yüzüncü Yıl University Medical Faculty, Department of Infectious Diseases, Van, Turkey

³Yüzüncü Yıl University Medical Faculty, Department of Pathology, Van, Turkey

⁴Yüzüncü Yıl University Medical Faculty, Department of Pathology, Van, Turkey

⁵Harran University Medical Faculty, Department of Medical Microbiology, Şanlıurfa, Turkey

Geliş Tarihi / Received: 18.06.2010, Kabul Tarihi / Accepted: 02.11.2010

ABSTRACT

Brucella infects many organs with various complications but thyroid gland infection is rare. We present a thyroid gland abscess due to brucellosis. The 53 years male patient was admitted to outpatient clinic with complaints of swelling and pain in the anterior part of the neck. The patient's thyroid hormones and anti-thyroid antibodies were in normal limits. The cause of thyroid gland abscess was *Brucella melitensis*. The diagnosis was made based on clinical, radiological, serological and bacterial culture results. The abscess was surgically evacuated and medical treatment was applied. The patient recovered without any sequel.

Key words: Brucellosis, thyroid, abscess

ÖZET

Brucella, birçok organı tutabilir ve çeşitli komplikasyonlarla seyredebilir. Ancak bruselloza bağlı tiroid bezi enfeksiyonu nadirdir. Bu yazıda brusellaya bağlı tiroid bezi apsesi gelişen bir olgu sunduk. 53 yaşında erkek hasta boyun ön tarafında şişlik ve ağrı ile polikliniğimize başvurdu. Hastanın tiroid hormonları ve anti-tiroid antikorları normal seviyede idi. Hastalığın tanısı, klinik, radyolojik, serolojik ve kültürle konuldu. Cerrahi ve medikal tedaviyle hasta sekelsiz iyileşti.

Anahtar kelimeler: Bruselloz, tiroid, apse

INTRODUCTION

Brucellosis is a zoonotic disease which constitutes a major health problem in many parts of the world, including Turkey¹. It is a multisystem disease with a broad spectrum of clinical manifestations, ranging from acute septicemic disease to various tissue and organ involvements in humans, whereas in animals, it is a localized disease presenting with abortus or sterility². The course of the disease may be subclinical, acute, subacute or chronic. Clinically, fever, chill, excessive sweating, headache, fatigue, malaise, weight loss, thoracic or lumbar back pain and generalized body pains are the most frequent symptoms.^{1,2} Many methods were used for proper diagnosis³. Thyroid gland involvement due to brucellosis is a rare complication. In this paper, we

present a rare case of thyroid gland abscess due to brucellosis.

CASE

A 53-year-old male patient admitted to our outpatient clinic with complaints of joint pain, fever, sweating and loss of appetite. His medical history revealed that his complaints had began two months ago with night fevers, chills and excessive sweating, accompanied at first by swelling and pain in his right knee and one week later in his left knee joints. Migratory pain was present in his hips, shoulders, and both lumbar and neck vertebral joints. Two weeks after the onset of the symptoms, painful swelling in the right side of his neck and throat pain developed and increased gradually in size. Following the next

days, he suffered from dysphagia and he began to walk only with support, therefore he was referred to our hospital. He was dealing with stockbreeding and he told that this year there had been abortion cases in their own sheep flock. His two sons and his bride living in the same village had also experienced brucellosis and treated. His family was used to making homemade cheese, but without boiling the milk and consuming the cheese freshly. On physical examination, his temperature was 37.5°C, pulse 80/min, breathe rate 16/min, blood pressure 140/70 mmHg. In his right thyroid lodge, a firm, slightly painful motionless mass was detected, with diameter of 4x4 cm and regular margins (Figure 1). In his complete blood count; leukocyte count was 11.900/mm³ (with the differential of 77% neutrophils, 17% lymphocytes and 6% monocytes), red blood cell count 4.490.000/mm³, hemoglobin 12.4 g/dl, haematocrit 37.1%, platelets 333.000/mm³, erythrocyte sedimentation rate 105 mm/h, C-reactive protein 182 mg/l. His blood biochemical tests were normal; Gruber- Widal test was negative. However, serum Rose Bengal Brucella test was positive. Serum brucella tube agglutination test was positive at 1/1280 titer. Blood culture yielded *Brucella melitensis*. His thyroid hormones were as follows: TSH 1.37, free T3 4.8, free T4 1.06 and he was euthyroid. Antithyroid peroxidase was 26.9 and antithyroid antibody <20. All these values were within normal ranges. In ultrasonographic examination, a heterogenous hypoechoic solid mass which includes cystic areas, with the diameter of 56x45 mm, fulfilling almost the whole right thyroid lobe was observed. The material in the thyroid right lobe was aseptically drawn and it was macroscopically purulent. In cytologic examination, abundant neutrophils, rare lymphocytes, as well as colloid and degenerated cells were seen. According to these findings, the condition was evaluated as acute inflammation. The abscess material was diluted with physiologic saline and then brucella tube agglutination which was performed from this diluted material revealed positivity at 1/1280 titer. Magnetic resonance imaging of the thyroid gland also showed the abscess in the right lobe.

The patient was treated with rifampin and doxycycline. The abscess was entirely evacuated. The clinical course of the patient recovered within two weeks and one month later the swelling in the neck of the patient entirely disappeared and other clinical and laboratory findings became normal. The

patient was discharged with full recovery after one month with the advice of continuing the treatment for further 2 weeks. Control follow-ups showed that the patient was completely recovered and his general health condition was well.

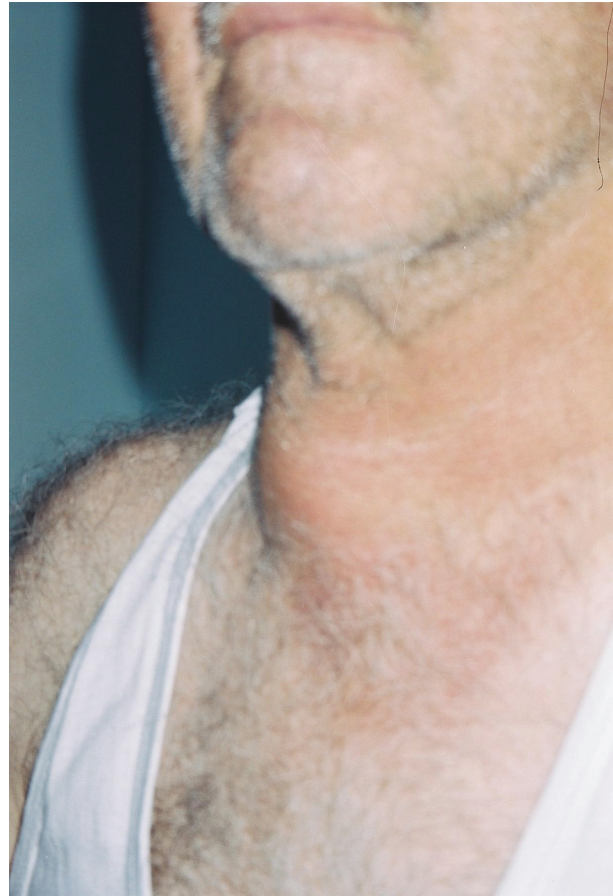


Figure 1. Swelling on the anterior part of the neck in thyroid gland location

DISCUSSION

Thyroid gland involvement due to brucellosis was firstly reported in a patient from Kuwait in 1989⁴. Up to now, the number of case reports in English literature has not exceeded digits of two hands. In thyroid gland involvement, an appearance of mass in neck region was seen^{5,6}, so was in our case too. Throat pain has been reported in some case reports⁶, as in our case. Neck pain was present due to the large mass, it is mentioned in some case reports, while not reported in some others^{5,7}. Graevenitz et al.⁵ did not observe dysphagia in their case, but we observed. Gürcan et al.⁸ made the diagnosis histologically in one of their cases. In one case report, histologically

nongranulomatous inflammation and lymphocytic infiltration in thyroid gland were reported.⁶ In cases with hyperthyroidism and thyroid tumors brucellosis could be coexisted.^{5,9} In our case, there was abundant neutrophilic infiltration and acute inflammation. These findings are differential characteristics of our case from subacute thyroiditis. Although culture positivity is the gold standard in diagnosis of brucellosis, but this is not possible all the time due to some reasons such as antibiotic therapy. Failure of yielding *Brucella* from purulent discharge may be due to antibiotic therapy. So the diagnosis is usually made serologically³. In our case, *B.melitensis* was grown from blood culture only, not from the abscess material. As tube agglutination test performed from abscess material was strongly positive. We think that thyroid abscess developed secondary to systemic brucellosis. The diagnosis was made in our case clinically, histologically, radiologically and with laboratory methods.

In conclusion, Brucellosis should be born in mind in differential diagnosis of thyroid gland diseases especially those associated with abscess.

REFERENCES

1. Young EJ. Serologic diagnosis of human brucellosis: Analysis of 214 cases by agglutination tests and review of the literature. *Rev Infect Dis* 1991; 13(4): 359-72.
2. Hall WH. Brucellosis. In: Evans AS, Brachman PS. editors. *Bacterial infections of humans*. Second edition. New York and London: Plenum Publishing corporation, 1991. p. 133-51.
3. Sisirak M, Hukić M, Knezević Z. Evaluation of some diagnostic methods for the brucellosis in humans - a five year study. *Prilozi* 2010; 31(1):91-101.
4. Mousa AR, al-Mudallal DS, Marafie A. *Brucella* thyroiditis. *J Infect* 1989; 19(2): 287-88.
5. Von Graevenitz A, Colla F. Thyroiditis due to *brucella melitensis*-report of two cases. *Infection* 1990; 18(2): 179-80.
6. Sirmatel F, Akarsu E. Case report. A brucellosis case with subacute thyroiditis. *Mikrobiyol Bult* 2002; 38(2): 149-53.
7. Azizi F, Katchoui A. *Brucella* infection of the thyroid gland. *Thyroid* 1996; 6(4): 461-63.
8. Gürcan Ş, Mistik R, Yılmaz E, et al. Thyroid gland involvement in brucellosis: Report of two cases. *Turk J Infect* 2001; 15(3): 369-71.
9. Van linthoudt D, Roth D, Ott H. Fibromyalgia associated with thyroid adenoma and brucellosis. *Presse Med* 1990;19(12):1587-9.