

PAPER DETAILS

TITLE: Geçici efüzyonlu konstriktif perikardit

AUTHORS: Erkan AYHAN,Turgay ISIK,Hüseyin UYAREL,Mehmet ERGELEN

PAGES: 571-574

ORIGINAL PDF URL: <https://dergipark.org.tr/tr/download/article-file/54260>

Transient effusive constrictive pericarditis

Geçici efüzyonlu konstriktif perikardit

Erkan Ayhan¹, Turgay Işık¹, Hüseyin Uyarel², Mehmet Ergelen²

ABSTRACT

Constrictive pericarditis is a rare complication which occurs after coronary bypass grafting operation. Classic constrictive pericarditis after cardiac operation coronary bypass grafting operation is considered to be progressive and irreversible, for which definitive therapy is a pericardiectomy. Herein, we reported a transient form of constrictive pericarditis that resolves without surgical intervention.

Key words: Complication, coronary bypass graft operation, transient constrictive pericarditis

ÖZET

Koroner bypass greft cerrahisi sonrası konstriktif perikardit gelişmesi nadir bir komplikasyondur. Kardiyak cerrahi koroner bypass greft cerrahisi sonrası gelişen klasik konstriktif perikardit ilerleyici ve geri dönüşümsüz seyirlidir ve kesin tedavisi perikardiyektomidir. Bu yazıda cerrahi müdahale olmaksızın düzelen konstriktif perikarditin geçici formunu sunmaktayız.

Anahtar kelimeler: Komplikasyon, koroner by-pass greft operasyonu, geçici konstriktif perikardit

INTRODUCTION

Constrictive pericarditis has been defined classically as a progressive condition, characterized by pericardial fibrosis, with or without calcification, which results in chronic refractory congestive heart failure.¹ and for which pericardiectomy is often required.¹ Constrictive pericarditis is a rare complication after coronary bypass grafting operation.¹ In most cases pericardiectomy is required as a definitive treatment. We report a 71-year-male patient who developed transient constrictive pericarditis with moderate mitral stenosis as a result of post cardiac injury syndrome. The patient went through coronary bypass graft operation that was successfully treated with postoperative medical therapy.

CASE REPORT

A 71-year old male patient was admitted to the emergency service with breathlessness, and paroxysmal nocturnal dyspnea. He had history of aorta-coronary bypass graft operation after unstable angina pectoris one-month ago. On physical examination, he was

dyspneic, blood pressure was 135/80mmHg, pulse rate was 110 beats/min and regular, respiratory rate was 28/min. The jugular veins were distended, the heart sounds were normal, no friction rub was noticed over the heart. He presented hepatomegaly and hepatojugular reflux. Electrocardiography demonstrated sinus tachycardia and nonspecific ST/T changes. Transthoracic echocardiography (TTE) revealed loculated large pericardial effusion (Figure 1A) adjacent to the lateral left ventricle and moderate mitral valve stenosis secondary to compression of the mitral valve annulus (Figure 1B). Computed tomography (CT) revealed pericardial effusion with thickened pericardium (6 mm) surrounding the left ventricle (Figure 1C, arrow). Aspirin (650 mg three times a day) and colchicines (1 mg for the first 2 days, and 0.5 mg per day afterwards) were given for three months. TTE and CT images, shown after a three month course of medical treatment, revealed minimal pericardial effusion (Figure 2A) with normal mitral valve gradient (Figure 2B) and normal pericardium (0.5 mm, Figure 2C).

¹ Balıkesir University, School Of Medicine, Department of Cardiology, Balıkesir, Turkey

² Bezmialem Vakıf University, School Of Medicine, Department of Cardiology, İstanbul, Turkey

Yazışma Adresi /Correspondence: Dr. Erkan Ayhan,

Pasaalanı Mah.233.Sokak, Suheda Apt No:3 Kat:1 Daire:4, Balıkesir,10100,Turkey Email: erkayh@gmail.com

Geliş Tarihi / Received: 25.07.2012, Kabul Tarihi / Accepted: 11.09.2012

Copyright © Dicle Tıp Dergisi 2012, Her hakkı saklıdır / All rights reserved

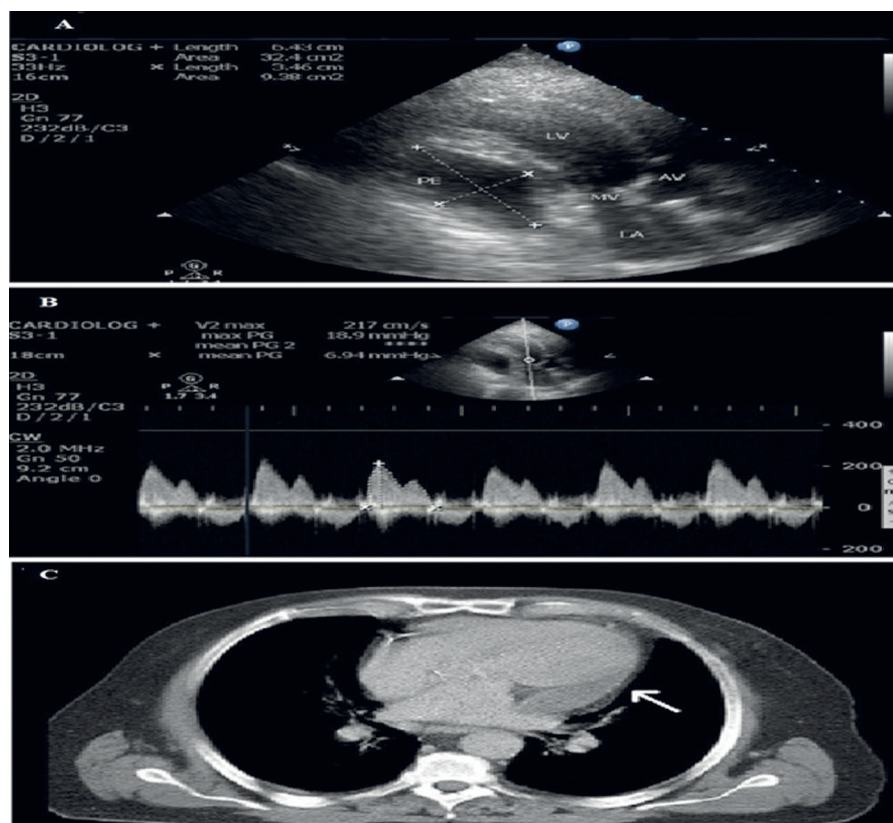


Figure 1. Transthoracic echocardiography (TTE) shows large pericardial effusion (A), moderate mitral valve stenosis (B), and thickened pericardium surrounding the left ventricle (C, arrow) before medical treatment.

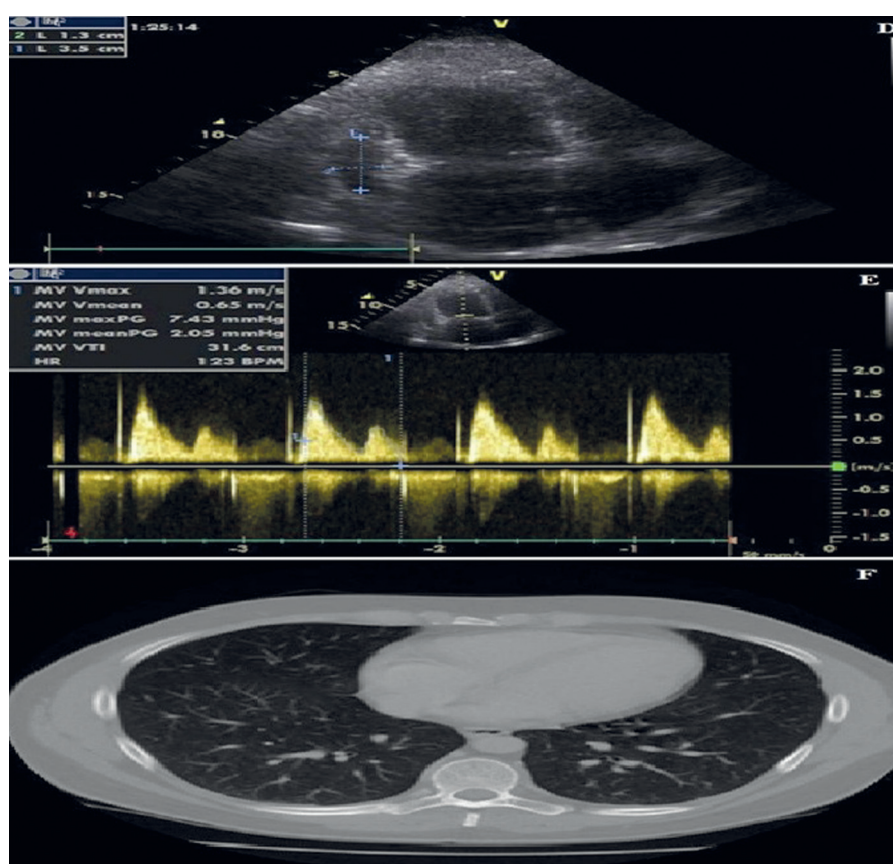


Figure 2. Minimal pericardial effusion (A), normal mitral valve gradient (B) and normal pericardium (C) after medical treatment. PE: Pericardial Effusion, LV: Left Ventricle, MV: Mitral Valve, AV: Aortic Valve, LA: Left Atrium

DISCUSSION

Pericardial inflammation of any etiology can spark a process of thickening, fibrosis, and occasionally, calcification, which can lead to manifestations of pericardial constriction.^{1,2} In a review of the cardiac constriction syndrome,¹ author suggested that there are several types of constrictive pericarditis. These include classic chronic constrictive pericarditis, subacute constriction including effusive-constrictive pericarditis, transient constrictive pericarditis, and occult constrictive pericarditis. All types of constrictive pericarditis were thought to be irreversible in the past. This led to a belief that all patients with constrictive pericarditis should undergo pericardiectomy. However, at present, it is well established that selected patients can be treated without pericardiectomy, leading to the concept of transient constrictive pericarditis.³⁻⁵ Clinical improvement can be spontaneous or accomplished with empirical medical therapy administered for several months. Constrictive pericarditis is an important cause of right and/or left ventricular failure caused by a reduction in the elasticity of the pericardium resulting in impaired diastolic filling of the heart.¹⁻³ Constrictive pericarditis diagnosis is possible to be obtained with the echocardiography, computed tomography, cardiac MRI and cardiac catheterization findings.^{6,7}

Constrictive pericarditis following coronary bypass graft operation is an unusual complication with occurrence rate of 0.2-0.3%.⁸ Time interval between operation and development of symptoms varies from 1 to 204 months, and clinical course varies as well. The pathogenesis of constrictive pericarditis after cardiac operation remains unknown.⁸

Transient constrictive pericarditis was first reported in 1987.⁴ The investigators described the three phases of this clinical entity. During the initial phase, a moderate to large amount of circumferential pericardial effusion was noted, and pericardiocentesis was necessary in some patients. In phase II, anti-inflammatory treatment yielded clinical improvement and diminished pericardial effusion; however, at a mean interval of 11 days (range, 5-30 days) after the detection of pericardial effusion, clinical signs and/or laboratory findings typical of constriction occurred. During the phase of constriction, the coexistence of a small amount of pericardial fluid was possible. In phase III (normalization), these constrictive changes returned to normal at a

mean of 2.7 months (range, 12 days to 10 months) after pericardial constriction was diagnosed, and all patients were reported free of constriction at a mean follow-up of 31 months. The mechanism of these findings would be a transiently thickened pericardium (as a consequence of edema, fibrin deposition or inflammation) that would return to normal.⁴ Haley JH et al. summarized the clinical picture and outcome of 36 patients with resolved pericardial constriction without surgical intervention.⁵ In this study, the most frequent causes of transient constrictive pericarditis were pericardiotomy-related (25%), idiopathic (22%), viral (19%), connective tissue disease-related (14%), and bacterial (11%). The results of these studies suggest that patients who have constrictive features, mainly if it appeared early in the course of their illness, and are hemodynamically stable should be considered for a trial of conservative therapy before pericardiectomy is pursued.⁵

Our patient showed phase II of transient constrictive pericarditis with pericardial fluid and moderate mitral stenosis. Because post-cardiac injury syndrome was seemed to be the cause of transient constrictive pericarditis and the patient was in phase II of the disease, we tried the anti-inflammatory drug therapy prior to the pericardiectomy. Medical therapy has been effective in reversing pericardial constriction only in some cases when it is given after operation.^{2,9,10} Therefore, we used aspirin and colchicines as a first line of anti-inflammatory treatment and successfully treated.

In conclusion, the reported patient presents a rare form of transient pericardial constriction who recovered completely following medical treatment without operation and any need for pericardiectomy.

REFERENCES

1. Sagrista-Sauleda J. Cardiac constriction syndromes. *Rev Esp Cardiol* 2008;61(2):33-40.
2. Clare GC, Troughton RW. Management of constrictive pericarditis in the 21st century. *Curr Treat Options Cardiovasc Med* 2007;9(6):436-42.
3. Akyuz S, Yaylak B, Ergelen M, Uyarel H. Transient constrictive pericarditis: an elusive diagnosis. *Future Cardiol* 2010;6(6):785-90.
4. Sagrista-Sauleda J, Permanyer-Miralda G, Candell-Riera J, Angel J, Soler-Soler J. Transient cardiac constriction: an unrecognized pattern of evolution in effusive acute idiopathic pericarditis. *Am J Cardiol* 1987;59(9):961-6.

5. Haley JH, Tajik AJ, Danielson GK, Schaff HV, Mulvagh SL, Oh JK. Transient constrictive pericarditis: causes and natural history. *J Am Coll Cardiol* 2004;43(2):271-5.
6. Mastouri R, Sawada SG, Mahenthiran J. Noninvasive imaging techniques of constrictive pericarditis. *Expert Rev Cardiovasc Ther* 2010;8(9):1335-47.
7. Almeida AR, Lopes LR, Cotrim C, et.al. Effusive-constrictive pericarditis: the role of noninvasive imaging. *Rev Port Cardiol* 2011;30(4):433-43.
8. Kutcher MA, King SB 3 RD, Alimurung BN, Craver JM, Logue RB. Constrictive pericarditis as a complication of cardiac surgery: recognition of an entity. *Am J Cardiol* 1982;50(4):742-8.
9. Imazio M, Trincherò R, Brucato A, et.al. COPPS Investigators. Colchicine for the Prevention of the Post-pericardiotomy Syndrome (COPPS): a multicentre, randomized, double-blind, placebo-controlled trial. *Eur Heart J* 2010;31(22): 2749-54.
10. Gianni F, Solbiati M; Gruppo di Autoformazione Metodologica (GrAM). Colchicine is safe and effective for secondary prevention of recurrent pericarditis. *Intern Emerg Med* 2012;7(2):181-2.