

PAPER DETAILS

TITLE: Mandibulada Dentinojenik Ghost Hücreli Tümör: Olgu sunumu

AUTHORS: Mehmet KELLES,Ahmet KIZILAY,Nasuhi Engin AYDIN

PAGES: 416-418

ORIGINAL PDF URL: <https://dergipark.org.tr/tr/download/article-file/54288>

Dentinogenic ghost cell tumour of mandible: Case report

Mandibulada Dentinojenik Ghost Hücreli Tümör: Olgu sunumu

Mehmet Kelleş¹, Ahmet Kızılay², Nasuhi Engin Aydın³

ABSTRACT

A 67 year old man with a gingival mass of six months duration was evaluated by aspiration cytology and excisional biopsy. Cytologic findings showed degenerated benign epithelial cells reminiscent of benign odontogenic keratocyst. However, the excisional biopsy was quite remarkable with odontogenic epithelium showing aberrant keratinization, i.e., ghost cells and dysplastic dentin that were features of dentinogenic ghost cell tumor. There was no sign of malignancy. After local resection of the mass, there was not any complication or recurrence six months later.

Key words: Odontogenic tumor, gingiva mass, dentinogenic ghost cell tumor

ÖZET

Altı aydır gingivada kitlesi olan 67 yaşındaki erkek hasta aspirasyon sitolojisi ve eksizyonel biyopsi ile değerlendirildi. Sitolojik bulgulara benign odontojenik keratositleri anımsatan dejenere benign epitelyal hücreler görüldü. Fakat eksizyonel biyopsi, dentinojenik ghost hücreli tümör özelliklerinden olan aberant keratinizasyon, ghost hücreleri ve displastik dentin görülen odontojenik epitel açısından oldukça belirgindi. Malignite belirtisi yoktu. Kitlenin lokal rezeksiyonundan sonraki 6 aylık dönemde herhangi bir komplikasyon veya rekürrens izlenmedi.

Anahtar kelimeler: Odontojenik tümör, gingiva kitlesi, dentinojenik ghost hücreli tümör

INTRODUCTION

Dentinogenic ghost cell tumor (DGCT) also known as odontogenic ghost cell tumor is a rare neoplastic counterpart of the calcifying odontogenic cyst.¹ Dentinogenic ghost cell tumor is a locally invasive neoplasm characterised by ameloblastoma-like islands of epithelial cells in a mature connective tissue stroma.² Dentinogenic ghost cell tumor can be seen in any age group from 10 to 90 years and there is no significant difference between genders.³ Dentinogenic ghost cell tumor occurring in the mandible and maxilla is called central or intraosseous, whereas in the alveolar mucosa and gingival soft tissues is called peripheral or extraosseous.³ The great majority of these tumors are benign and these are treated by local resection.¹

In this paper, a patient with dentinogenic ghost cell tumor in the mandibular gingiva is presented and the diagnosis and treatment is put forward.

CASE REPORT

A 67 year old man without any remarkable past medical history noticed a painless mass at his right lower anterior mandibular gingival region near the lateral incisive tooth. The mass had a continuous growth over a six month period. Upon physical examination a nodular mass of 2 cm with bulging smooth surface was seen on right anterior mandibular gingival sulcus. Radiograph showed a well-defined radiolucency in close approximation to the tooth-bearing area of right lower anterior mandibular region (Figure 1).

Fine needle aspiration of the mass yielded one milliliter of turbid brown fluid. Cytologic examination revealed groups of degenerating epithelial cells with prominent cytoplasm with foamy histiocytes (Figure 2). The cytology was interpreted as a degenerating epithelial cyst. Combining the radiographic image and the cytology the mass was

¹ Sütçü İmam Üniversitesi Tıp Fakültesi, KBB Anabilim Dalı, Kahramanmaraş, Türkiye

² İnönü Üniversitesi Tıp Fakültesi KBB Anabilim Dalı, Malatya, Türkiye

³ İnönü Üniversitesi Tıp Fakültesi, Patoloji Anabilim Dalı, Malatya, Türkiye

Yazışma Adresi /Correspondence: Dr. Mehmet Kelleş,

KSÜ University Medical faculty, Otolaryngology Department, Kahramanmaraş, Turkey Email: mkelles@hotmail.com

Geliş Tarihi / Received: 17.01.2012, Kabul Tarihi / Accepted: 27.08.2012

Copyright © Dicle Tıp Dergisi 2012, Her hakkı saklıdır / All rights reserved

thought to be a possible odontogenic cyst with possible proliferative activity. Excisional biopsy was planned. Total excision of the mass was done under local anesthesia. The mass did not have an intraosseous component. There was no complication.

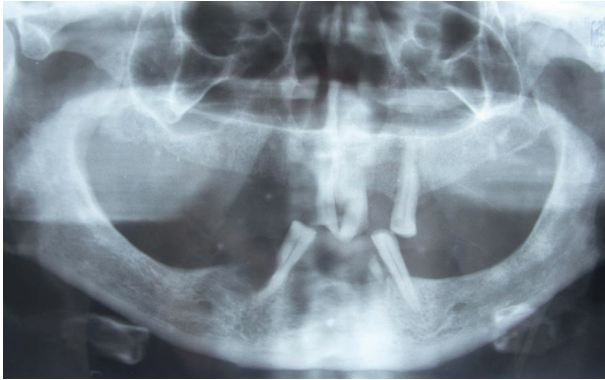


Figure 1. Radiolucent lesion and cortical defect in the anterior parasagittal aspect of mandible near right lateral incisor tooth (Panoramic mandible radiograph)

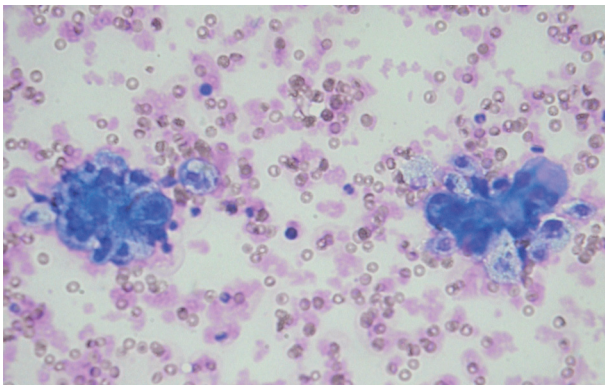


Figure 2. Cytologic examination revealing groups of degenerating epithelial cells with prominent cytoplasm with foamy histiocytes (H.E.x200)

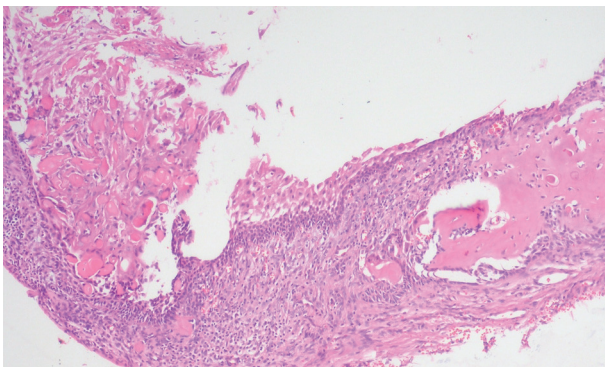


Figure 3. Histopathologic examination of the excised mass yielded cyst inner wall formed by stellate reticulum type, i.e., odontogenic, epithelium besides hyaline masses of dentin like tissue in a mature connective tissue background (H.E.x200)

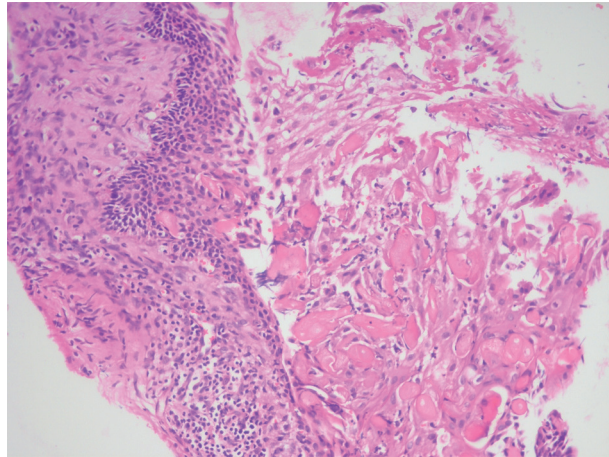


Figure 4. There was prominent eosinophilic transformation of anucleated epithelial cells, i.e. ghost cells (H.E.x200)

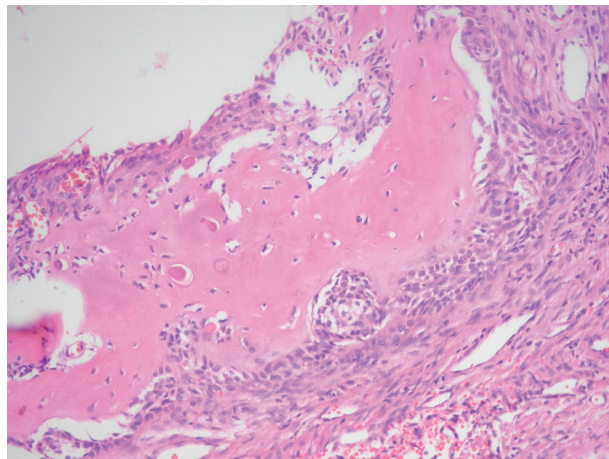


Figure 5. There was not any mitotic activity or invasive epithelial cell groups. In close approximation to these odontogenic epithelium eosinophilic hyaline masses of dysplastic dentine (dentinoid) without calcification was prominent (H.E.x200)

Histopathologic examination of the excised mass yielded cyst inner wall formed by stellate reticulum type, i.e., odontogenic, epithelium besides hyaline masses of dentin like tissue in a mature connective tissue background (Figure 3). There was prominent eosinophilic transformation of anucleated epithelial cells, i.e. ghost cells, (Figure 4). There was not any mitotic activity or invasive epithelial cell groups. In close approximation to these odontogenic epithelium eosinophilic hyaline masses of dysplastic dentine (dentinoid) without calcification was prominent (Figure 5). In other areas mononuclear inflammatory cells with some multinucleated foreign body giant cells could be seen. Based

on these histopathological features, a dentinogenic ghost cell was diagnosed. There was no evidence of malignancy on bony and mucosal margins. The patient with a gingival mass of six months duration underwent excisional biopsy. Excisional biopsy was remarkable with aberrant keratinization of odontogenic epithelium, i.e., ghost cell and dysplastic dentin. There was no sign of malignancy and there was not any postoperative complication. The patient is well without any recurrence after six months postoperatively.

DISCUSSION

Calcifying odontogenic tumors contain cystic, neoplastic elements in different proportions which are termed as dentinogenic ghost cell tumor, odontogenic ghost cell tumor, dentinoameloblastoma, calcifying ghost cell odontogenic tumor or epithelial odontogenic ghost cell tumor and formerly DGCT was considered a solid variant of the calcifying odontogenic cyst.^{2,4} The odontogenic ghost cell tumor was named first time as a different clinicopathologic entity by Gorlin et al in 1962.^{1,5} Dentinogenic ghost cell tumor is an odontogenic tumor characterised by ameloblastic odontogenic epithelial islands which show aberrant keratinization in the form of ghost cells and varying amounts of dysplastic hyaline masses of dentin.^{1,6} These tumors, are found almost always within the maxillofacial bones as central DGCT or in gingival region overlying tooth-bearing areas as peripheral DGCT (7). Dentinogenic ghost cell tumor may occur in any tooth-bearing area of the jaws. There is no preference for maxilla or mandible. The extraosseous variant shows for predilection for the anterior part of the jaws, while the intraosseous variant most often affects the canine to first molar region. The extraosseous variant presents as sessile, sometimes pedunculated, exophytic nodule of the gingival or alveolar mucosa. Many have occurred in edentulous areas. The size varies from 0.5-4.0 cm, but most are between 0.5 and 1 cm. The size of the intraosseous DGCT varies from 1 to more than 10 cm in diameter. There may be bony expansion and in some cases resorption of cortical bone with extension into soft tissues. Adjacent teeth may be displaced and mobile. Both intraosseous and extraosseous tumours are usually asymptomatic.² One to 2 percent of odontogenic tumors are calcifying odontogenic tumors and 2 to

14 percent of these are solid.^{1,8} There is also a malignant counterpart of DGCT.¹ The intraosseous DGCT is more aggressive than extraosseous DGCT and the intraosseous DGCT have more recurrence compared to the extraosseous DGCT.^{1,8}

Radiographs of the intraosseous tumours will show saucerization of the underlying bone in about 20% of the cases. Radiographs of the extraosseous tumours show a radiolucent to mixed radiolucent/radiopaque appearance depending on the amount of calcification. The borders are usually well demarcated. Most are unilocular. Resorption of adjacent teeth is a common finding, and associated impacted teeth have been described.² In this case imaging showed a well-defined radiolucency in close approximation to the tooth-bearing area of right lower anterior mandibular region.

The treatment of DGCT is by local resection or enucleation.¹ The intraosseous DGCT may be aggressive with wide local resection recommended, particularly if the tumour is radiologically ill-defined. Enucleation is an appropriate treatment of the extraosseous DGCT; no recurrences have been reported, except in some intraosseous cases, and even malignant transformation has been documented.²

REFERENCES

1. Quinn M, Brace M. Dentinogenic ghost cell tumor of the maxilla. *Otolaryngology-Head Neck Surg* 2008;139(4):604-5.
2. Praetorius F, Ledesma-Montes C. Dentinogenic ghost cell tumour. *World Health Organization Classification of Tumours. Pathology & Genetics Head and Neck Tumours*. Edited by Leon Barnes, John W. Evenson, Peter Reichart, David Sidransky. IARC Press, Lyon, 2005:314.
3. Tomich CE. Calcifying odontogenic cyst and dentinogenic ghost cell tumor. *Oral Maxillofac Surg Clin North Am* 2004;16(2):391-7.
4. Mori M, Kasai T, Nakai M, et al. Dentinogenic ghost cell tumor: histologic aspects, immunohistochemistry, lectin binding profiles, and biophysical studies. *Oral Oncology* 2000;36(1):134-43.
5. Gorlin RJ, Pindborg JJ, Clausen FP. Et al. The calcifying odontogenic cyst: A possible analogue of the cutaneous calcifying epithelioma of Malherbe. *Oral Surg Oral Med Oral Pathol Oral Radiol Endod* 1962;15(9):1235-43.
6. Ellis GL. Odontogenic ghost cell tumor. *Semin Diagn Pathol* 1999;16(2):288-92.
7. Alice E, Curran. Peripheral odontogenic tumors. *Oral Maxillofac Surg Clin N Am* 2004;16(2):399-408.
8. Stone CH, Gaba AR, Benninger MS, et al. Odontogenic ghost cell tumor: A case report with cytological findings. *Diagn Cytopathol* 1998;18(2):199-203.