

PAPER DETAILS

TITLE: Calculation of Intracranial Volume in Van Cats by Stereological Method

AUTHORS: Ali Koçyigit,Ismail Demircioglu,Osman Yilmaz

PAGES: 50-54

ORIGINAL PDF URL: <https://dergipark.org.tr/tr/download/article-file/3823189>



Calculation of Intracranial Volume in Van Cats by Stereological Method

Ali KOÇYİĞİT^{1,a}, İsmail DEMİRCİOĞLU^{2,b}, Osman YILMAZ^{3,c}

¹Harran University Laboratory and Veterinary Health Vocational School, Birecik, Şanlıurfa-TÜRKİYE

²Harran University, Department of Anatomy, Faculty of Veterinary Medicine, Eyyubiye, Şanlıurfa-TÜRKİYE

³Van Yüzüncü Yıl University, Department of Anatomy, Faculty of Veterinary Medicine, Van-TÜRKİYE

ORCID: ^a0000-0002-9354-7480; ^b0000-0002-0724-3019; ^c0000-0003-2013-9213

Corresponding author: Ali KOÇYİĞİT; E-mail: akocyigit@harran.edu.tr

How to cite: Koçyigit A, Demircioğlu İ, Yılmaz O. Calculation of intracranial volume in Van cats by stereological method. Erciyes Univ Vet Fak Derg 2024; 21(1):50-54

Abstract: Stereology is a powerful scientific method for estimating the real attributes of three-dimensional structures using calculations on two-dimensional photographs. The goal of this study was to determine the cerebral volume of cats using stereological cranial computed tomography (CT) and to uncover dimorphic differences. The study employed 16 adult Van cats (8 females and 8 males). A multislice CT equipment was utilized to scan the craniums of the cats involved in the study. Stereological computations were performed using 12 section images from cranial CT sections with intracranial borders calculated using a systematic random sampling procedure. Linear measurements of the intracranial region were also taken. When the findings were analysed, it was discovered that intracranial volume values differed across sexes ($P < 0.05$). It was determined that the measured linear parameters and calculated index values did not show dimorphism between the sexes ($P > 0.05$). As a result, it is thought that the determination of the intracranial volumes of Van cats using stereology method will contribute to clinical sciences in terms of diagnosis, detection and treatment of diseases and will allow the comparison of volume values calculated with different methods.

Keywords: Cavalieri's principle, intracranial volume, neurocranium, stereology

Van Kedilerinde İntrakranial Hacmin Stereolojik Yöntemle Hesaplanması

Öz: Stereoloji, üç boyutlu olan yapıların, iki boyutlu görüntüleri üzerinden hesaplamalar yaparak gerçek özelliklerinin tahmininin yapılabildiği etkili bilimsel bir yöntemdir. Bu çalışmada kedilerin kranial bilgisayarlı tomografi (BT) kullanılarak intrakranial hacminin stereolojik olarak belirlenmesi ve dimorfik farklılıklarının ortaya konulması amaçlandı. Çalışmada 16 adet (8 dişi, 8 erkek) erişkin Van Kedisi kullanıldı. Kullanılan kedilerin kranium'ları, çok kesitli BT cihazı ile tarandı. İntrakranial sınırları belirlenen BT kesitlerinden sistematik rastgele örneklem yöntemiyle 12 kesit görüntüsü alınarak stereolojik hesaplamalar yapıldı. Ayrıca intrakranial bölgenin lineer ölçümleri alındı. Elde edilen sonuçlar değerlendirildiğinde intrakranial hacim değerlerinin cinsiyetler arasında dimorfizm gösterdiği belirlendi ($P < 0.05$). Ölçülen lineer parametreler ve hesaplanan index değerlerinin ise cinsiyetler arası dimorfizm göstermediği belirlendi ($P > 0.05$). Sonuç olarak Van kedilerinin intrakranial hacimlerinin stereoloji yöntemi kullanarak belirlenmesi hem hastalıkların tanı, tespit ve tedavileri açısından klinik bilimlere katkı sağlayacağı hem de farklı metotlarla hesaplanan hacim değerlerinin karşılaştırılmasına imkan sağlayacağı düşünülmektedir.

Anahtar kelimeler: Cavalieri prensibi, intrakranial hacim, neurocranium, stereoloji

Introduction

The cranial cavity of the brain, liquor cerebrospinalis involves blood vessels and is surrounded by cavum cranii (Evans and De Lahunta, 2013; Rodrigues et al., 2010; König and Liebich, 2020). Intracranial volume is important for diagnosing neurodegenerative diseases and evaluating prognosis (Schofield et al, 1995). In addition, knowing the anatomical features of the intracranial region in animals without any pathology also helps to calculate the topographic positions of the organs to each other (Demircioğlu et al, 2021a). There are different methods to determine intracranial volume, among which the most widely used in recent

years are measurements made using imaging systems (Manjunath, 2002; Caruso et al., 2009; Yılmaz and Tugrul, 2019).

Stereology is a scientific method in which the real properties of three-dimensional structures can be estimated by making calculations on two-dimensional images (Mayhew and Gundersen, 1996). One of the frequently used methods in stereology is the Cavalieri Principle. Due to its high reliability, this method is used in many fields, as well as in the medical field, especially in experimental studies (Diab et al., 1998; Black, 1999; Sahin et al., 2003). Stereology is based on the principle of neutrality and effectiveness. It is known that the calculations do not statistically deviate from the true value by ensuring the validity of the principle of neutrality and effectiveness by using the

Cavalieri Principle on the sections obtained using cross-sectional medical imaging systems (Howard and Reed, 1998; Roberts et al., 2000).

In the study, it was aimed to calculate the intracranial volume of cats using cranial computed tomography (CT) images using stereological methods and to calculate the statistical difference between the sexes of the results obtained. In addition, it aimed to contribute to the limited literature in this field by comparing the intracranial volumes obtained in studies on different races and species.

Material and Method

The study 16 (8 female, 8 male) adult Van Cats in the study. Animal materials were obtained Van Yüzüncü Yıl University Van Cat Research and Application Centre. This study was approved by Van Yüzüncü Yıl University Animal Experiments Local Ethics Committee (Decision no: 2020/02). After the animals were sedated with Ketamine and Xylazine, the head region was scanned with a 16-slice computed tomography (CT) device (Somatom Sensation 16; Siemens Medical Solutions, Erlangen, Germany). CT parameters; KV / Effective mAs / Rotation time (sec) values 120/120/0.75; gantry rotation period 420 ms; physical detector collimation, 16×0.6 mm; section thickness, 0.75 mm; final section collimation, 32×0.63 mm; feed/rotation, 6mm; increment 0.5mm; The resolution was determined to be 512×512 pixels. Prokop (2003) and Kalra et al, (2004) were taken as reference in the screening and dosing protocol (Table 1).

Stereological calculations of 12 cross-section images were made using the mean sampling method from cranial CT sections with limited intracranial borders. The cross-sectional image was counted at 81 mm² intervals using the "Grid" option on the imageJ program and calculated according to the Cavalieri's principle (Figure 1). The same process was repeated a total of 3 times to be calculated at different times. Acer et al, (2007), Roberts et al, (1993), Gundersen and Jensen (1987) were referenced for the estimation of total intracranial volume. Intracranial cavity volumes were estimated using the following equation:

$$V = \sum p \times t \times a(p)$$

The coefficient of error (CE) was estimated by taking Sahin et al, (2003), Roberts et al, (1993), and Roberts et al, (1994) as reference.

Measurements are taken from the cranial cavity (Figure 2): Measurement of the cranial cavity.

MWCC: Maximum width of the cranial cavity, [Euryon -Euryon (intracranial border)]

MHCC: Maximum height of the cranial cavity, (maximum distance between the floor of the intracranial compartment and the intracranial cavity roof)

MLCC: Maximum length of the cranial cavity (From akrokranon to the lamina cribrosa ossis etmoidale)

Index 1 (Cranial cavity index): maximum width of the cranial cavity x 100 / maximum length of cranial cavity

Index 2 (Length width index): maximum length of cranial cavity / maximum width of the cranial cavity (Künzel et al., 2003; Onar et al., 2002).

For statistical data, SPSS 20 program was used. In the study, normality was subjected to the Shapiro-Wilk test. Independent t-test was applied to the differences between the sexes.

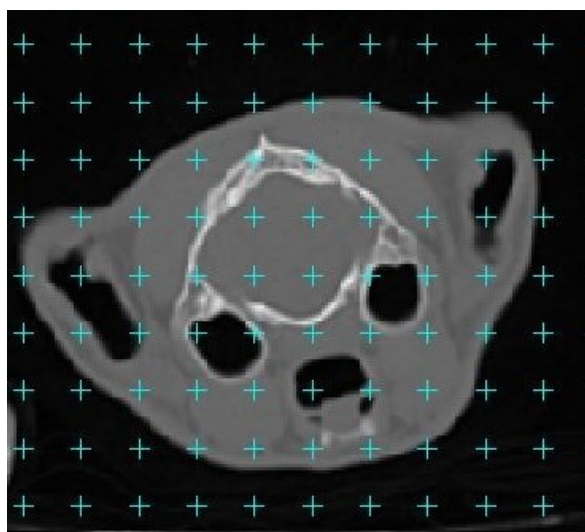

Figure 1: A point counting grid that superimposed on CT slice.

Table 1. Computed tomography scan parameters

Computed Tomography		Parameters
Rotation time (sec)	0.75	0.75
Kv	120	120
mAs	120	120
Thickness slice	0.75 mm	0.75 mm
Resolution	512x512	512x512
increment	0.5 mm	0.5 mm
Position	Coronal	Sagittal

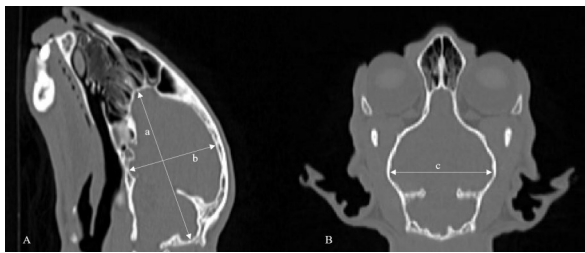


Figure 2: Intracranial linear measuring points (A) Sagittal plane, (B) Coronal plane. a: Maximum length of the cranial cavity, b: Maximum height of the cranial cavity, c: Maximum width of the cranial cavity.

Results

The mean and dimorphic values obtained as a result of the stereological calculations of the intracranial volumes of the cats in the study are given in Table 2. According to Table 2, it was observed that there was a statistically significant $P < 0.005$ difference between the sexes in intracranial volume values.

Table 2. Sexual dimorphic values of intracranial volume (cm³)

Gender	n	Minimum	Maximum	Mean	Standard deviation	CE	P
Male	8	26.97	30.46	28.17	1.19	0.03	0.024
Female	8	26.16	27.86	26.99	0.57		

Data are normally distributed, there is a significant difference between males and females ($P < 0.05$)

Linear measurements of the intracranial space by gender and the index values obtained from these measurements are given in Table 3. When Table 3 was examined, it was determined that intracranial parameters and calculated index values did not show statistical dimorphism between genders ($P > 0.05$).

Table 3. Parameter of the cranial cavity (mm)

	Gender	n	Minimum	Maximum	Mean	Standard deviation	P
MWCC	Male	8	37.18	40.58	38.59	1.09	0.355
	Female	8	37.84	39.97	39.06	0.83	
MHCC	Male	8	28.61	31.97	30.22	1.23	0.131
	Female	8	27.8	30.83	29.37	0.85	
MLCC	Male	8	50.05	56.82	54.17	2.98	0.972
	Female	8	52.62	56.97	54.21	1.38	
Index1	Male	8	66.44	77.67	71.47	5.00	0.758
	Female	8	69.19	75.23	72.08	2.26	
Index2	Male	8	1.29	1.51	1.405	0.01	0.674
	Female	8	1.33	1.45	1.39	0.04	

Data are normally distributed, no significant difference between males and females ($P > 0.05$); MWCC: Maximum width of the cranial cavity, MHCC: Maximum height of the cranial cavity, MLCC: Maximum length of the cranial cavity.

Discussion and Conclusion

By using the Cavalieri principle on the cross-sectional images obtained by CT method, the volume value is obtained in an unbiased and effective manner, and it also minimizes the margin of error by separating it from the surrounding structures more easily. In the

light of this information, the intracranial volume and linear measurements of Van cats were determined by stereological method.

When calculating the volume according to the Cavalieri principle, the use of a dotted area measurement ruler can be used safely in many disciplines (Altındal et al., 2018). In our study, using the dotted area measurement ruler in volume calculation, it will allow us to compare the method between the volume values calculated with the modelling programs today. Although there are studies on intracranial parameters of some animal species (Sahin et al., 2001; Onar et al., 2002; MacKillop, 2011; Demircioğlu et al., 2021a; Demircioğlu et al., 2021b), data in this area are quite limited. Sahin et al. (2001) reported that the brain volume was 59.24 ± 13.09 cm³ in female rats and 60.55 ± 17.12 cm³ in males. Demircioğlu et al. (2021b) reported that the intracranial volumes of gazelles were calculated stereological as 80.80 ± 8.01 cm³ in females and 78.77 ± 7.50 cm³ in males and that they did not show dimorphism between the sexes. In the

study of Mayhew et al. (1990), in which the brain volume of cats and dogs was calculated stereological, the brain volume of the cat was 15.9cm³, reported dog's brain volume as 48.7cm³. Yılmaz and Tuğrul (2019) found that the total brain volume of Van cats was calculated with the Prowess Panther Treatment

Planning System V5.01 software on CT images, and the total brain volume was 20.72 ± 1.71 cm³ in females and 23.26 ± 1.80 cm³ in males. reported that there was a statistically significant $P < 0.005$ difference between the sexes. In the study, it was determined that the mean value of the total intracranial volume of Van cats was 26.99 ± 1.19 cm³ in females and 28.17 ± 0.57

cm³ in males and statistically $P < 0.05$ dimorphism was observed between the sexes. It is thought that these value differences observed between the study and the study of Yılmaz and Tuğrul (2019) may be caused by other structures and method differences in the intracranial cavity other than the brain.

Regodon et al. (1991) calculated cranial volumes in dogs of different breeds by computed tomography and stated that the sexes could be separated by cranial volume at a rate of 99.99%. The study confirms this information, and it has been determined statistically that intracranial volumes show dimorphism on genders.

Thanks to medical imaging methods, fast, safe and high-accuracy measurements can be taken on the brain and brain-related structures (Kurtoğlu, 2013; Demircioğlu et al., 2021c). In the study, MWCC, MHCC, MLCC values, which are intracranial linear measurement parameters of cats, were measured and two index values were calculated using this value. In the statistical analysis of our measured parameters, it was determined that there was no dimorphism between the sexes. Demircioglu et al. (2021b), in their study on gazelle intracranial parameters and index values, reported that these findings did not show a statistical difference between genders. Our findings are compatible with this literature.

As a result, in the study, intracranial linear measurements and volume of Van cats were determined stereologically and the differences between the sexes were determined. We believe that our study data is important in terms of revealing the limited data in this area and evaluating various neuroanatomical structures and many neurodegenerative diseases.

References

- Acer N, Sahin B, Bas O, Ertekin T, Usanmaz M. Comparison of three methods for the estimation of total intracranial volume: stereologic, planimetric, and anthropometric approaches. *Ann Plas Surg* 2007; 58(1): 48-53.
- Altındal F, Onur Ş, Acar K. İnsan craniumlarında intrakranial hacim, basis cranii externa yüzey alanı ve foramen magnum kesitsel alanı arasındaki ilişki. *Pam Tıp Derg* 2018; 11(3): 237-49.
- Black KJ. On the efficiency of stereologic volumetry as commonly implemented for three-dimensional digital images. *Psychiatry Res* 1999; 90(1): 55-64.
- Caruso PA, Roberston R, Setty B, Grant E. Disorders of brain development. Atlas SA. ed. In: *Magnetic Resonance Imaging of the Brain and Spine*. Fourth Edition. Philadelphia: Lippincott Williams & Wilkins, 2009; pp. 194-271.
- Demircioglu I, Demiraslan Y, Gurbuz I, Dayan MO. Examination of the topography and morphometry of Hypophysis (*Glandula pituitaria*) in New Zealand rabbit by computed tomography. *Atatürk University J Vet Sci* 2021a; 16(2): 170-5.
- Demircioğlu İ, Koçyiğit A, Aydoğdu S, İnce NG, Yılmaz B. Calculation of the intracranial volume in Gazelles (*Gazella subgutturosa*) by stereology and computed tomography. *Harran Üniv Vet Fak Derg* 2021b; 10(2): 178-83.
- Demircioğlu İ, Koçyiğit A, Demiraslan Y, Yılmaz B, İnce NG, Aydoğdu S, Dayan MO. Digit bones (Acropodium) of gazella (*Gazella subgutturosa*); Three-dimensional modelling and morphometry. *Pak Vet J* 2021c; 41(4): 481-6.
- Diab KM, Ollmar S, Sevastik JA, Willers U, Svensson A. Volumetric determination of normal and scoliotic vertebral bodies. *Eur Spine J* 1998; 7(4): 282-8.
- Evans HE, De Lahunta A. Miller's Anatomy of The Dog. Fourth Edition. Missouri, USA: Elsevier Health Sciences 2013; pp. 70-156.
- Gundersen HJG, Jensen EB. The efficiency of systematic sampling in stereology and its prediction. *J Microsc* 1987; 147(3): 229-63.
- Howard V, Reed M. Unbiased Stereology: Three-Dimensional Measurement in Microscopy. Oxford: Bios Scientific Publishers 1998; pp. 39-65.
- Kalra MK, Maher MM, Toth TL, Hamberg LM, Blake MA, Shepard JA, Saini S. Strategies for CT radiation dose optimization. *Radiology* 2004; 230(3): 619-28.
- König HE, Liebich HG. Veterinary Anatomy of Domestic Animals: Textbook and Colour Atlas. New York, USA: Georg Thieme Verlag 2020; pp. 39-162.
- Kurtoğlu E. Değişik yazılımlar kullanılarak beyin hacminin ve yüzey alanının MR görüntüleri ile hesaplanması, Yüksek lisans tezi, Erciyes Üniv Sağ Bil Enst, Kayseri 2013; s. 13-67.
- Künzel W, Breit S, Oppel M. Morphometric investigations of breed-specific features in feline skulls and considerations on their functional implications. *Anat Histol Embryol* 2003; 32(4): 218-23.
- MacKillop E. Magnetic resonance imaging of intracranial malformations in dogs and cats. *Vet Radiol Ultrasound* 2011; 52(1): 542-51.
- Manjunath KY. Estimation of cranial volume in dissecting room cadavers. *J Anat Soc India* 2002; 51(2): 168Y172.

- Mayhew TM, Gundersen HJ. If you assume, you can make an ass out of u and me': A decade of the disector for stereological counting of particles in 3D space. *J Anat* 1996; 188(Pt 1): 1-15.
- Mayhew TM, Mwamengele GLM, Dantzer V. Comparative morphometry of the mammalian brain: Estimates of cerebral volumes and cortical surface areas obtained from macroscopic slices. *J Anat* 1990; 172: 191-200.
- Onar V, Kahvecioglu KO, Çebi V. Computed tomographic analysis of the cranial cavity and neurocranium in the German shepherd dog (Alsatian) puppies. *Vet Arh* 2002; 72(2): 57-66.
- Prokop M. General principles of MDCT. *Eur J Radiol* 2003; 45: 4-10.
- Regodon S, Franco A, Garin JM, Robina A, Lignereux Y. Computerized tomographic determination of the cranial volume of the dog applied to racial and sexual differentiation. *Acta Anat (Basel)* 1991; 142(4): 347-50.
- Roberts N, Cruz-Orive LM, Reid NMK, Brodie DA, Bourne M, Edwards RHT. Unbiased estimation of human body composition by the Cavalieri method using magnetic resonance imaging. *J Microsc* 1993; 171(3): 239-53.
- Roberts N, Garden AS, Cruz-Orive LM, Whitehouse GH, Edwards RH. Estimation of fetal volume by magnetic resonance imaging and stereology. *Br J Radiol* 1994; 67(803):1067-77.
- Roberts N, Puddephat MJ, McNulty, V. The benefit of stereology for quantitative radiology. *Br J Radiol* 2000; 73(871): 679-97.
- Rodrigues RTS, Matos WCG, Walker FM, Costa FS, Wanderley CWS, Neto JP, Faria MD. Dimensions of the cranium and of the cranial cavity and intracranial volume in goats (*Capra hircus* LINNAEUS, 1758). *J Morphol Sci* 2010; 27(1): 6-10.
- Sahin B, Aslan H, Unal B, Canan S, Bilgic S, Kaplan S, Tumkaya L. Brain volumes of the lamb, rat and bird do not show hemispheric asymmetry: A stereological study. *Image Anal Stereol* 2001; 20(1): 9-13.
- Sahin B, Emirzeoglu M, Uzun A, Incesu L, Bek Y, Bilgic S, Kaplan S. Unbiased estimation of the liver volume by the Cavalieri principle using magnetic resonance images. *Eur J Radiol* 2003; 47(2): 164-70.
- Schofield PW, Mosesson RE, Stern Y, Mayeux R. The age at onset of Alzheimer's disease and an intracranial area measurement: A relationship. *Arch Neurol* 1995; 52(1): 95-8.
- Yılmaz O, Tuğrul T. Van kedilerinde total beyin hacminin bilgisayarlı tomografi görüntüleri kullanılarak hesaplanması. *Eurasian J Bio Chem Sci* 2019; 2(2): 42-6.

