

PAPER DETAILS

TITLE: Semptomsuz Periapikal Aktinomikoz: Siradisi Bir Vaka

AUTHORS: Esengöl BEKAR, Nilüfer Çakır ÖZKAN, Filiz KARAGÖZ

PAGES: 70-75

ORIGINAL PDF URL: <https://dergipark.org.tr/tr/download/article-file/403709>

Semptomsuz Periapikal Aktinomikoz: Sıradışı Bir Vaka
Asymptomatic Periapical Actinomycosis: An unusual case
Esengül Bekar¹, Nilüfer Çakır Özkan¹, Filiz Karagöz²

Özet

Periapikal aktinomikoz, maksillofasiyal bölgede nadir görülen bir enfeksiyondur. Bu vaka raporunda biyopsi sonucuna göre periapikal aktinomikoz olarak teşhis edilen periapikal bir lezyon anlatılmıştır.

Kliniğimize başvuran 53 yaşında bayan hastada, klinik olarak herhangi bir semptom gözlenmemesine rağmen radyografik olarak sol birinci premolar dişinin apikal bölgesinde düzensiz sınırlı radyolüsent alan tespit edildi. Çıkarılan periapikal lezyon histopatolojik inceleme sonucunda periapikal aktinomikoz olarak değerlendirildi. Bu vaka raporunda periapikal radyolüsent görüntülerin çeşitli patolojik durumlardan kaynaklanabileceği ve çıkarılan her patolojik dokunun histopatolojik incelemesinin mutlaka yapılması gerektiği vurgulanmıştır.

Anahtar Kelimeler: Aktinomikozis, periapikal lezyon, oral cerrahi.

Abstract

Periapical actinomycosis is a rare infection in maxillofacial region. This case report describes a periapical lesion diagnosed as periapical actinomycosis accidentally on the basis of biopsy results. A 53-year-old female patient referred to our clinic. There was no clinical signs and symptoms. Radiographically, irregular radiolucency was observed at the periapical region of the left mandibular first premolar. Histopathological examination of the removed periapical tissue showed periapicalactinomycosis. This case report illustrates the point that periapicalradiolucencies may result from different pathologies and the granulation tissue removed during tooth extraction should be submitted for histopathologic examination.

Keywords: Actinomycosis, periapical lesion, oral surgery.

¹Ondokuz Mayıs University, Faculty of Dentistry, Department of Oral and Maxillofacial Surgery, Samsun, Turkey

²OndokuzMayıs University, Faculty of Medicine, Department of Pathology, Samsun, Turkey

Yazışma Adresi:

Dt. Esengül Bekar

OndokuzMayıs University, Faculty of Dentistry, Department of Oral and Maxillofacial Surgery, Samsun, Turkey

E-

mail:esengulbekar@yahoo.com

Giriş

Actinomycosis is an infection caused by filamentous, branching, Gram-positive anaerobic bacteria and normally colonizes mouth, colon and urogenital tract. These microorganisms are not virulent. When the mucosal disruption occurs, they lead to infection. Periapical actinomycosis is a nonresolving lesion associated with actinomycotic infection and has been suggested as a contributing factor in the perpetuation of periapical radiolucencies after root canal therapy. Periapicalactinomycosis is one of the rarest forms of actinomycosis occurring in the maxillofacial region. It generally presents in the form of persistent and recurrent draining fistula in the periapical region (1,2).

This case report describes an unusual asymptomatic periapical lesion accidentally diagnosed as periapicalactinomycosis on the basis of biopsy results.

Case Report

A 53-year-old female patient referred to our clinic with an apical lesion caused by left mandibular first premolar. The lesion was diagnosed in routine dental examination. In intraoral examination there was no pain, pus discharge or sinus tract. In radiographic examination a 1x1 cm irregular radiolucency in the periapical region of left mandibular first premolar and canine (Figure 1). The canine was vital. The first premolar was extracted because of lack of bone support and apical curettage was done. A provisional diagnosis of periapical granuloma was made. Postoperative antibiotics (625 mg amoxicillin+clavulanic acid) were given

twice a day for five days. After one week the patient has no symptoms related with operation.

Histopathological examination of the removed periapical tissue showed actinomyces colonies in the granulation tissue (Figure 2, 3). The lesion was diagnosed as periapical actinomycosis histopathologically. It was seen there was a complete recovery in the 6 months follow-up period (Figure 4).

Figure 1. Preoperative radiograph showing periapical radiolucency.

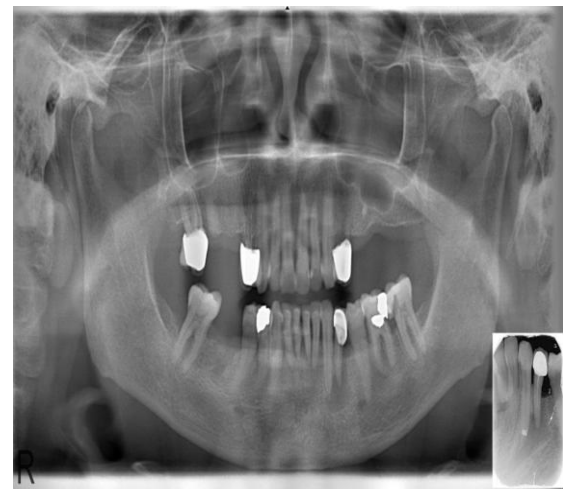


Figure 2. Granulation tissue with inflammatory infiltration and vascular proliferation with actinomyces colonies (H&E staining x200).

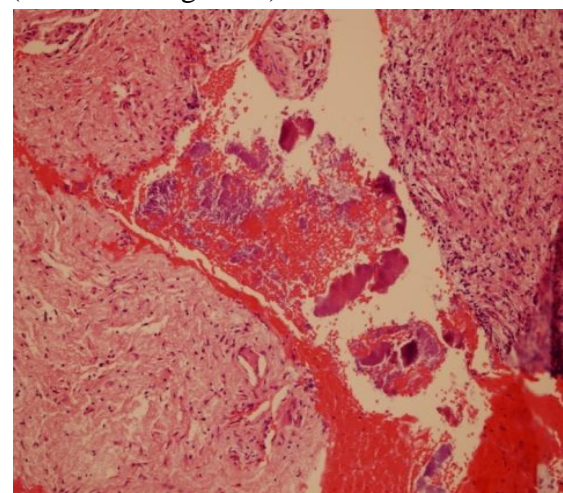


Figure 3. Actinomycotic colonies in fibrin tissue (Periodic acid Schiff stain x 100)

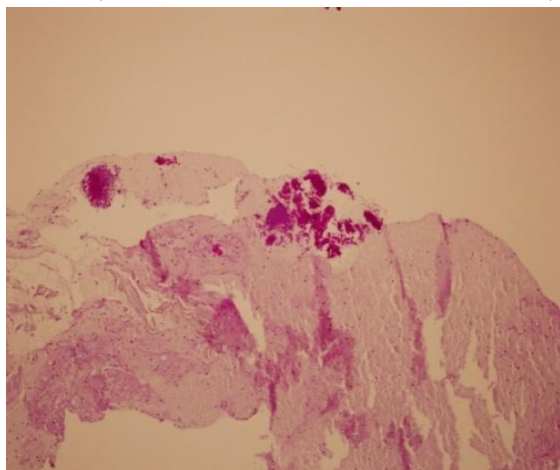
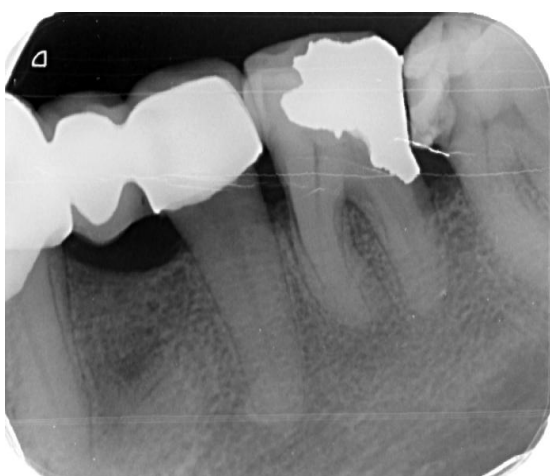

Figure 4. Postoperative radiograph showing the healing of bone defect 3 months after surgery



Discussion

Actinomycosis is caused by anaerobic Gram-positive *Actinomyces* species which exist in oral cavity, gastrointestinal tract, and urogenital tract. When the mucosal barrier is disrupted by trauma, surgery or preceding infection, bacteria can invade the adjacent tissues. These bacteria can produce chronic pus forming inflammation and spread unchecked through several tissues (3,4).

Cervicofacial actinomycosis is further classified into central and peripheral types, of which the central variety is very rare in nature with the incidence of 1–2%. Periapical actinomycosis is accepted as central varieties. The most common actinomyces species that cause this infection are *Actinomyces israelii*, *Actinomyces naeslundii*, *Actinomyces odontolyticus*, *Actinomyces viscosus*, *Actinomyces Meyer* and *Actinomyces Gerencseriae* (4). The infection occurs when the mucosal barrier is disrupted by invasive dental procedures like fractures, dental extractions, puncture wounds and etc (5).

Periradicular actinomycosis is one important reason for failure of nonsurgical endodontic treatment. According to the literature root canal therapy can also cause periapical actinomycosis by displacement of microorganisms from oral cavity to periapical region (6,7). In accordance with the literature, our patient underwent root canal therapy years ago. Actinomycosis has no predilection for age, race, season or occupation but it is found that it has a relation with immunodeficiency (8). But, our patient has no systemic disease or immunodeficiency. Moreover, sinus tracts can be seen frequently in previously reported cases (9). Different from the literature, in our case, no sinus tract or mucosal disruption have been seen in intraoral examination. Because of nonspecific manifestations, clinical differential diagnosis of actinomycosis is difficult. In the cases of actinomycosis associated with periapical and periodontal pathology have been frequently seen inflammation, swelling, erythema, pain and sinus tract formation. Rarely, in some cases there is no clinical signs and symptoms. In such cases, it is thought that

the bacterial load is low. Because of nonspecific manifestations, clinical differential diagnosis of actinomycosis is difficult. Therefore, histopathologic examination is necessary for definitive diagnosis. Especially in such asymptomatic cases, after extraction remnant granulation tissue might have kept its low-grade actinomycotic activity. The resistant nature of actinomycosis may demonstrate unusual recurrences even after years (10). Similar to above mentioned hypothesis, there was no clinical signs and symptoms in our case. Only, periapical bone destruction was seen on the radiographic examination.

Cervicofacialactinomycosis is one of the conditions requiring longer antibiotic treatment compared with the other dental infections. But periapicalactinomycosis present an indolent form of actinomycosis and usually resolve after tooth extraction, curettage or within 1-2 weeks of antibiotic treatment. Antibiotic was given for a week to our patient and the healing was uneventful for 3 months follow-up period (9,10).

Conclusion

This case report illustrates the point that periapical radiolucencies may result from different pathologies and the granulation tissue removed during tooth extraction should be submitted for histopathological examination. Because, it could contribute to better understanding of the cause for inflammation and possibly this can improve treatment.

Periapical actinomycosis is a challenging diagnosis because of its uncertain clinical view and the diagnosis is often missed. Ultimately, a definitive diagnosis can be confirmed only by histopathologic examination. It should be

included in differential diagnosis of periapical pathology like periapical granuloma, periapical cysts and periapical abscess.

References

1. Sehouli J, Stupin JH, Schlieper U, Kuemmel S, Henrich W, Denkert C, et al. Anticancer Res. Actinomycotic inflammatory disease and misdiagnosis of ovarian cancer. A case report. *Anticancer Res.* 2006;26:1727-31.
2. Sarkonen N, Kononen E, Summanen P, Kanervo A, Takala A, Jousimies-Somer H. Oral colonization with *Actinomyces* species in infants by two years of age. *J Dent Res.* 2000;79:864-7.
3. Nikolaitchouk N, Hoyles L, Falsen E, Grainger JM, Collins M. Characterization of *Actinomyces* isolates from samples from the human urogenital tract: description of *Actinomyces urogenitalis* sp. nov. *Int J Syst Evol Microbiol.* 2000;50:1649-54.
4. Lancella A, Abbate G, Foscolo AM, Dosdegani R. Two unusual presentations of cervicofacial actinomycosis and review of the literature. *Acta Otorhinolaryngol Ital.* 2008;28:89-93.
5. Weese WC, Smith IM. A study of 57 cases of actinomycosis over a 36-year period. A diagnostic 'failure' with good prognosis after treatment. *Arch Intern Med.* 1975;135:1562-8.
6. Jeansonne BG. Periapical actinomycosis: a review. *Quintessence Int.* 2005;36:149-53.
7. Ricucci D, Siqueira JF. Apical actinomycosis as a continuum of intraradicular and extraradicular infection: case report and critical review on its involvement with

- treatment failure. J Endod. 2008;34:1124–9.
8. Hirshberg A, Tsesis I, Metzger Z, Kapla I. Periapical actinomycosis: A clinicopathologic study. Oral Surg Oral Med Oral Pathol Oral Radiol Endod. 2003;95:614–20.
 9. Becker DG, McKinney CD, Hahn JF, Rebel JF. Abscess with sulfur granules with organisms consistent with Actinomyces species. Arch Otolaryngol Head Neck Surg. 1992;118:1359-60.
 10. Göçmen G, Varol A, Göker K, Basa S. Actinomycosis: Report of a case with a persistent extraoral sinus tract. 2011;112:121-3.

