

## PAPER DETAILS

TITLE: Internal Karotid Arterin Spontan Tıkanması ve Anevrizma Gelişimi: Olgu Sunumu

AUTHORS: Fatih Ersay Deniz,Özgür Demir,Erol Öksüz,Selçuk Palaoglu

PAGES: 132-137

ORIGINAL PDF URL: <https://dergipark.org.tr/tr/download/article-file/403721>

**İnternal Karotid Arterin Spontan Tıkanması ve Anevrizma Gelişimi: Olgu Sunumu**  
**Spontaneous Occlusion of Internal Carotid Artery and Aneurysm**

**Formation: Case Report**

**Fatih Ersay Deniz<sup>1</sup>, Özgür Demir<sup>1</sup>, Erol Öksüz<sup>1</sup>, Selçuk Palaoğlu<sup>2</sup>**

**Özet**

Subaraknoid kanama nedeniyle, 68 yaşındaki erkek hasta değerlendirildi. Angiografi tetkikinde sol internal karotid arterin tıkalı olduğu, ayrıca anterior kommunikan arter anevrizması olduğu tespit edildi. Bilgisayarlı tomografi tetkiki ile her iki karotid kanalın mevcut olduğu tespit edildi. Pterional kraniotomi ile anevrizma başarılı olarak kliplendi. Hastanın ameliyat sonrası döneminde kliniği vasospazm gelişmiş olduğunu telkin edecek şekilde sorunlu oldu ve hasta ameliyat sonrası 18. günde vefat etti. Tek taraflı internal karotid arter yokluğunda, kanamış bir anevrizmayı ameliyat etmeden önce anormal damarsal anatomi dikkatli bir şekilde incelenmelidir. Cerrah, ameliyata bağlı risklerin yüksek olabileceğinden dolayı dikkatli olmalıdır.

**Anahtar Kelimeler:** Karotid arter trombozu; intrakranial anevrizma; subaraknoid kanama

**Abstract**

A 68-years-old patient was evaluated for subarachnoid hemorrhage. Angiography revealed aneurysm of the anterior communicating artery and absence of the left internal carotid artery. Presence of the both bony carotid canals were demonstrated by computed tomography. Successful clipping was performed via a right pterional approach. Postoperative course was eventful and suggested vasospasm. The patient died at post-operative eighteenth day. Abnormal vascular anatomy should be carefully studied prior to direct surgery for a ruptured aneurysm in patients with unilateral agenesis of the internal carotid artery. The surgeon should be aware of the higher risks of the operation.

**Key Words:** Carotid artery thrombosis; intracranial aneurysm; subarachnoid hemorrhage

<sup>1</sup>Gaziosmanpaşa

University Department of  
Neurosurgery.

<sup>2</sup>Hacettepe University  
Department of  
Neurosurgery.

**Correspondence**

Fatih Ersay Deniz, M.D.

Gaziosmanpaşa  
Üniversitesi Hastanesi  
Beyin ve Sinir Cerrahisi  
AD.

60100, Tokat - Turkey

**Phone:** 3562129500 -  
1292

**E-mail:**  
ersaymd@yahoo.com

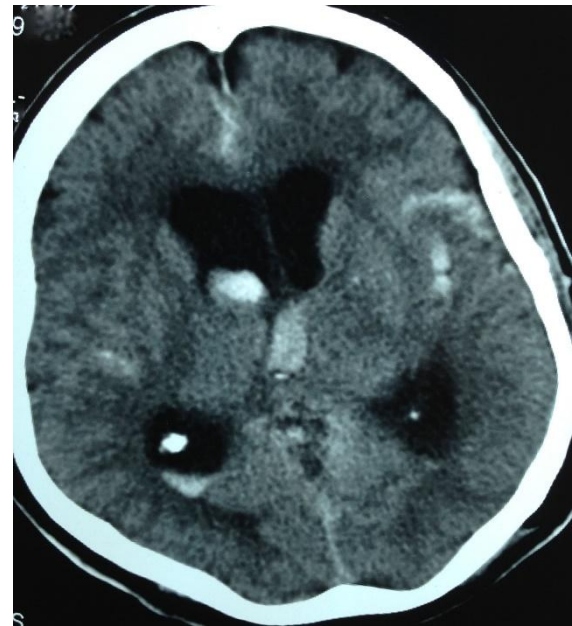## Introduction

Spontaneous occlusion of the internal carotid artery (ICA) is a rare entity. It may be developed due to chronic dissection, fibro muscular dysplasia and severe atherosclerosis. Congenital ICA malformations such as agenesis, aplasia and hypoplasia have to be excluded by imaging techniques. The presence of the bony carotid canal should be demonstrated by computerized tomography (CT) and the vessels by dopler ultrasound and angiography to exclude congenital ICA malformations. Intracranial aneurysm incidence is higher in those patients but the exact frequency of the concurrence is not known (1). Although the patients may remain asymptomatic due to the collateral blood supply, morbidity and mortality rate of operation in those patients can be higher.

## Case Report

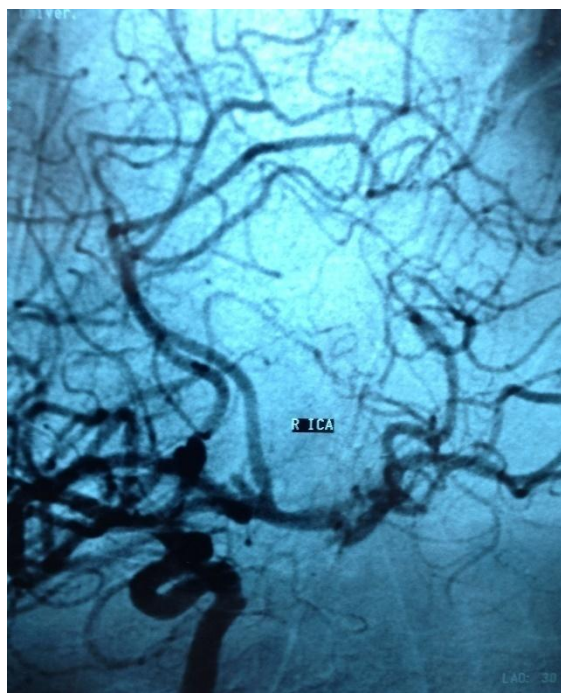A 68-years-old male patient was admitted to our hospital with persistent headache and disturbance of consciousness. Neurological examination revealed somnolence and nuchal rigidity. CT scan showed subarachnoid haemorrhage (SAH) and hydrocephalus (Figure 1).

**Figure 1.** Preoperative CT revealed SAH and hydrocephalus.

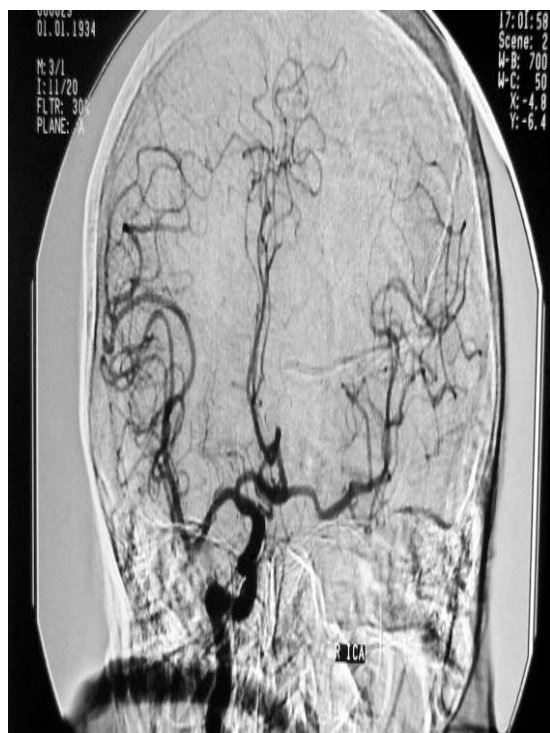

The patient was evaluated as grade 4 according to both World Federation of Neurosurgical Societies grading system and Fisher's classification. Ventricular drainage was performed to relieve hydrocephalus. Angiography revealed an aneurysm of the anterior communicating artery (ACoA) (Fig. 2), absence of the left ICA and both anterior cerebral arteries (ACA) and middle cerebral arteries (MCA) perfusing from the right ICA via the ACoA (Fig. 3, 4). Presence of the left carotid canal was demonstrated on CT (Fig. 5). Angiographic atherosclerotic findings and presence of the bony carotid canal suggested spontaneous occlusion of ICA. Successful clipping was performed via a right pterional approach. Postoperative course was eventful and suggested vasospasm (Fig. 6). The patient died at post operative eighteenth day.

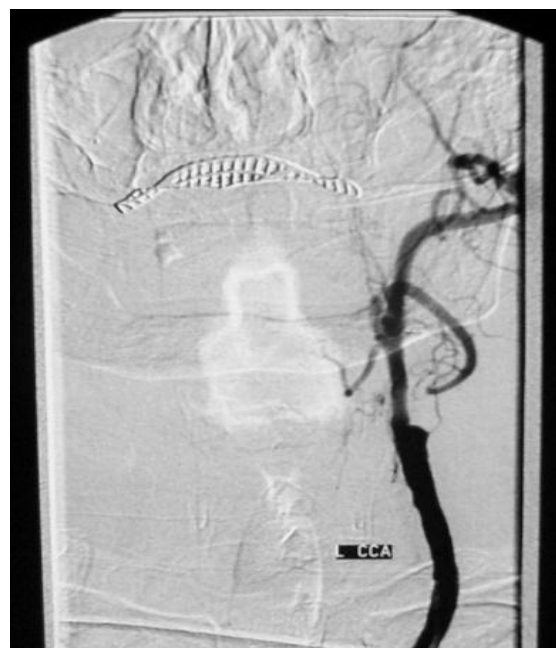**Figure 2.** Angiography revealed an aneurysm of the ACoA.



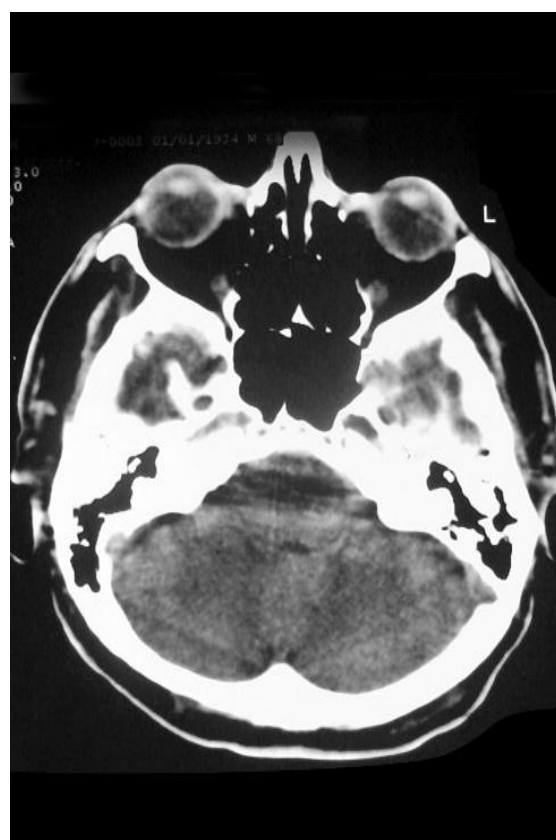
**Figure 3.** Angiography from right ICA showing ACoA left MCA perfusing via ACoA.



**Figure 4.** Angiography showing absence of the left ICA (ICA= internal carotid artery).

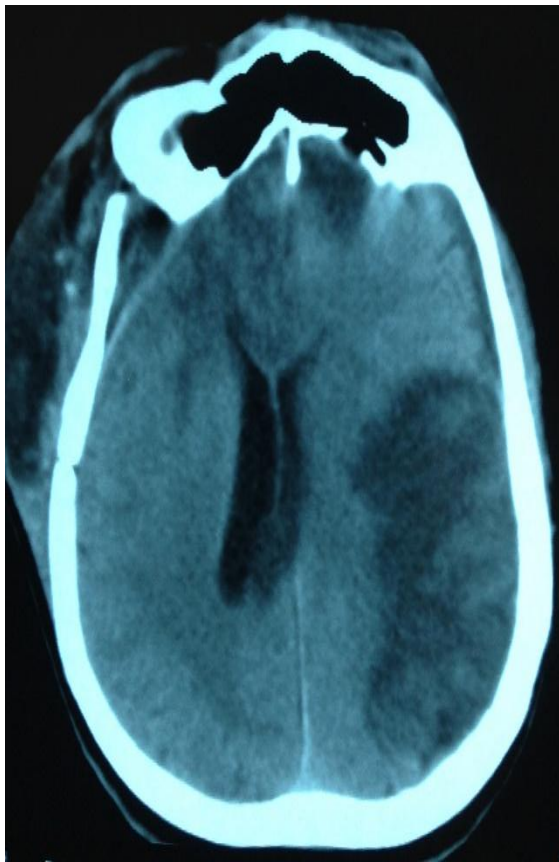

**Figure 5.** CT showed both carotid canals.





**Figure 6.** Postoperative CT revealed cerebral ischemia due to vasospasm.



## Discussion

Haemodynamic stress and hypertension have been regarded as causative factors of cerebral aneurysm as well as congenital anomaly of cerebral arterial structure (1,2). Bidzinski et al. reported 921 patients diagnosed and treated for intracranial aneurysm; co-existence of ruptured aneurysm and occlusion of ICA was found in 5 patients. In 4 of 5 cases the aneurysm was located on the ACoA (2). Timperman et al. reported 58 balloon occlusions for unclippable giant aneurysms of the ICA; two cases of SAH caused by aneurysm development and enlargement in the ACoA complex were detected (3). Niirio et al. reported eleven patients treated by only proximal occlusion for giant cavernous sinus aneurysms; new formations of aneurysms were detected 13 and 17 years

later in two (4). All of these series were aneurysm patients, therefore the only causative factor of the newly developed aneurysms may not be the haemodynamic stress as explained before.

The estimated prevalence of cerebral aneurysms in the general population is 2% to 4%. The reported incidence of symptomatic aneurysm formation after carotid ligation is between 4% and 10 %. The reported prevalence of aneurysms in association with congenital absence of the ICA is 24% to 34% (5,6). This is probably due to a long period of haemodynamic stress accompanied by developmental vascular defect. The exact frequency of cerebral aneurysm formation in spontaneous occlusion of ICA is not known.

Although the patients may remain asymptomatic in ICA anomaly because of the collateral blood supply, recognition of the anomaly has important implication during planned surgery for the aneurysm. Recognition of the anomaly is also important in transsphenoidal hypophyseal surgery due to intercavernous collaterals, in carotid endarterectomy as both cerebral hemispheres may be dependent upon the atheromatous carotid and in thromboembolic disease as emboli may be explained by the contralateral atherosclerotic disease of the ICA. In cases with poor collateral blood flow, extra-intracranial bypass surgery may be necessary before aneurysm occlusion (7). From our experience, abnormal vascular anatomy should be carefully studied prior to direct surgery for a ruptured aneurysm in patients with unilateral agenesis of the ICA. The surgeon should be aware of the higher risks of the operation (8,9).

Asymptomatic patients of major vessel occlusion should be followed up using non-invasive imaging studies such as magnetic resonance angiography or CT angiography. The long term follow up of spontaneous occlusion of ICA patients by imaging studies will help to determine the role of haemodynamic stress in aneurysm formation.

## References

1. Florio F, Balzano S, Nardella M, Strizzi V, Cammisa M, Bozzini V, et al. Congenital absence of the internal carotid artery. *Cardiovasc Intervent Radiol*. 1999;22:74-8.
2. Bidzinski J, Bonicki W, Kolyty GV, Zareba A. Ruptured intracranial aneurysm associated with spontaneous occlusion of internal carotid artery. Experience with 5 cases. *Acta Neurochir (Wien)*. 1989;100:43-5.
3. Timperman PE, Tomsick TA, Tew JM, Van Loveren HR. Aneurysm formation after carotid occlusion. *AJNR Am J Neuroradiol* 1995;16:329-31.
4. Given AC, Hellinger FH, Baker MC, Chepuri NB, Morris PP. Congenital absence of the internal carotid artery: case reports and review of the collateral circulation. *AJNR Am J Neuroradiol*. 2001;22:1953-9.
5. Dyste GW, Beck DW. De Novo aneurysm formation following carotid ligation: case report and review of the literature. *Neurosurgery*. 1989;24:88-92.
6. Niino M, Shimozuru T, Nakamura K, Kadota K, Kuratsu J. Long-term follow-up study of patients with cavernous sinus aneurysm treated by proximal occlusion. *Neurol Med Chir (Tokyo)*. 2000;40:88-96.
7. Inoue T, Tsutsumi K, Adachi S, Tanaka S, Saito K, Kunii N. Clipping and superficial temporal artery-M2 bypass for unruptured anterior communicating artery aneurysm associated with atherosclerotic internal carotid artery occlusion: report of 2 cases. *Surg Neurol*. 2007;68:226-31.
8. Dehdashti AR, de Tribolet N. Giant intracavernous aneurysm thrombosis by spontaneous carotid occlusion. *Cerebrovasc Dis*. 2003;15:301-2.
9. Vasconcellos LP, Flores JA, Conti ML, Veiga JC, Lancellotti CL. Spontaneous thrombosis of internal carotid artery: a natural history of giant carotid cavernous aneurysms. *Arq Neuropsiquiatr*. 2009;67:278-83.

