

## PAPER DETAILS

TITLE: Morphometric analysis of orbit in Turkish population: a MDCT study

AUTHORS: B sra PİRİN ,Zeliha FAZLIOGULLARI,Mustafa KOPLAY,Ahmet Kagan

KARABULUT,Nadire  NVER DOGAN

PAGES: 590-600

ORIGINAL PDF URL: <https://dergipark.org.tr/tr/download/article-file/2681904>

## ORIGINAL ARTICLE

## Morphometric Analysis of Orbit in Turkish Population: a MDCT Study

## Türk Popülasyonunda Orbita'nın Morfometrik Analizi: MDBT Çalışması

<sup>1</sup>Busra Pirinc , <sup>1</sup>Zeliha Fazliogullari , <sup>2</sup>Mustafa Koplay , <sup>1</sup>Nadire Unver Dogan , <sup>1</sup>Ahmet Kagan Karabulut <sup>1</sup>Department of Anatomy, Faculty of Medicine, Selcuk University, 42131 Konya, Turkey<sup>2</sup>Department of Radiology, Faculty of Medicine, Selcuk University, 42131 Konya, Turkey

## Correspondence

Zeliha Fazliogullari, Department of Anatomy, Selcuk University Faculty of Medicine 42131, Konya, TURKEY

E-Mail: z\_topal@yahoo.com

## How to cite ?

Pirinc B. , Fazliogullari Z. , Koplay M. , Karabulut A. K. , Ünver Doğan N. Morphometric analysis of orbit in Turkish population: a MDCT study. Genel Tıp Dergisi. 2022; 32(5): 590-600

## ABSTRACT

**Objective:** The orbit is an important cavity containing vision-related formations and important neurovascular structures, and adjacent to various regions. This study aimed to evaluation, by multidetector computed tomography (MDCT) images, the morphometry of orbit by examining its changes according to gender and body side, and developments according to age, in Turkish population.**Materials and Methods:** A total of 200 individuals's (94 females, 106 males; 400 sides) MDCT images were evaluated. Images were examined according to the gender, body side, and the anatomical structures development.**Results:** The height, width and depth of the orbit were determined as 36.04±2.97 mm, 32.33±2.59 mm, 38.35±3.32 mm on the right side, 35.79±3.18 mm, 32.29±2.67 mm, 38.13±3.21 mm on the left side, respectively, in healthy subjects. The height and width of the orbit were found to be statistically significantly larger on both sides in men than in women (p<0.05).**Conclusion:** Comprehensive information about the orbit and associated apertures is quite important for clinicians working in this area, damage to these structures can cause serious complications. In addition, determining the morphometry of the orbit can be used as an important parameter for determining gender, age and race in forensic medicine.**Keywords:** Anatomy, morphometry, multislice computed tomography, orbit

## ÖZ

**Amaç:** Orbita bağlantı sağladıkları boşluklar, komşu olduğu bölgeler ve içerdiği yapılar sebebiyle oldukça önemli bir bölgedir. Çalışmamızda Türk popülasyonunun orbita morfometrisini, çok kesitli bilgisayarlı tomografi (ÇKB) görüntülerinde cinsiyete, vücut tarafına göre farklılıklarını, yaşa bağlı gelişimini değerlendirmeyi amaçladık.**Gereç ve Yöntem:** 94'ü erkek, 106'sı kadın olmak üzere toplam 200 bireyin (400 taraf) ÇKB görüntüleri üzerinde ölçümler yapıldı. Görüntüler cinsiyet, vücut tarafı ve anatomik yapıların gelişimlerine göre değerlendirildi.**Bulgular:** Sağlıklı bireylerde orbita yüksekliği, genişliği ve derinliği sırasıyla sağ tarafta ortalama 36,04±2,97 mm, 32,33±2,59 mm, 38,35±3,32 mm iken sol tarafta 35,79±3,18 mm, 32,29±2,67 mm, 38,13±3,21 mm olarak belirlendi. Orbita'nın yüksekliği ve genişliği her iki tarafta da erkeklerde kadınlardan istatistiksel olarak anlamlı derecede büyük olduğu tespit edildi (p<0,05).**Sonuç:** Orbita ve ilişkili açıklıklar hakkında kapsamlı bilgi, ilgili bölgede çalışan klinisyenler açısından oldukça önemlidir, bu yapıların zarar görmesi ciddi komplikasyonlara neden olabilir. Bununla birlikte, orbita'nın morfometrisi adli tıpta cinsiyet, yaş ve ırk tespiti için önemli bir parametre olarak kullanılabilir.**Anahtar Kelimeler:** Anatomi, morfometri, çok kesitli bilgisayarlı tomografi, orbita

## Introduction

The orbit is an important anatomical region containing the eye and related formations and extensions of the central nervous system, with connections to the nasal and paranasal sinuses (1). Intraorbital structures, thanks to the four walls of the orbit, are separated from the formations associated with the brain and face. These walls have their own characteristics and are connected to neighboring structures by openings that allow the passage of important structures such as nerves and blood vessels (2). Therefore, even single lesions of the orbit can cause multiple complication (3).

Various diseases and event, including trauma, infection, and tumors, can affect the orbit. Orbit plays an important role in surgical procedures, in particular orbital decompression, enucleation, exenteration, optic nerve decompression and vascular ligation (4). Therefore, the orbit is an important anatomical region where tissues and organs belonging to different specialties such as ophthalmology, otolaryngology

and neurosurgery are located. The surgical approach to the structures located in the orbit is difficult due to the fact that this region has a relatively small volume and the richness of neurovascular structures located in the region (5). Comprehensive anatomical information about the orbit is important for regional surgery (2). In addition, determining the morphometry of the orbit can be used as an important parameter for determining gender, age and race in forensic medicine. Accurate measurements of the orbital anthropometry are valuable for the purpose of designing protective equipment for the eye (6). Thus, we believe that the results of our study will contribute to the existing literature knowledge, the prevention of possible complications in surgical interventions, and shed light on possible new designs.

## Materials and Methods

Images were performed with a 256-slice MDCT scanner (Siemens Somatom Flash, Erlangen, Germany). Imaging

parameters were as follows: kV = 120; mA = 160; rotation time = 0.5 s; collimation =  $64 \times 0.625$ ; FOV = 220 mm. According to power analysis using the GPower 3.1.9.4. program, the sample size was detected in 200 cases (the effect size was 0.75, the reliability was 0.95, and the power was 0.95).

The images of 355 patients who underwent orbital or paranasal CT imaging for different complaints between 2013 - 2021 were evaluated. A total of 155 cases were not included (orbital fractures, pathology in orbital structures, tumors, patients who underwent orbital surgery, foreign body in the relevant region, and poor image quality). Images of a total of 200 individuals (400 sides, 94 male and 106 female), were evaluated. In these cases, prepubertal age was accepted as below 15 years old, postpubertal age was accepted as above 15 years old, and geriatric age limit was accepted as 60 years old (7,8). Taking into account these limits, the cases were evaluated in eight different groups as 0-9 years old, 10-14 years old, 15-19 years old, 20-29 years old, 30-39 years old, 40-49 years old, 50-59 years old, and over 60 years old. In axial and coronal images, height, width, depth, and lengths of the medial and lateral walls of the orbit were measured. Area of orbital apertura was calculated. Measurements were taken three times by the same person for both parties and averaged.

#### Height and width of the orbit

The height of the orbit was measured as the longest vertical distance between the midpoints of the supraorbital and infraorbital margins at the superficial level of the infraorbital foramen, in coronal section images (9,10) (Figure 1). In the same images, width of the orbit was measured as the longest horizontal distance between medial and lateral margins at the superficial level of the frontozygomatic suture (1, 9) (Figure 1).

#### Depth of the orbit

In order to determine the orbital depth, firstly, the level at which the optic nerve is monitored continuously was determined, in axial section images. In the section at this level, the line has been drawn from anterior corner of lateral wall of the orbit to anterior lacrimal crest. And from this line to midpoint of the optic canal descending perpendicularly another line was determined as depth of the orbit (1) (Figure 2).

#### Lengths of the medial and lateral walls of the orbit

The medial and lateral wall lengths of the orbit were evaluated on axial section images at the level where the optic nerve was monitored continuously and the superior orbital fissure was observed. The medial wall length was measured as distance between the anterior lacrimal crest and the anteromedial point of the optic canal (1, 4, 10, 11) (Figure 3A). The lateral wall length was measured as distance between the anterior corner this wall and the anterolateral margin

of the superior orbital fissure (10-12) (Figure 3B).

#### Area of orbital apertura

The area of orbital apertura was calculated by using the software for both sides by following certain anatomical points on the edges of the orbit on coronal section images. This anatomic landmarks are supraorbital foramen, the anterior edge of floor of lacrimal fossa, frontozygomatic suture, lateral and infraorbital edges throughout ceiling of maxillary sinus, infraorbital foramen, junction point with this edge and medial margin. The area of the closed bone line drawn, provided that the medial edge passes through the bone line, is calculated automatically with the help of software (13, 14) (Figure 4).

#### Statistical Analyses

The SPSS for Windows version 24.0 program was used in the analysis, and the p-value less than 0.05 was considered statistically significant. The data conformity to the normal distribution was tested with the Shapiro Wilk test. Student's t-test (for normally distributed variables) and Mann-Whitney u test (for non-normally distributed variables) were used in the comparison of numerical variables in two groups. The Kruskal Wallis test and Dunn's multiple comparison test (for non-normally distributed variables) were used to compare numerical variables in more than two groups.

#### Results

In our study, data from 400 orbit of a total of 200 individuals, 94 male (47%) and 106 female (53%), were evaluated. Individuals aged between 3 months old and 90 years old were examined in eight different age groups. The distribution of age groups by gender was similar ( $p=0.344$ ). Morphometric measurements were made on the images and the reference values of these structures according to gender, side and age were determined in healthy individuals.

#### Height, width and depth of the orbit

The height and width of the orbit were found to be statistically significantly larger on both sides in males than in females ( $p<0.05$ ). Depth of the orbit was found to be statistically significantly greater in males than in females on the left side ( $p<0.05$ ), but it was not statistically significant right side ( $p>0.05$ ).

The height, width and depth of the orbit were found to be greater in the right side than in the left side, but this difference was not statistically significant ( $p>0.05$ ) (Table 1).

The height, width and depth of the orbit were compared according to age groups and a statistically significant difference was observed between the sides ( $p<0.05$ ). The largest height of orbit was 40-49 age group, while the widest orbit was observed in the 50-59 age group, for both sides. The largest depth of the orbit

**Table 1.** Orbital parameters according to body side and gender

	Height of the orbit (mm)		Width of the orbit (mm)		Depth of the orbit (mm)		Length of the medial wall (mm)		Length of the lateral wall (mm)		Area of orbital apertura (mm <sup>2</sup> )	
	Mean±SD		Mean±SD		Mean±SD		Mean±SD		Mean±SD		Mean±SD	
	Right	Left	Right	Left	Right	Left	Right	Left	Right	Left	Right	Left
Male (n=94)	36.96±2.19	36.64±2.52	32.97±2.34	32.87±2.32	38.71±2.66	38.85±2.68	38.54±2.65	38.68±2.47	42.72±3.27	42.7±3.22	1055.26±117.82	1048.57±104.01
Female (n=106)	35.22±3.33	35.03±3.51	31.76±2.68	31.77±2.85	38.03±3.8	37.48±3.5	37.58±3.2	37.72±3.26	40.94±3.58	41.31±3.05	994.74±144.17	991.14±143.99
p	0.001*	0.001*	0.001*	0.007*	0.281	0.014*	0.070	0.070	0.001*	0.001*	0.005*	0.004*
Total (n=200)	36.04±2.97	35.79±3.18	32.33±2.59	32.29±2.67	38.35±3.32	38.13±3.21	38.01±2.98	38.17±2.95	41.78±3.54	41.96±3.2	1023.18±135.54	1018.13±129.7
p	0.187		0.418		0.129		0.147		0.386		0.144	

\*Show statistical significance p&lt;0.05, SD: Standard Deviation

**Table 2** Orbital parameters according to age groups and body side

Age groups	Height of the orbit (mm)		Width of the orbit (mm)		Depth of the orbit (mm)		Length of the medial wall (mm)		Length of the lateral wall (mm)		Area of orbital apertura (mm <sup>2</sup> )	
	Right	Left	Right	Left	Right	Left	Right	Left	Right	Left	Right	Left
	Mean±SD	Mean±SD	Mean±SD	Mean±SD	Mean±SD	Mean±SD	Mean±SD	Mean±SD	Mean±SD	Mean±SD	Mean±SD	Mean±SD
0-9 (n=33)	32.68±3.5	32.44±3.46	29.05±2.72	29.48±3.08	36.22±3.74	35.79±3.68	36.01±3.39	36.3±3.76	38.22±4.54	38.92±3.8	839.53±129.57	845.87±128.39
10-14 (n=15)	34.17±2.64	34.35±2.12	30.82±1.92	30.45±2.18	37.46±3.17	37.63±3.09	38.23±2.42	37.93±2.93	41.17±3.44	40.98±2.43	932.86±97.66	950.67±92.79
15-19 (n=13)	36.54±2.2	36.06±3.44	32.94±3.2	32.61±2.48	38.39±4.47	38.13±4.23	38.73±3.5	39.59±3.84	42.21±2.76	42.76±2.84	1038.19±143.15	1020.59±136.05
20-29 (n=22)	36.03±1.61	35.6±1.82	32.48±1.84	32.49±1.88	37.9±2.18	38.13±1.76	38.55±3	38.35±2.5	42.87±2.99	42.78±2.83	1029.36±68.46	1014.36±65.04
30-39 (n=28)	36.49±2.11	36.04±2.26	33.25±1.84	33.18±2.1	39.37±2.28	39.03±2.65	38.58±2.98	38.45±2.51	42.62±2.94	42.74±3.19	1055.93±84.68	1071.01±89.95
40-49 (n=30)	37.81±2.54	37.63±3.19	33.02±1.49	32.85±1.92	39±3.68	38.57±2.96	37.85±2.71	38.25±2.44	42.45±2.96	42.59±2.85	1105.51±103.04	1081.28±117.92
50-59 (n=30)	37.37±2.17	37.05±2.9	33.66±1.82	33.76±2.33	39.22±2.77	38.74±1.84	37.96±2.09	38.26±1.91	43.15±2.27	42.59±2.15	1108.35±92.27	1094.76±85.53
60 years and over (n=29)	36.99±1.94	36.9±1.84	33.49±1.64	33.14±1.71	39.01±3.07	39.08±3.83	39.1±2.76	39.2±2.83	42.21±2.73	42.9±2.5	1062.57±74.96	1055.15±57.62
p	0.001*	0.001*	0.001*	0.001*	0.006*	0.005*	0.015*	0.041*	0.001*	0.001*	0.001*	0.001*

\*Show statistical significance p&lt;0.05, SD: Standard Deviation, Kruskal Wallis Test

**Table 3** Multiple comparison table of orbital parameters according to age groups

		0-9	10-14	15-19	20-29	30-39	40-49	50-59
Height of the orbit on right	0-9							
	10-14	0.350						
	15-19	0.001*	0.019*					
	20-29	0.001*	0.046*	0.524				
	30-39	0.001*	0.012*	0.785	0.644			
	40-49	0.001*	0.001*	0.240	0.029*	0.067		
	50-59	0.001*	0.001*	0.495	0.109	0.226	0.526	
	60 years and over	0.001*	0.001*	0.590	0.154	0.305	0.419	0.858
Height of the orbit on left	0-9							
	10-14	0.169						
	15-19	0.001*	0.103					
	20-29	0.001*	0.126	0.762				
	30-39	0.001*	0.052	0.993	0.702			
	40-49	0.001*	0.001*	0.063	0.010*	0.019*		
	50-59	0.001*	0.006*	0.450	0.204	0.345	0.156	
	60 years and over	0.001*	0.002*	0.246	0.081	0.147	0.377	0.601
Width of the orbit on right	0-9							
	10-14	0.147						
	15-19	0.001*	0.009*					
	20-29	0.001*	0.034*	0.419				
	30-39	0.001*	0.001*	0.895	0.251			
	40-49	0.001*	0.003*	0.864	0.421	0.700		
	50-59	0.001*	0.001*	0.527	0.079	0.529	0.302	
	60 years and over	0.001*	0.001*	0.670	0.133	0.712	0.444	0.795
Width of the orbit on left	0-9							
	10-14	0.465						
	15-19	0.001*	0.014*					
	20-29	0.001*	0.011*	0.825				
	30-39	0.001*	0.001*	0.540	0.321			
	40-49	0.001*	0.002*	0.920	0.693	0.512		
	50-59	0.001*	0.001*	0.271	0.115	0.543	0.198	
	60 yaş ve üzeri	0.001*	0.001*	0.540	0.319	0.996	0.511	0.537
Depth of the orbit on right	0-9							
	10-14	0.295						
	15-19	0.129	0.653					
	20-29	0.175	0.888	0.724				
	30-39	0.001*	0.065	0.211	0.056			
	40-49	0.003*	0.189	0.460	0.189	0.506		
	50-59	0.001*	0.119	0.332	0.112	0.709	0.766	
	60 years and over	0.002*	0.151	0.391	0.147	0.613	0.875	0.890
Depth of the orbit on left	0-9							
	10-14	0.060						
	15-19	0.044*	0.850					
	20-29	0.028*	0.957	0.879				
	30-39	0.001*	0.187	0.296	0.156			
	40-49	0.003*	0.594	0.770	0.592	0.335		
	50-59	0.001*	0.436	0.598	0.416	0.504	0.763	
	60 years and over	0.001*	0.390	0.545	0.367	0.575	0.688	0.918

Length of the medial wall on right	0-9							
	10-14	0.04*						
	15-19	0.006*	0.48					
	20-29	0.005*	0.68	0.71				
	30-39	0.002*	0.58	0.78	0.89			
	40-49	0.03*	0.77	0.28	0.41	0.31		
	50-59	0.03*	0.74	0.28	0.39	0.29	0.96	
	60 years and over	0.001*	0.43	0.95	0.69	0.77	0.19	0.17
Length of the medial wall on left	0-9							
	10-14	0.16						
	15-19	0.003*	0.15					
	20-29	0.04*	0.73	0.22				
	30-39	0.01*	0.59	0.27	0.84			
	40-49	0.09	0.98	0.1	0.66	0.5		
	50-59	0.06	0.9	0.13	0.78	0.6	0.87	
	60 years and over	0.001*	0.21	0.66	0.32	0.4	0.12	0.17
Length of the lateral wall on right	0-9							
	10-14	0.050						
	15-19	0.005*	0.410					
	20-29	0.001*	0.182	0.700				
	30-39	0.001*	0.152	0.664	0.969			
	40-49	0.001*	0.317	0.990	0.642	0.590		
	50-59	0.001*	0.052	0.361	0.549	0.549	0.247	
	60 years and over	0.001*	0.467	0.808	0.445	0.391	0.743	0.140
Length of the lateral wall on left	0-9							
	10-14	0.126						
	15-19	0.001*	0.091					
	20-29	0.001*	0.057	0.992				
	30-39	0.001*	0.055	0.938	0.936			
	40-49	0.001*	0.061	0.887	0.877	0.937		
	50-59	0.001*	0.096	0.732	0.695	0.740	0.797	
	60 years and over	0.001*	0.034*	0.914	0.889	0.815	0.750	0.566

**Table 4** A comparison of height and width of orbit among various studies (mm) (Mean±SD).

Height of the orbit		Width of the orbit							
Method	Right	Male		Female		Total		Male	
		Left	Right	Left	Right	Left	Right	Left	Right
Bones	Sangvichien et al. (2007) (20) (n=101) (age range: 18-86 year)	33.44±2.33		32.89±2.28				40.1±1.89	
	Nilek et al. (1) (2009) (n=100) (No age information)	3.36±0.27 cm	3.36±0.26 cm	3.36±0.29 cm	3.46±0.29 cm	3.35±0.28 cm	3.46±0.27 cm	42.6	41.6
	Rajangam et al. (2012) (9) (n=72) (No age information)	35±0.27	33.7±0.26	32±0.28	30.8±0.21			41.7±0.21	36.9±0.16
	Kumar and Gnanagurudasan (2015) (n=50) (No age information)	31.56±2.36	31.28±2.34	32.86±2.66	30.16±2.06			41.44±2.08	40.04±2.10
Direct graphy	Ghorai et al. (2017) (16) (n=101) (age range: 20-50 year)	28.54±1.95	28.51±1.91	33.23±1.74	28.69±2.16			32.79±1.4	30.81±1.44
	Sinanoglu et al. (2016) (18) (n=182) (age mean: 32.6 year)	40.3±4.0	40.3±4.2	33.5±2.5	34.3±2.7			37.3±3.1	29.7±2.2
CT	Weaver et al. (2010) (6) (n=39) (age mean: 45.1 year)	32.44±1.89		31.75±2.51				32.44±1.89	
	Kaya et al. (2014) (17) (n=112) (age range: 13-86 year)	33.9±2.27	34.5±2.20	32.6±2.40	33.16±2.19	33.3±0.22	33.8±0.21	37.04±1.79	35.78±1.50
	Ozer et al. (2016) (24) (n=198) (age range: 5-74 year)	37.7	37.77	36.55	36.97			33.99	33.27
	Altia et al. (2018) (13) (n=92) (128 section) (age range: 18-65 year)	37.3±3.2	36.9±2.9	35.9±2.8	35.9±2.8			37.2±4.7	37±3.6
MDCT	Acar et al. (2019) (14) (n=100) (128 section) (age range: 18-90 year)	36.2±1.8		35.0±1.3		35.9±1.7		39.4±2.1	38.5±1.6
	El-Farouny et al. (2021) (19) (n=89) (128 section) (age range: 20-70 year)	34.92±5.01	35.18±1.73	35.08±3.26	34.77±3.25			36.79±1.34	37.39±1.77
MDCT	Present study (n=200) (256 section) (age range: 3 month-90 year)	36.96±2.19	36.64±2.52	35.22±3.33	35.03±3.51			32.97±2.34	31.77±2.85

CT: Computerized tomography, MDCT: Multidetector computerized tomography

**Table 5** A comparison of lengths of the medial and lateral walls of orbit among various studies (mm) (Mean±SD).

		Length of the medial wall				Length of the lateral wall							
Metod	Right	Male		Female		Total		Male		Female		Total	
		Left	Right	Left	Right	Right	Left	Right	Left	Right	Left	Right	Left
Bones		Karakas et al. (2002) (12)											
		(age range: 30–50 year)											
		41.7±3.1											
		37.7±3.6											
Bones		Thanasil Huanmanop et al. (2007) (4)											
		42.3±3.1											
		41.8±2.5											
		42.4±1.5											
		42.2±2.1											
Bones		Nilek et al. (2009) (1)											
		42.1											
		42.6											
		39.9											
		40											
Bones		Kumar and Gnanagurudasan (2015) (10) (No age information)											
		42.40±2.60											
		41.84±2.10											
		42.08±2.33											
		41.64±2.18											
CT		Oester Jr et al. (2012) (11) (Adult individual)											
		43.9±3.0											
		46.9±3.3											
		41.6±5.6											
		45.7±4.0											
MDCT		Nilek et al. (2015) (23) (Age mean: 56 year)											
		40.40±2.76											
		38.39±1.85											
		42.72±3.26											
		41.31±3.05											
MDCT		Present study (age range: 3 month–90 year)											
		38.5±2.65											
		38.68±2.47											
		42.7±3.22											
		40.94±3.58											



**Table 6** A comparison of area of orbital apertura among various studies (Mean±SD).

Method	Area of orbital apertura			
	Female		Male	
	Right	Left	Right	Left
<b>Bones</b>				
Nitek et al. (2009) (1)		10.83 cm <sup>2</sup>	11.19 cm <sup>2</sup>	11.39 cm <sup>2</sup>
Attia et al. (2018) (13)		97.8±10.2	97.7±10.8	103.8 ± 14.5
(128 section)		cm <sup>2</sup>	cm <sup>2</sup>	cm <sup>2</sup>
Acar et al. (2019) (14)		1205 ± 66 mm <sup>2</sup>		1258± 67 mm <sup>2</sup>
(128 section)				
<b>MDCT</b>				
El-Farouny et al. (2021) (19)		100.40±7.23		111.964± 11.44
(128 section)		cm <sup>2</sup>	99.57± 6.14 cm <sup>2</sup>	109.67±11.47 cm <sup>2</sup>
Present				
study		994.74 ± 144.17 mm <sup>2</sup>	991.14 ± 143.99 mm <sup>2</sup>	1055.26 ± 117.82 mm <sup>2</sup>
(256 section)				1048.57 ± 104.01 mm <sup>2</sup>

MDCT: Multidetector computerized tomography

was 30-39 age group in right side, 60 age and over in left side. The narrowest height, width and depth of the orbit were observed in the 0 – 9 age group (Table 2).

When the height and width of the orbit were evaluated according to age groups for both sides, it was observed that there was a statistically significant difference between the mean values between the 0-9 age range and the 10-14 age range and all other age groups ( $p<0.05$ ). This result showed that the development of these structures continued until the age of 15-19 years on both sides, and reached the adult size from the age of 15-19 years (Table 3).

The difference between the mean values 0-9 age range years, except to 10-14, 15-19, 20-29 age range, all other age groups was found to be statistically significant. ( $p<0.05$ ). In left side, depth of the orbit were evaluated according to age groups for both sides, it was observed that there was a statistically significant difference between the mean values between the 0-9 age range and the 10-14 age range and all other age groups ( $p<0.05$ ) (Table 3). This result showed that the development of depth of the orbit continued until the age of 30-39 years, and reached the adult size from the age range, in right side. In contrast to in left, development of depth of the orbit continued until the age of 15-19 years, and reached the adult size from this age range (Table 3).

#### Medial and Lateral Wall Lengths of Orbit

There was no statistically significant difference in the length of the medial wall of the orbit by gender for both sides ( $p>0.05$ ). On the other hand, the length of the lateral wall was found to be statistically significantly larger on both sides in male than in female ( $p<0.05$ ) (Table 1).

The medial and lateral wall lengths were found to be

greater in left side than in right side, but this difference was not statistically significant ( $p>0.05$ ). The medial and lateral wall mean lengths are given in Table 1 separately for each groups.

The medial and lateral wall mean lengths were compared according to age groups and a statistically significant difference was observed ( $p<0.05$ ). The longest medial wall of the orbit were found to be 60 years old and over on the right side, 15-19 year group on the left side, and the longest lateral wall was observed to be 50-59 year group on the right side and 60 years old and over on the left side. The shortest lengths for these parameters were observed in the 0 – 9 age group for both sides (Table 3).

When the lateral wall was evaluated according to age groups for both sides, it was observed that there was a statistically significant difference between the mean values between the 0-9 age range and the 10-14 age range and all other age groups ( $p<0.05$ ). This result showed that the development of these structure continued until the age of 15-19 years on both sides, and reached the adult size from the age of 15-19 years (Table 3).

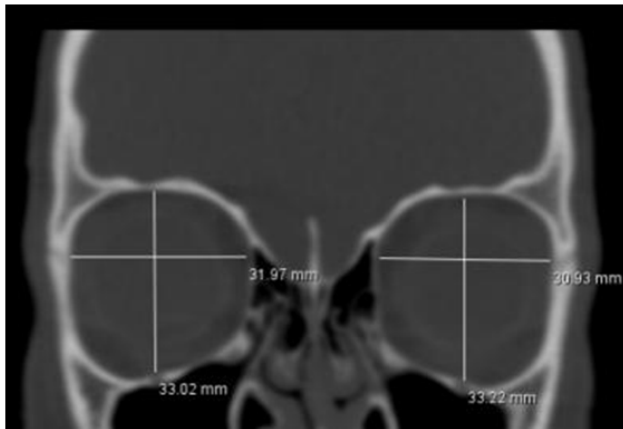
#### Area of orbital apertura

The area of the orbital aperture was found to be statistically significantly larger in males than in females, on both sides ( $p<0.05$ ) (Table 1).

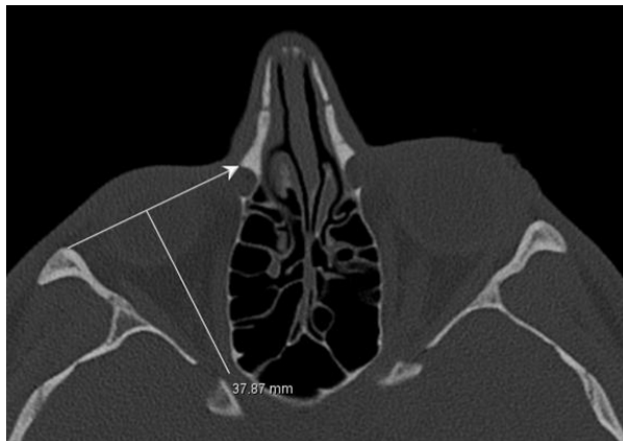
The means area of the orbital aperture were larger in right sides than in left sides, but this difference was not statistically significant ( $p>0.05$ ). The means areas of the orbital aperture are given in Table 1 separately for each groups.

When the areas of the orbital aperture was compared according to age groups, a significant difference was

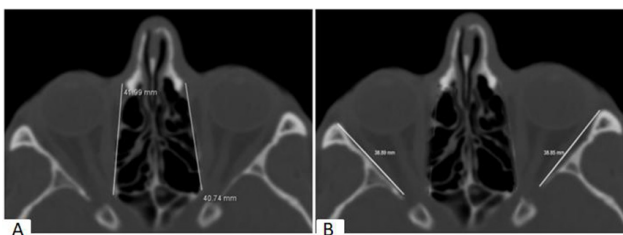
found for both sides ( $p<0.05$ ). On both sides, the age group with the largest area was 50-59 years, while the smallest area was 0-9 years (Table 3).



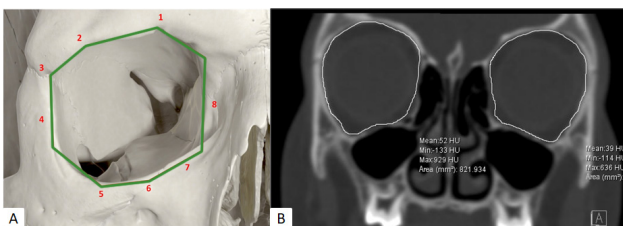
**Figure 1** Measurement of height and width of the orbit



**Figure 2** Measurement of depth of the orbit



**Figure 3** Measurement of medial (A) and lateral (B) wall lengths of orbit



**Figure 4** Measurement of area of orbital aperture (A: The supraorbital foramen (notch) on the supraorbital margin bone line (1), the anterior edge of the lacrimal fossa floor (2), the frontozygomatic suture (3), the lateral margin of orbit (4), the infraorbital margin (5), the level of

infraorbital foramen (6), the point of junction of the infraorbital margin and the medial margin (7) and the medial margin bone line (8), B: Coronal section)

## Discussion

The detailed anatomy of the orbit is important because it concerns many pathologies and surgical approaches, including orbital trauma, thyroid orbitopathy, and chronic orbital hyperesthesia (15).

Orbital nerves and their accompanying structures have a high risk of injury during orbital surgery. For this reason, the anatomy of the region has been the subject of study for many years. In most of the studies, dry bones have been examined, and the study data obtained with the MDCT method, which is a newly developed technology, is quite limited. In addition, researchers have generally focused on examining the differences in gender and in right-left sides, and studies evaluating the changes according to age in detail are very limited in the available literature. In our study, the MDCT method was used to examine the morphometry of orbit, its differences according to gender and body side, and its changes and developments according to age.

The skeleton plays an important role in determining gender from the point of view of forensic medicine. Morphological features of various structures of the skull have been the subject of studies due to the fact that it has the potential to identify the individual (1). The orbit is a valuable structure for determining gender, as it has a structure that is relatively resistant to trauma (16).

The studies in which the height of the orbit is evaluated are summarized in Table 4. It has been reported from these studies that the height of the orbit is generally not affected by gender. As in the study of Kaya et al. (2014) (17), Sinanoglu et al. (2016) (18) and Acar et al. (2019) (14), it was observed that the orbital height was statistically higher in males than in females in our study ( $p<0.05$ ). This similarity suggests that the height of the orbit is influenced by race (These studies were conducted in the Turkish population.). In Nitek et al (2009)'s study (1), it was noted that this parameter varies depending on the body side and is significantly larger on the left side ( $p<0.05$ ). Similarly to previous studies (9, 10, 13, 16, 19), it was found in our study that the height of the orbit was not affected by the body side. In our study, while the orbital height was similar to CT studies (13, 14, 17, 19), it was found that it was larger than the results of dry bone and direct graphy studies. The difference in the results of the study may be different methods, race and age groups. In dry bone studies, the age range of Sangvichien et al. (2007) (20) was reported as 18-86 years, while other studies do not have age information. In the study conducted with direct radiography, the age range was reported as 20-50 years. Although the Turkish population was examined in the study of Sinanoglu et al. (2016) (18), the results of this study are larger than our results. The reason for this situation may be the evaluation of only

adult individuals (average age: 32.6) in the relevant study. Because according to our study results, the orbital height reaches adult dimensions between the ages of 15 and 19.

The studies in which the width of the orbit is evaluated with various methods are summarized in Table 4. As in some studies (10, 14, 16, 17, 18, 19), it was found in our study that man have a statistically significantly wider orbit than female ( $p<0.05$ ). Consistent with the dry bone (1, 9) and MDCT (13, 19) studies evaluating the orbital width according to the side, it was also found in our study that the width did not show a significant difference between the sides ( $p>0.05$ ). In our study, it was observed that the orbital width was generally smaller than the other studies in the table, which is because it was thought that the method used may be due to the age and race differences of the individuals. In addition, in the studies that provided age information from the studies in the table, it was seen that only adults were included in the study. In our study, individuals between the ages of 3 months and 90 were evaluated, and it was determined that the 0-9 age group had the narrowest orbit and the 50-59 age group had the widest orbit. In addition, the fact that the orbital width reaches adult sizes in the 15 - 19 age group according to our study explains and supports this situation.

Orbital depth was found to be unaffected by the body side in Nitek et al's (2009) (1) ( $n=100$ , male; right: 50.3 mm, left: 50 mm; female; right: 46.8 mm, left: 47 mm) research and in our study ( $p>0.05$ ). In the study of Acar et al. (2019) (14) ( $n=100$ ), it was reported that this value is more in male ( $46.5\pm2$  mm) than in female ( $45.5\pm2.4$  mm). In our study, it was also found that the it was larger in male in left side ( $p<0.05$ ), while the right side was not affected by gender ( $p>0.05$ ).

The orbit is an important region due to its close relationship with the paranasal sinuses and the neurovascular formations passing through the openings in its structure (21). The anatomy of the medial orbital wall is important for the successful results of some orbital procedures such as ethmoidal vessel ligation, medial wall fractures, orbital decompression, ethmoid sinus exenteration, and transethmoidal sphenoidotomy. Damage to this structure may result in herniation of the orbital fat tissue into the ethmoidal sinus with careless dissection, complicating vision during surgery and resulting in enophthalmos after surgery (22). An important anatomical point on this wall is the anterior lacrimal crest (12). The studies in which the distance between the anterior lacrimal crest and the anteromedial of the optic canal is evaluated are summarized in Table 5. In accordance with the study of Thanasil Huanmanop et al. (2007) (4), it was also observed in our study that this distance was not affected in terms of gender and side ( $p>0.05$ ). In the study of Kumar and Gnanagurudasan (2015) (10), it was reported that this distance was not affected by the body side difference, but it was longer in male than in female. Similarly, in the study of Nitek et al. (2009) (1),

the medial wall was found to be longer in male than in female, while in the study of Nitek et al. (2015) (23) it was stated that this distance was longer on the right than on the left ( $p<0.05$ ). In the study of Oester Jr et al (2012) (11), it was evaluated in healthy individuals and individuals with vision loss, and it was reported that there was no significant difference between the two groups ( $p>0.05$ ).

The lateral wall of the orbit is an important site for lateral orbitotomy and excision of the lacrimal gland. The reference point in this area is the superior orbital fissure, through which important neurovascular structures pass (12). Anterolateral edge of the superior orbital fissure and front corner of this wall with the distance between has been investigated in some studies and these studies are also summarized in Table 5. In the study of Kumar and Gnanagurudasan (2015) (10), it was reported that this distance is significantly longer on the right side than on the left. In our study, no difference was found in terms of the body side where it was located ( $p>0.05$ ). In addition, in our study, it was found that the lateral wall is longer in male than in female, on both sides ( $p<0.05$ ). In the study of Oester Jr et al (2012) (11), healthy and visually impaired individuals were evaluated and it was reported that there was no significant difference ( $p>0.05$ ).

The studies in which the area of orbital apertura is evaluated with various methods are summarized in Table 6. As in some studies (13, 14, 19), it was found in our study that male have a statistically significantly larger area of orbital apertura than female ( $p<0.05$ ). In the study of Nitek et al. (2009) (1), it was reported that the area of orbital apertura mainly depends on the body side and is statistically significantly larger on the left side. In contrast to this result, in the study of Acar et al. (2019) (14), it was found that the area of orbital apertura was not affected in terms of the body side. Similarly, the area averages in our study are not affected by the side where they are located ( $p>0.05$ ).

## Conclusion

The orbit is an important cavity containing vision-related formations and important neurovascular structures, and adjacent to various regions. Due to the varying sizes of this complex region among individuals, it has been studied by anatomists and clinicians for many years. Our study shows that the orbit is a dynamic structure, its dimensions continues to change with growth and development during youth and with the effect of aging throughout adulthood. In the available literature, studies have usually been conducted with adult individuals, and very few studies have evaluated only the young population. In our study, both pediatric and adult individuals were examined in 8 different age groups by accepting that prepubertal age limit is before 15, postpubertal age limit is after 15 and geriatric age limit is 60 (7, 8). The development of height, width and lateral wall of the orbit continued until the age of 15-19 years, and reached the adult size from this age range. This result shows that the development of the

orbit is influenced by the pubertal period. In addition, the effect of gender and the side where it is located on the orbital dimensions was investigated. The height, width, area, lateral wall of the orbit were found to be statistically significantly larger in male than in female ( $p < 0.05$ ). In all the orbital parameters evaluated, it was found that the structure was not affected by the side in which it was located ( $p > 0.05$ ).

In this study presents reference ranges for the morphometry of orbits that maintain structural integrity and are intact in Turkish population, and evaluates them separately according to gender, body side and developmental age. Due to the neurovascular structures contained in this structure, there is a restriction for surgical procedures, as well as the fact that their size changes during growth increases the importance of this region. In addition, our study provides data that proves the evaluability of the orbit for gender determination, so we think that it will contribute to the existing literature for forensic medicine.

**Ethical approval:** All procedures performed in this study involving human participants were in accordance with the ethical standards of the institutional and/or national research committee and with the 1964 Helsinki declaration and its later amendments or comparable ethical standards. Ethical approval (approval number 2020/01) was given by the Local Ethics Committee of the Medical Faculty. This single-center retrospective study was approved by the local institutional review board with a waiver of the requirement for written, informed consent. This study was conducted at Selcuk University Faculty of Medicine.

**Declaration of Interests:** The authors declare that they do not have any conflict of interest.

**Funding:** This research did not receive any specific grant from funding agencies in the public, commercial, or not-for-profit sectors.

## References

- Nitek S, Wysocki J, Reymond J, Piasecki K. Correlations between selected parameters of the human skull and orbit. *Med Sci Monit*. 2009; 15 (12): 370-7.
- Cheng AC, Lucas PW, Yuen HK, Lam DS, So K-F. Surgical anatomy of the Chinese orbit. *Ophthalmic Plastic Reconstr Surg*. 2008; 24 (2): 136-41.
- Servat JJ, Black EH, Nesi FA, Gladstone GJ, Calvano CJ. Smith and Nesi's *Ophthalmic Plastic and Reconstructive Surgery*. Springer International Publishing; 2020. p. 3-65.
- Thanasil Huanmanop M, Sithiporn Agthong M, Vilai Chentanez M. Surgical anatomy of fissures and foramina in the orbits of Thai adults. *J Med Assoc Thai*. 2007; 90 (11): 2383-91.
- Hayek G, Mercier P, Fournier H. Anatomy of the orbit and its surgical approach. *Adv Tech Stand Neurosurg*. 2006; 35-71.
- Weaver AA, Loftis KL, Tan JC, Duma SM, Stitzel JD. CT based three-dimensional measurement of orbit and eye anthropometry. *Invest Ophthalmol Vis Sci*. 2010; 51 (10): 4892-7.
- Alkofide EA. The shape and size of the sella turcica in skeletal Class I, Class II, and Class III Saudi subjects. *Eur J Orthod*. 2007; 29 (5): 457-63.
- Chauhan P, Kalra S, Mongia SM, Ali S, Anurag A. Morphometric analysis of sella turcica in North Indian population: a radiological study. *Int J Res Med Sci*. 2014; 2 (2): 521-6.
- Rajangam S, Kulkarni R, Quadri L, Sreenivasulu S. Orbital dimensions. *Indian J Anat*. 2012; 1: 5-9.
- Kumar SS, Gnanagurudasan E. Morphometry of bony orbit related to gender in dry adult skulls of South Indian population. *Int J Health Sci Res*. 2015; 5: 207-14.
- Oester Jr AE, Sahu P, Fowler B, Fleming JC. Radiographic predictors of visual outcome in orbital compartment syndrome. *Ophthalmic Plast Reconstr Surg*. 2012; 28 (1): 7-10.
- Karakas P, Bozkir M, Oguz O. Morphometric measurements from various reference points in the orbit of male Caucasians. *Surg Radiol Anat*. 2002; 24 (6): 358-62.
- Attia AM, Ghoneim M, Elkhamary SM. Sex discrimination from orbital aperture dimensions using computed tomography: Sample of Egyptian population. *Journal of Forensic Radiology and Imaging*. 2018; 14: 32-8.
- Acar G, Buyukmumcu M, Guler I. Computed tomography based analysis of the lamina papyracea variations and morphology of the orbit concerning endoscopic surgical approaches. *Braz J Otorhinolaryngol*. 2019; 85 (5): 551-9.
- Leong SC, Karkos PD, MacEwen CJ, White PS. A systematic review of outcomes following surgical decompression for dysthyroid orbitopathy. *The Laryngoscope*. 2009; 119 (6): 1106-15.
- Ghorai L, Asha M, Lekshmy J, Rajarathnam BN, Kumar HM. Orbital aperture morphometry in Indian population: A digital radiographic study. *Journal of Forensic Dental Sciences*. 2017; 9 (2): 61.
- Kaya A, Uygur S, Eraslan C, Akar GC, Kocak A, Aktas E, Govsa F. Sex estimation: 3D CTA-scan based on orbital measurements in Turkish population. *Rom J Leg Med*. 2014; 22 (4): 257-62.
- Sinanoglu A, Orhan K, Kursun S, Inceoglu B, Oztas B. Evaluation of optic canal and surrounding structures using cone beam computed tomography: considerations for maxillofacial surgery. *J Craniofac Surg*. 2016; 27 (5): 1327-30.
- El-Farouny RH, Hassanien SA, Azab RM. Morphometric Evaluation Of Piriform And Orbital Aperture In Sex Discrimination By Using Computed Tomography In Egyptian Population. *Egypt J Forensic Sci Appl Toxicol*. 2021; 21 (1): 1-12.
- Sangvichien S, Boonkaew K, Chuncharunee A, Komoltri C, Piyawinitwong S, Wongsawut A, Namwongsa S. Sex determination in Thai skulls by using craniometry: multiple logistic regression analysis. *Siriraj Med J*. 2007; 59 (5): 216-21.
- Aziz SR, Marchena JM, Puran A. Anatomic characteristics of the infraorbital foramen: a cadaver study. *J Oral Maxillofac Surg*. 2000; 58 (9): 992-6.
- Akdemir G, Tekdemir I, Altin L. Transethmoidal approach to the optic canal: surgical and radiological microanatomy. *Surg Neurol*. 2004; 62 (3): 268-74.
- Nitek S, Bakoń L, Sharifi M, Rysz M, Chmielik LP, Sadowska-Krawczyńska I. Morphometry of the orbit in East-European population based on three-dimensional CT reconstruction. *Advances in Anatomy*. 2015; 1-10.
- Ozer MO, Oz II, Serifoglu I, Buyukuyul MC, Barut C. Evaluation of Eyeball and Orbit in Relation to Gender and Age. *J Craniofac Surg*. 2016; 27 (8): e793-e800.