

PAPER DETAILS

TITLE: Non-Invasive Assessment of Liver Fibrosis Using Diffusion-Weighted MRI

AUTHORS: Mehmet Hakan Piçak,Ahande Yardimci

PAGES: 465-471

ORIGINAL PDF URL: <https://dergipark.org.tr/tr/download/article-file/3736597>

ORIGINAL ARTICLE

Non-Invasive Assessment of Liver Fibrosis Using Diffusion-Weighted MRI

Difüzyon Ağırlıklı MR Kullanarak Karaciğer Fibrozisinin Non-Invaziv Değerlendirilmesi

¹Mehmet Hakan Pıçak , ²Aytül Hande Yardımcı 

¹Çiğli Eğitim ve Araştırma Hastanesi
²Sağlık Bilimleri Üniversitesi, İstanbul
Başakşehir Çam Ve Sakura Şehir Sağlık
Uygulama Ve Araştırma Merkezi

Correspondence

Mehmet Hakan Pıçak, Çiğli Eğitim ve
Araştırma Hastanesi

E-Mail: hakanbicak@gmail.com

How to cite ?

Pıçak MH, Yardımcı A. Non-Invasive
Assessment of Liver Fibrosis Using
Diffusion-Weighted MRI. Genel Tıp Derg.
2024;34(4):465-71.

ABSTRACT

Objective: In this study, we aimed to evaluate the stage of liver fibrosis in patients with chronic hepatitis and cirrhosis due to HBV and HCV, with DWI-MRI instead of the liver biopsy, and to investigate whether ADC values can practically replace histological fibrosis staging.

Material and methods: Forty-six patients diagnosed with chronic hepatitis who underwent biopsy with the Ishak fibrosis scoring system and 11 cases who were evaluated as normal according to radiological and clinical findings were included in the study. The ADC value of liver fibrosis patients and healthy controls was compared. The correlation of ADC value and liver fibrosis staging was analyzed. It was shown that ADC values decreased as the fibrosis stage increased.

Results: Very high statistical significance was found between the mean liver ADC values ($p < 0.001$). A high level of statistical significance was found between the normalized liver ADC values ($0.001 \leq p < 0.01$).

Conclusion: DWI images have been among the routine sequences in many imaging centers, are being used extensively, and give good results in the staging of fibrosis. With further studies we can access to standardized values which can lead to more efficient results.

Keywords: Liver fibrosis, ADC, Diffusion MRI, Fibrosis

ÖZ

Amaç: Bu çalışmada, HBV ve HCV'ye bağlı kronik hepatit ve sirozlu hastalarda karaciğer fibrozisinin evrelerini karaciğer biyopsisi yerine DAG-MR ile değerlendirmeyi ve ADC değerlerinin histolojik fibrozis evrelemesinin yerine kullanılabilirliğini araştırmayı amaçladık.

Metod: Biyopsi ile Ishak fibrozis skorlama sistemi uygulanmış kronik hepatit tanılı 46 hasta ile radyolojik ve klinik bulgulara göre normal olarak değerlendirilen 11 olgu çalışmaya dahil edildi.

Bulgular: Karaciğer fibrozisi olan hastaların ve sağlıklı kontrol grubunun ADC değerleri karşılaştırıldı. ADC değeri ile karaciğer fibrozis evreleri arasındaki korelasyon analiz edildi. ADC değerlerinin fibrozis evresi arttıkça azaldığı gösterildi. Ortalama karaciğer ADC değerleri arasında çok yüksek düzeyde istatistiksel olarak anlamlı fark bulundu ($p < 0.001$). Normalize edilmiş karaciğer ADC değerleri arasında yüksek düzeyde istatistiksel olarak anlamlı fark bulundu ($0.001 \leq p < 0.01$).

Sonuç: DWI görüntülemesi, birçok görüntüleme merkezinde rutin sekanslar arasında yer almakta, yaygın bir şekilde kullanılmakta ve fibrozis evrelemesinde iyi sonuçlar vermektedir. İleri çalışmalar ile standartlaştırılmış değerlere ulaşılabilir ve daha etkin sonuçlara ulaşmak mümkün olabilir.

Anahtar Kelimeler: Karaciğer fibrozis, Difüzyon Ağırlıklı MRG, ADC

Introduction

Fibrosis is the term used to define the over-accumulation of connective tissue in parenchymal organs. Liver fibrosis is an indicator of progressive liver disease. All of the causes causing liver injury also lead to fibrosis through inflammation and necrosis of the liver. Fibrosis, which is reversible in acute cases, can advance to portal hypertension and cirrhosis, with the course of complications of liver dysfunction and the formation of regeneration nodules and fibrous bands in the chronic injury process. Factors leading to liver fibrosis include viral hepatitis (B, C, D), metabolic causes (e.g., hemochromatosis, alpha-1 antitrypsin deficiency, Wilson disease, galactosemia, tyrosinemia, and Type IV glycogen storage disease), hepatic venous obstruction, toxins and drugs (e.g., alcohol, amiodarone, and methotrexate), primary biliary cirrhosis, nonalcoholic steatohepatitis (NASH), autoimmune hepatitis, helminthes (schistosomiasis) and cryptogenic cirrhosis (1,2).

The fibrosis evaluation is based on whether the liver biopsy specimen is stained with collagen stains. There are several scoring systems in use, such as the histologic activity index (HAI) (3) and the Ishak score (4), which evaluate the degree of inflammation and fibrosis in liver tissue. The Ishak system uses a scale from 0 to 6 to grade the severity of fibrosis, in which 0 indicates no fibrosis and 6 indicates cirrhosis. The evaluation of fibrosis stage in cases with chronic hepatitis related to hepatitis B virus and hepatitis C virus is important regarding the determination of the prognosis and the planning of treatment. Early-stage hepatic fibrosis can be reversed with specific therapeutic agents or the removal of the cause (e.g., alcohol and hepatitis) (5-7). The gold standard for the diagnosis and staging of hepatic fibrosis is biopsy. However, biopsy is an invasive procedure that can cause pain with a rate of 40%, and major complications with a rate of 0.5% (8). In addition,

biopsy has been found to be associated with significant sampling error (9). Therefore, a reliable, simple, and noninvasive method is required to evaluate hepatic fibrosis.

ADC (Apparent Diffusion Coefficient) values are a type of quantitative measurement obtained from diffusion-weighted magnetic resonance imaging (DW-MRI). These values reflect the degree of water diffusion in tissues, which can be affected the microstructure of tissues including the presence of fibrosis (10).

Fibrosis is a process of excessive accumulation of extracellular matrix components such as collagen in tissues. In general, fibrosis leads to a decrease in the mobility of water molecules, which results in a reduction of ADC values. This means that tissues with higher degree of fibrosis tend to show lower ADC values on DW-MRI (11).

Therefore, ADC values can be used as a potential biomarker to assess the degree of fibrosis in various tissues, including the liver, kidney, and lung. By analyzing ADC values in conjunction with other imaging or clinical parameters, radiologists and clinicians can evaluate the severity of fibrosis, monitor disease progression, and guide treatment decisions.

In our study, we aimed to evaluate the fibrosis level noninvasively using diffusion-weighted magnetic resonance imaging (DW-MRI) instead of the gold-standard biopsy and to investigate the usability of ADC values in place of the histologic evaluation of fibrosis. The hypothesis of the paper is that DW-MRI can be a reliable, simple, and non-invasive method for the evaluation of hepatic fibrosis, and that ADC values can practically replace histological fibrosis staging.

Material and Methods

The Institutional Ethics Committee of İstanbul Education and Research Hospital approved this study Year 2017, number 1114, and informed consent was obtained from all participants. Our study included 46 cases of chronic hepatitis diagnosed between January 2014 and April 2015 at İstanbul Education and Research Hospital, who underwent liver biopsy with modified Knodell and Ishak fibrosis scoring and underwent abdominal MRI examination. Additionally, 11 cases with normal liver evaluations based on radiological and clinical-laboratory assessments of abdominal MRI for various reasons (5 hemangiomas, 4 liver cysts, and 2 adrenal masses) were also included in the study.

Liver ADC studies on all of the cases were carried out using a 1.5-Tesla MRI device with a superconductor (Signa HDxt; GE Medical Systems, Milwaukee, Wisconsin, ABD), with an 8-channel body helix. DW-MRI were obtained at b values of 0 and 400 s/mm². ADC maps were created at a separate workstation (Advantage Workstation 4.4-GE Medical Systems) using a software program. ADC values were measured on the ADC map using 80- to 100-mm² regions of interest (ROI) on four quadrants of the liver (anterior

and posterior segments in the right lobe, and medial and lateral segments on the left lobe), avoiding the focal lesions, vascular structures and artifact areas, and the mean value was calculated. Spleen ADC values were measured on slices at the same level (Figures 1 and 2). Normalized liver ADC (liver ADC/spleen ADC) values were calculated. Normalization is a technique used to reduce variability and improve the accuracy of ADC measurements. By comparing the liver ADC values to those of the spleen, it is possible to account for individual differences in patient physiology and imaging conditions that could affect the ADC measurements. This process involves calculating a ratio of the liver ADC to the spleen ADC, which provides a more standardized measure that can be more reliably compared across different patients and studies. (12)

Statistical Analysis

The Kruskal-Wallis test was performed to test the significance of the mean ADC values based on the fibrosis stage. Very high statistical significance was found between the mean liver ADC values ($p < 0.001$). A high level of statistical significance was detected between the normalized ADC values ($0.001 \leq p < 0.01$). There were no statistically significant differences between the splenic ADC values (Tables 3-4).

The relationship between Spearman correlation analysis and the quantitative variables was calculated in the statistical evaluation. A high level of statistical significance was found between the corrected ADC (mean liver ADC value/spleen ADC value) values together with fibrosis stages and HAI –Ishak scores ($0.001 \leq p < 0.01$). Very high statistical significance was detected between the mean liver ADC value and fibrosis stage ($p < 0.001$) (Table 5).

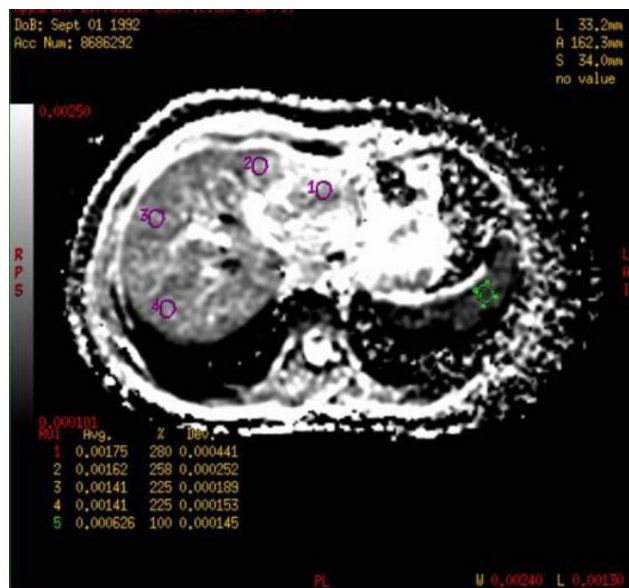
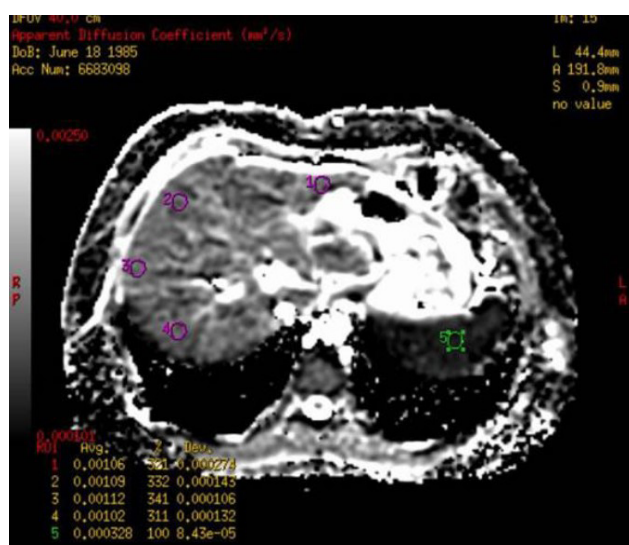
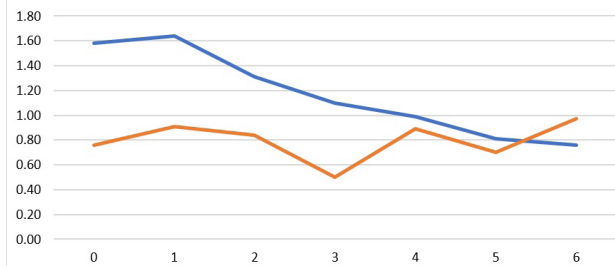
In the ROC analysis carried out between stages 0, 1 and 2 and stages 5 and 6 (cirrhosis), 100% specificity and sensitivity were calculated with a very high performance. The area under the curve (AUC) value was equal to 1. An unsuccessful performance was observed in the ROC analysis carried out in stage 0 (healthy subject) and stage 1 and 2 (onset of cirrhosis). The AUC value was 0.560. In the ROC analysis between stage 0 and stages 3 and 4, 100% specificity and sensitivity were calculated. The AUC was equal to 1. In the ROC analysis carried out between stages 1 and 2 and stages 3 and 4, 96% specificity and 92.3% sensitivity were calculated with a very high performance. The AUC value was equal to 0.988. In the ROC analysis carried out between stages 3 and 4 and stages 5 and 6, the specificity was calculated as 84.6%, and the sensitivity was calculated as 100% with very high performance. The AUC value was equal to 0.976. In the ROC analysis carried out between stages 4 and 6, the specificity was 85.7%, and the sensitivity was 100% with a very high performance. The AUC value was equal to 0.964. In the ROC analysis carried out between stage 5 and 6, 100% specificity and 50% sensitivity were calculated with poor performance. The AUC value was equal to 0.688.

Table 1: Distribution of the cases based on age and gender

	N	Minimum	Maximum	Mean	Std. Deviation
Age	57	26,00	80,00	49,96	13,65
Gender	n	%			
Man	31	54,4			
Woman	26	45,6			

Table 2: Measurements of the differences between the mean ADC values based on the fibrosis stage

	Mean liver ADC	Normalized Liver ADC	Mean Spleen ADC
Chi-Square	46,827	18,208	9,058
p	0,001	0,006	0,170

**Figure 1:** The ADC measurements made on the four quadrants of the liver and on the spleen in a 23-year-old man for whom the liver was evaluated as normal in radiological, clinical and laboratory studies, and fibrosis stage was determined as "0".**Figure 2:** The ADC measurements made on the four quadrants of the liver and on the spleen in a 30-year-old man with fibrosis stage determined to be "4".**Mean ADC values for fibrosis pathologically staged using the Ishaac classification system**
Liver ADC values(blue), Spleen ADC values**Figure 3:** Mean ADC values for fibrosis staged using Ishaac classification system.**Table 3:** ADC values based on fibrosis stage

Fibrosis	Mean liver ADC	Normalized Liver ADC	Mean Spleen ADC
N	11	11	11
Mean	0.00158	4.54481	0.00076
Standard Deviation	0.00032	6.71658	0.00039
Median	0.00152	1.96053	0.00076
Minimum	0.00126	1.27593	0.00011
Maximum	0.00245	22.43119	0.00135
N	16	16	16
Mean	0.00164	1.94473	0.00091
Standard Deviation	0.00032	0.66045	0.00027
Median	0.00158	1.76139	0.00092
Minimum	0.00129	1.06884	0.00052
Maximum	0.00269	3.25000	0.00138
N	9	9	9
Mean	0.00131	1.62906	0.00084
Standard Deviation	0.00012	0.38820	0.00018
Median	0.00132	1.71893	0.00085
Minimum	0.00110	1.20087	0.00051
Maximum	0.00145	2.33760	0.00110
N	6	6	6
Mean	0.00110	3.74474	0.00050
Standard Deviation	0.00008	3.98442	0.00027
Median	0.00108	2.19924	0.00052
Minimum	0.00102	1.34910	0.00011
Maximum	0.00124	11.67453	0.00078
N	7	7	7
Mean	0.00099	1.30522	0.00089
Standard Deviation	0.00009	0.68037	0.00030
Median	0.00103	1.12776	0.00095
Minimum	0.00084	0.67200	0.00033
Maximum	0.00107	2.75994	0.00125
N	4	4	4
Mean	0.00081	1.71545	0.00070
Standard Deviation	0.00008	1.40442	0.00039
Median	0.00079	1.16764	0.00075
Minimum	0.00074	0.76376	0.00020
Maximum	0.00090	3.76276	0.00109
N	4	4	4
Mean	0.00076	0.86047	0.00097
Standard Deviation	0.00012	0.35168	0.00030
Median	0.00075	0.89338	0.00090
Minimum	0.00065	0.47263	0.00073
Maximum	0.00090	1.18248	0.00137

Table 4: Spearman correlation analysis

Spearman's rho		HAI score	Fibrosis stage
Mean liver ADC	rs (ro)	-0.748	-0.850
	p	0.000	0.000
Normalized Liver ADC	rs (ro)	-0.349	-0.432
	p	0.008	0.001
Mean Spleen ADC	rs (ro)	-0.013	-0.017
	p	0.923	0.900

Table 5: Comparison of sensitivity, specificity, AUC and p values between different fibrosis stages

Fibrosis stages	AUC	P value	Sensitivity	Specificity
F0,1,2 to F5,6	1.000	<0.0001	100%	100%
F0 to F1,2	0.560	0.5680	56%	72.7%
F0 to F3,4	1.000	<0.0001	100%	100%
F1,2 to F3,4	0.988	<0.0001	92.3%	96%
F3,4 to F5,6	0.976	<0.0001	100%	84.6%
F4 to F6	0.964	<0.0001	100%	85.7%
F5 to F6	0.688	0.3993	50%	100%

Results

In total, 57 cases were included in our study. The ages of the cases ranged between 26 and 80 years, and the mean age was 50 years (std: 13.65) (Table 1). Thirty-one of the cases were men, and 26 were women.

Our study included 11 cases (19%) that were radiologically and clinically evaluated as normal, 16 cases (28%) with a pathology fibrosis score of stage 1, nine cases (16%) with stage 2, six cases (11%) with stage 3, seven cases (12%) with stage 4, and 4 cases each (7% each) in stages 5 and 6, respectively (as shown in Figure 3). We measured the ADC values for the liver (Dliver mean) and spleen (Dspleen), and calculated the normalized liver ADC (D dif) values. (Table 2).

The mean ADC values were calculated according to the fibrosis stage. The fibrosis stage was inversely proportional to the mean ADC values for the measurements made on the liver. It was determined that the ADC values decreased with the increasing fibrosis stage. No similar

ratio was found with a single measurement made in the liver; however, it was observed that

spleen ADC values tended to increase with increasing fibrosis levels (Figure 3).

Discussion

Liver fibrosis occurs through collagen accumulation in the extracellular matrix and chronic liver damage (13). Hepatic fibrosis was accepted previously as a passive and irreversible event because of the collapse in the hepatic parenchyma and replacement of the parenchyma with tissue rich in collagen (14, 15). We know that hepatic fibrosis is a dynamic event that can advance or regress within short periods of time such as a few months (16).

Hepatic fibrosis is related to inflammatory response and accumulation restricted in the matrix. The distribution

of the fibrous material depends on the cause of liver damage. The fibrotic tissue in chronic viral hepatitis and chronic cholestatic disease can be found around the portal paths at the beginning; however, it occurs in peri-central and peri-sinusoidal paths in alcoholic liver injuries (17).

Liver biopsy is accepted as the standard reference for evaluating hepatic fibrosis (18). However, a biopsy is an invasive procedure that causes pain with a rate of 40% and major complications with a rate of 0.5% (9). Furthermore, biopsies have been found to be related to sampling errors (9). Therefore, a reliable, simple and noninvasive method is required to evaluate hepatic fibrosis.

The no-contrast MR images taken in patients with liver fibrosis in the pre-cirrhotic stage and early-stage cirrhosis are often normal or are characterized by minimal changes and heterogeneity (19). Fibrous septa, bridging, and reticulations that produce low signals in T1AG and high signals in T2AG are observed in patients with advanced age cirrhosis (11).

In their study on mice, Yi-Ping Zhao et al. (19) reported decreases in the ADC value with increasing fibrosis stage ($r = -0.903$ and $P = 0$). A similar correlation was also observed in our study regarding the ADC values.

Lower than normal ADC values have been found in many studies (20-23). It is thought that while the decrease in water diffusion in hepatic fibrosis is multifactorial, the increase in the amount of collagen, in which the free water content is less than that in normal liver parenchyma, plays an important role (24,25).

Do et al. (25) achieved better results in their study when they normalized the liver ADC value with the splenic ADC value in the diagnosis of fibrosis and cirrhosis. In our study, a very high correlation was found in the mean liver ADC values ($P=0$); however, while the correlation between DWI and fibrosis was significant after normalization with the spleen, it was reduced ($P=0.006$). In their study, Bonekamp et al. (26) concluded that normalization with the spleen provided no diagnostic benefit. Prospective studies on larger patient groups are needed in this area.

Our study also observed a significant statistical correlation between the HAI score, showing the necro-inflammatory activity, and ADC values. We believe that this correlation is related to the increasing fibrosis level. Fujimoto et al. (27) reported significant differences between the inflammatory activity scores and mean ADC values in their study; however, since their aim was to use the ADC values in the staging of fibrosis or inflammation, they did not investigate the effects of inflammation on fibrosis. In another study, Bonekamp et al. claimed that (26), in their multiple-regression model, inflammation did not have a significant effect on the ADC values.

It is important to detect patients with fibrosis stage 3 or greater among patients with chronic viral hepatitis because the toxicity risk is high in these patients and antiviral therapy can be required; furthermore, the

effectiveness of treatment can be reduced with increasing fibrosis stage. (28)

Soylu et al. (29) concluded that, although the ADC values were smaller in cirrhotic patients, they were useless in HAI and fibrosis staging. In our study, however, the differentiation of healthy subjects and cases with stage 3 and 4 fibrosis (medium level) (AUC: 1.000, $p < 0.0001$) was possible with ROC analyses with 100% sensitivity and specificity. Likewise, the differentiation of early-stage fibrosis (F0, 1,2) and advanced-stage fibrosis (F5,6) (AUC:1.000, $p < 0.0001$) was possible with 100% sensitivity and specificity. The differentiation of early-stage fibrosis (F1, 2) and medium-level fibrosis (F3, 4) (AUC: 0.988, $p < 0.0001$) was possible with 92.3% sensitivity and 96% specificity. It was possible to differentiate medium-level fibrosis (F3, 4) from advanced-stage fibrosis (F5, 6) (AUC:0.976, $p < 0.0001$) with 100% sensitivity and 84.6% specificity.

Charatcharoenwithaya P et al. (30) reported that DWI, particularly with spleen-normalized ADC values, could serve as a non-invasive, accurate tool for diagnosing cirrhosis. The study also discusses the impact of necroinflammation and steatosis on ADC values and proposes a diagnostic algorithm incorporating DWI and the Fibrosis-4 index to reduce the need for liver biopsies potentially.

Pan Z et al's study (31) uses of fat- and iron-corrected Apparent Diffusion Coefficient (ADC) values to assess liver fibrosis in chronic hepatitis B patients. The study aimed to improve diagnostic accuracy by accounting for the effects of hepatic steatosis and iron deposition on ADC measurements. The results indicated that correcting ADC values for fat and iron content improved the diagnostic performance for identifying significant fibrosis and cirrhosis, suggesting that fat- and iron-corrected ADC could be a more reliable, non-invasive tool for liver fibrosis assessment.

Jang, W et al.'s study (32) presents a meta-analysis comparing the diagnostic performance of diffusion-weighted imaging (DWI) and magnetic resonance elastography (MRE) techniques, specifically gradient-recalled echo-based MRE (GRE-MRE) and spin-echo echo-planar imaging-based MRE (SE-EPI-MRE), in staging liver fibrosis. The study includes data from 60 studies involving 6620 patients. It concludes that both GRE-MRE and SE-EPI-MRE offer high diagnostic accuracy for liver fibrosis at all stages and could potentially replace liver biopsy. DWI, while showing moderate accuracy, is highlighted as a widely available and easily implemented alternative in routine liver MRI settings.

Jiang Y et al. (33) evaluate the clinical potential of a continuous-time random-walk diffusion model (CTRW) for staging liver fibrosis, comparing it with traditional diffusion-weighted imaging (DWI) and serum biomarkers. It involved 52 patients and used multi-b value DWI to derive various diffusion parameters. The findings demonstrate that the CTRW model, especially when combined with other parameters like ADC and LSM, can accurately stage liver fibrosis, offering a

reliable, non-invasive tool for liver fibrosis evaluation.

The b value determines the amplitude and period of the diffusion gradient and greatly affects the sensitivity for selective diffusion and the image quality (34-36). High b values must be used to increase the diffusion sensitivity and to decrease the perfusion effect in diffusion-weighted sequences (31). The selected b value will change the measured ADC value; lower ADC values are obtained with increasing b values. However, some studies have shown that average values such as $b=400$ are more advantageous in the calculation of ADC value for fibrosis staging (35). Only the $b=400$ value was used in our study, and this is one of the limitations of our study.

In particular, it was not possible to obtain significant results in the differentiation of healthy cases (F0) from cases with early-stage fibrosis (F1, 2) in several studies (20, 25). Similarly, in our study, the differentiation of healthy individuals (F0) from early-stage fibrosis (F1, 2) (AUC: 0.560, $p: 0.568$), and differentiation of incomplete cirrhosis (F5) from complete cirrhosis (F6) (AUC: 0.688, $p: 0.399$) was not possible.

However, there are several limitations to this study that must be considered. Firstly, the study only utilized one b value ($b=400$) in the DWI-MRI examination, which may have influenced the measured ADC values and the overall sensitivity of the findings. Secondly, the study did not compare DWI-MRI to other non-invasive methods for liver fibrosis staging, such as transient elastography or blood biomarkers, which could have provided a more comprehensive understanding of the relative strengths and weaknesses of DWI-MRI. Another possible limitation is the use of a single MRI device and software program for ADC measurements, which could introduce measurement bias and limit the generalizability of the results to other imaging platforms. Additionally, our study was limited by the inability to detect pathologic fibrosis stages in cases considered healthy based on clinical and laboratory results. Furthermore, the small number of cases in stage 5 and stage 6 fibrosis groups (4 in each) is another constraint of this study.

In the light of these limitations, future research should aim to conduct larger-scale studies with a more diverse patient population to validate the findings and enhance their generalizability. Researchers should also investigate the optimal b value for liver fibrosis staging, as well as compare the performance of DWI-MRI to other non-invasive methods. Furthermore, longitudinal studies should be conducted to evaluate the ability of DWI-MRI to predict disease progression, treatment response, and patient outcomes.

Conclusion

In this study, we demonstrated that diffusion-weighted MRI (DWI-MRI) is a highly effective non-invasive tool for staging liver fibrosis. Our findings show that liver ADC values decrease with increasing fibrosis stage. The statistical analyses confirmed a high level of

significance, underscoring the reliability of DWI-MRI in differentiating between various stages of liver fibrosis.

The practical implications of our findings are significant for clinicians, as DWI-MRI offers a safer, less invasive alternative to liver biopsy, reducing patient discomfort and risk of complications. For patients, this method means a more accessible and repeatable option for monitoring liver health, potentially leading to earlier detection and treatment of liver fibrosis. These benefits reinforce the value of our research in advancing liver disease management and improving patient outcomes.

Conflict of interest statement

The authors declare that they have no conflict of interest.

Ethics committee approval (place/date/number)

The Institutional Ethics Committee of Istanbul Education and Research Hospital approved this study Year 2017, number 1114, and informed consent was obtained from all participants.

Funding

This research received no specific grant from any funding agency in the public, commercial, or not-for-profit sectors.

Authorship Contribution Statement

Conception: M.H.P., A.H.Y., Design: M.H.P., A.H.Y., Supervision: M.H.P., A.H.Y., Data Collection and/or Processing: M.H.P., A.H.Y., Analysis and/or Interpretation: M.H.P., A.H.Y., Literature Review: M.H.P., A.H.Y., Writer: M.H.P., A.H.Y., Critical Review: M.H.P., A.H.Y.

References

- Friedman SL. Molecular regulation of hepatic fibrosis, an integrated cellular response to tissue injury. *Journal of Biological Chemistry*. 2000; 275(4):2247-2250.
- Friedman SL. Mechanisms of disease: mechanisms of hepatic fibrosis and therapeutic implications. *Nature clinical practice Gastroenterology & hepatology*. 2004;1(2):98-105.
- Knodel RG, Ishak KG, Black WC, et al. Formulation and application of a numerical scoring system for assessing histological activity in asymptomatic chronic active hepatitis. *Hepatology*. 1981;1(5):431-435.
- Ishak K. Histological grading and staging of chronic hepatitis. *J hepatol*. 1995;22:696-699.
- Dufour J-F, Delellis R, Kaplan MM. Regression of hepatic fibrosis in hepatitis C with long-term interferon treatment. *Digestive diseases and sciences*. 1998;43:2573-2576.
- Malekzadeh R, Mohamadnejad M, Nasser-Moghaddam S, et al. Reversibility of cirrhosis in autoimmune hepatitis. *The American journal of medicine*. 2004;117(2):125-129.
- Wanless IR, Nakashima E, Sherman M. Regression of human cirrhosis: morphologic features and the genesis of incomplete septal cirrhosis. *Archives of pathology & laboratory medicine*. 2000;124(11):1599-1607.
- Thampanitchawong P, Piratvisuth T. Liver biopsy: complications and risk factors. *World J Gastroenterol*. Aug 1999;5(4):301-304. doi:10.3748/wjg.v5.i4.301
- Regev A, Berho M, Jeffers LJ, et al. Sampling error and intraobserver variation in liver biopsy in patients with chronic HCV infection. *The American journal of gastroenterology*. 2002;97(10):2614-2618.
- Koh DM, Collins DJ. Diffusion-weighted MRI in the body: applications and challenges in oncology. *AJR Am J Roentgenol*. Jun 2007;188(6):1622-35. doi:10.2214/ajr.06.1403
- Taouli B, Tolia AJ, Losada M, et al. Diffusion-weighted MRI for quantification of liver fibrosis: preliminary experience. *American Journal of Roentgenology*. 2007;189(4):799-806.
- Papanikolaou N, Gourtsoyianni S, Yarmenitis S, et al. Comparison between two-point and four-point methods for quantification of apparent diffusion coefficient of normal liver parenchyma and focal lesions: value of normalization with spleen. *Eur J Radiol* 2010; 73:305-309
- Friedman SL. Hepatic fibrosis—overview. *Toxicology*. 2008;254(3):120-129.
- Popper H, Udenfriend S. Hepatic fibrosis: correlation of biochemical and morphologic investigations. *The American journal of medicine*. 1970;49(5):707-721.
- Schaffner F, Klion FM. Chronic hepatitis. *Annual Review of Medicine*. 1968;19(1):25-38.
- Soyer MT, Ceballos R, Aldrete JS. Reversibility of severe hepatic damage caused by jejunoileal bypass after re-establishment of normal intestinal continuity. *Surgery*. 1976;79(5):601-604.
- Pinzani M. Liver fibrosis. *Springer*; 2000:475-490.
- Afdhal NH, Nunes D. Evaluation of liver fibrosis: a concise review. *Official journal of the American College of Gastroenterology | ACG*. 2004; 99(6):1160-1174.
- Zhao Y-P, Guo D-M, Liu H, Liu W-H, et al. Apparent diffusion coefficient measurements and Gd-DTPA enhanced-imaging in staging hepatic fibrosis in rats. *International Journal of Clinical and Experimental Medicine*. 2015;8(2):2197.
- Taouli B, Chouli M, Martin AJ, et al. Chronic hepatitis: role of diffusion-weighted imaging and diffusion tensor imaging for the diagnosis of liver fibrosis and inflammation. *Journal of Magnetic Resonance Imaging: An Official Journal of the International Society for Magnetic Resonance in Medicine*. 2008;28(1):89-95.
- Koinuma M, Ohashi I, Hanafusa K, et al. Apparent diffusion coefficient measurements with diffusion-weighted magnetic resonance imaging for evaluation of hepatic fibrosis. *Journal of Magnetic Resonance Imaging: An Official Journal of the International Society for Magnetic Resonance in Medicine*. 2005;22(1):80-85.
- Girometti R, Furlan A, Bazzocchi M, et al. Diffusion-weighted MRI in evaluating liver fibrosis: a feasibility study in cirrhotic patients. *La radiologia medica*. 2007;112(3):394-408.
- Lewin M, Poujol-Robert A, Boëlle PY, et al. Diffusion-weighted magnetic resonance imaging for the assessment of fibrosis in chronic hepatitis C. *Hepatology*. 2007;46(3):658-665.
- Naganawa S, Kawai H, Fukatsu H, et al. Diffusion-weighted imaging of the liver: technical challenges and prospects for the future. *Magnetic Resonance in Medical Sciences*. 2005;4(4):175-186.
- Do RK, Chandanara H, Felker E, et al. Diagnosis of liver fibrosis and cirrhosis with diffusion-weighted imaging: value of normalized apparent diffusion coefficient using the spleen as reference organ. *American Journal of Roentgenology*. 2010;195(3):671-676.
- Bonekamp S, Torbenson MS, Kamel IR. Diffusion-weighted magnetic resonance imaging for the staging of liver fibrosis. *Journal of clinical gastroenterology*. 2011;45(10):885.
- Fujimoto K, Tonan T, Azuma S, et al. Evaluation of the mean and entropy of apparent diffusion coefficient values in chronic hepatitis C: correlation with pathologic fibrosis stage and inflammatory activity grade. *Radiology*. 2011; 258(3):739-748.
- Kim AI, Saab S. Treatment of hepatitis C. *The American journal of medicine*. 2005;118(8):808-815.
- Soylu A, Kilickesmez O, Poturoglu S, et al. Utility of diffusion-weighted

MRI for assessing liver fibrosis in patients with chronic active hepatitis. *Diagn Interv Radiol.* 2010;16(3):204-208.

30.Charatcharoenwithaya P, Sukonrut K, Korpraphong P, et al. (2021) Diffusion-weighted magnetic resonance imaging for the assessment of liver fibrosis in chronic viral hepatitis. *PLoS ONE* 16(3): e0248024.

31.Pan Z, Li Z, Meng F, Hu Y, et al. Fat- and iron-corrected ADC to assess liver fibrosis in patients with chronic hepatitis B. *Diagn Interv Radiol.* 2022;28(1):5-11.

32.Jang, W., Jo, S., Song, J.S. et al. Comparison of diffusion-weighted imaging and MR elastography in staging liver fibrosis: a meta-analysis. *Abdom Radiol* 46, 3889–3907 (2021)

33.Jiang Y, Fan F, Zhang P, et al. Staging liver fibrosis by a continuous-time random-walk diffusion model. *Magn Reson Imaging.* 2024 Jan;105:100-107.

34.Kim T, Murakami T, Takahashi S, Hori M, et al. Diffusion-weighted single-shot echoplanar MR imaging for liver disease. *AJR American journal of roentgenology.* 1999;173(2):393-398.

35.Girometti R, Furlan A, Esposito G, et al. Relevance of b-values in evaluating liver fibrosis: a study in healthy and cirrhotic subjects using two single-shot spin-echo echo-planar diffusion-weighted sequences. *Journal of Magnetic Resonance Imaging: An Official Journal of the International Society for Magnetic Resonance in Medicine.* 2008;28(2):411-419.

36.Zhou M-L, Yan F-H, Xu P-J, et al. Comparative study on clinical and pathological changes of liver fibrosis with diffusion-weighted imaging. *Zhonghua yi xue za zhi.* 2009; 89(25):1757-1761