

PAPER DETAILS

TITLE: Evaluation of Treatment Results in Orthopaedic Firearm Injuries: Review of 52 Cases

AUTHORS: Ahmet Atilla Abdioglu, Onur Varis, Oguzhan Aslan, Kemal Paksoy, Kerim Öner,
Hüseyin Uygun

PAGES: 764-771

ORIGINAL PDF URL: <https://dergipark.org.tr/tr/download/article-file/3689945>

ORIGINAL ARTICLE

Evaluation of Treatment Outcomes in Orthopaedic Firearm Injuries: A Review of 52 Cases

Ortopedik Ateşli Silah Yaralanmalarında Tedavi Sonuçlarının Değerlendirilmesi: 52 Olgunun İncelenmesi

¹Ahmet Atilla ABDİOĞLU^{ID}, ²Onur VARİŞ^{ID}, ³Oğuzhan ASLAN^{ID}, ⁴Kemal PAKSOY^{ID}, ⁵Kerim ÖNER^{ID}, ⁶Hüseyin UYGUN^{ID}¹Fatih State Hospital, Department of Orthopedics and Traumatology, Trabzon, Türkiye²Trabzon Kanuni Training and Research Hospital, Department Of Orthopedics and Traumatology, Türkiye³Karadeniz Technical University, School of Medicine, Department Of Orthopedics and Traumatology, Trabzon, Türkiye⁴Memorial Hospital, Department of Neurosurgery, İstanbul, Türkiye⁵Karadeniz Technical University, School of Medicine, Department Of Orthopedics and Traumatology, Trabzon, Türkiye⁶Trabzon Kanuni Training and Research Hospital, Department Of Orthopedics and Traumatology, Trabzon, Türkiye

Correspondence

Ahmet Atilla ABDİOĞLU
Fatih State Hospital, Department of Orthopedics and Traumatology, Trabzon, TürkiyeE-Mail: ahmetatilla@hotmail.com

How to cite ?

Abdioğlu AA, Varış O, Aslan O, Paksoy K, Öner K, Uygun H. Evaluation of Treatment Outcomes in Orthopaedic Firearm Injuries: A Review of 52 Cases. Genel Tıp Derg. 2024;34(6):764-771

ABSTRACT

Background/Aims: The prevalence of firearm-related fractures (FAF) among public has increased in many countries. The management of these injuries is challenging for physicians. The aim of this study was to evaluate the clinical outcomes of the patients treated for FAF.**Materials and Methods:** The study included adults treated in orthopaedic clinics for long bone shaft fractures of the extremities caused by civilian firearm injuries between 2015 and 2020. The medical records of the patients were retrospectively reviewed in this double-center study. Age, gender, fracture bone name, fracture type, treatment type, time to union, presence of permanent sequelae, presence of deep or superficial infection, presence of neurovascular injury, presence of mal-union and follow-up time were analysed.**Results:** This study was performed in 52 cases with a mean age of 43 years. Fifty patients were males, and two were females. 22 tibia, 20 femur, four humerus, four ulna, and two radius fractures were included. In total, 11 patients were treated with conservative method, 15 patients with plate-screw fixation, nine patients with intramedullary nails and 17 patients with external fixators. Permanent sequelae occurred in 13 (25%) patients following treatment. Seven (13.5%) infections were diagnosed during the treatment phase, and four (7.7%) were superficial and three (5.8%) were deep infections. In cases treated with external fixator, infection occurred in five (29.4%) patients, four of them were superficial infections. The mean follow-up period for all patients was 37.5 (25-60) months. While the mean time to union was 6.6 (1.5-15) months in all patients, this time was shorter with a mean of 2.5 months in patients treated with conservative treatment (p < 0.001).**Conclusion:** From admission to the emergency department to the finalisation of treatment, FAFs are challenging forensic cases for physicians. In addition to fractures, they may cause vascular, nerve and soft tissue injuries and may leave a high rate of sequelae. In addition to modern surgical techniques, conservative treatment is successfully used in appropriate cases.**Keywords:** Firearm-related fracture, orthopaedics, surgery

Öz

Amaç: Siviller arasında ateşli silah yaralanmaları (ASY) sebebiyle oluşan kırıkların yaygınlığı birçok ülkede artmıştır. Bu yaralanmaların yönetimi hekimler için zorlayıcıdır. Bu çalışmanın amacı, ASY nedeniyle ortopedi kliniğinde tedavi edilen hastaların sonuçlarını değerlendirmektir.**Gereç ve Yöntem:** Çalışmaya 2015-2020 yılları arasında, ekstremitelerin uzun kemiklerinde sivil ASY'ye bağlı shaft kırığı nedeniyle ortopedi kliniğinde tedavi edilen yetişkinler dahil edildi. İki merkezli çalışmada hastaların tıbbi kayıtları retrospektif olarak incelendi. Yaş, cinsiyet, kırık kemik adı, kırık tipi, tedavi tipi, kaynamaya kadar geçen süre, kalıcı sekel varlığı, yüzeysel veya derin doku enfeksiyon varlığı, nörovasküler yaralanma varlığı, malunion varlığı ve takip süresi analiz edildi.**Bulgular:** Bu çalışma yaş ortalaması 43 olan 52 olguda gerçekleştirildi. Elli hasta erkek, iki hasta kadındı. Çalışmaya 22 tibia, 20 femur, dört humerus, dört ulna ve iki radius kırığı dahil edildi. Toplam 11 hasta konservatif tedavi, 15 hasta plak-vida tespiti, dokuz hasta intramedüller çivi ve 17 hasta eksternal fiksatör ile tedavi edildi. Tedavi sonrası 13 (%25) hastada kalıcı sekel meydana geldi. Tedavi sırasında yedi (%13.5) enfeksiyon tanısı kondu; bunların dördü (%7.7) yüzeysel, üçü (%5.8) derin enfeksiyondü. Eksternal fiksatör ile tedavi edilen olgularda, dördü yüzeysel enfeksiyon olmak üzere beş (%29.4) hastada enfeksiyon ortaya çıkmıştır. Tüm hastalar ortalama takip süresi 37.5 (25-60) aydı. Kaynama süresi tüm hastalarda ortalama 6.6 (1.5-15) ay iken, konservatif tedavi ile tedavi edilen hastalarda bu süre ortalama 2.5 ay ile daha kısaydı (p < 0.001).**Sonuç:** Acil servise başvurudan tedavinin sonuçlanmasına kadar, ASY hekimler için zorlu adli vakalardır. Kırklara ek olarak damar, sinir ve yumuşak doku yaralanmalarına neden olabilirler ve yüksek oranda sekel bırakabilirler. Modern cerrahi tekniklerin yanı sıra uygun vakalarda konservatif tedavi de başarıyla uygulanmaktadır.**Anahtar Kelimeler:** Ateşli silah yaralanması, cerrahi, ortopedi

Introduction

The prevalence of firearm-associated fractures (FAFs) among civilians has increased in numerous nations, as a result of an increase in private armament (1-3). The degree of tissue damage caused by a bullet depends on numerous factors, including the type of bullet, its diameter, the kind of tissue affected, the angle of entry, and its course within the body (4-6).

Firearm-associated fractures primarily affect the spine, femur, tibia-fibula, hand and forearm bones, and can result in amputation or death (7). In addition, compartment syndrome, neurovascular damage, and soft tissue injury may result (4). The spectrum of soft tissue injuries induced by FAF ranges from a single bullet hole to extensive soft tissue defects (8,9). In addition, FAF is

associated with an increased likelihood of infection, since the bullet or its fragments create an opening through which bacteria from the skin flora, clothing, or other intermediate targets may enter the wound (4,10,11). Many of these factors make treatment of FAFs challenging (3,9,12). Although various methods have been described for fractures, the treatment of FAFs is still controversial (3,9,12-17). Therefore, the aim of this study was to evaluate the outcomes of patients treated in an orthopaedic clinic for FAFs.

Material and Method

This study was retrospective and bicentral. Ethics committee approval was obtained. The study was conducted in adult patients treated for long bone shaft fractures caused by FAFs in an orthopaedic clinic between 2015 and 2020.

The medical records of the patients were analysed. Patients with comprehensive evaluation data in their medical records and a follow-up period of at least two years were included in the study. The cases with complete information including age, gender, fractured bone, fracture type, treatment type, time to union, presence of permanent sequelae, presence of deep-superficial infection, presence of neurovascular injury, presence of mal-union, time to complete union and follow-up period were included in the study. Patients with less than two years of follow-up or missing evaluation criteria were excluded from the study. The study was conducted with 52 patients who fully met the criteria out of 67 patients treated in both clinics. Informed consent was obtained from the patients admitted for follow-up. Fractures healed with limb length discrepancy and deformity were considered as permanent sequelae (12). In anterior-posterior and lateral radiographs, union was determined by the presence of callus in three of the four cortices (13). The fractures were classified based on the Gustilo-Anderson classification (GAC) (8).

Sterile dressing was applied to the wounds in the emergency room. The wounds of patients that underwent fracture stabilization procedures were debrided (3,16). Bullets and gunshot fragments that were superficial or encountered during surgery were removed, but no extra investigation was undertaken to remove other bullets or fragments (4). Primary closure of wounds was not performed. Closed reduction and plaster cast was applied to the patients who were planned to be treated conservatively (CT). These patients were followed up with daily dressings

for the first week after debridement in the emergency department and intermittent dressings thereafter. Then weekly follow-ups were performed. Intramedullary nailing (IM), plate screw fixation (PS) or external fixation (EF) methods were used in the patients for whom operation had been planned. Before and after surgery, intravenous antibiotics were administered to all patients. Intravenous antibiotic treatment (first generation cephalosporin, gentamicin and metronidazole) was administered to all patients for at least five days from the first day. Antibiotic treatment was then regulated according to the culture results. In addition, vascular injuries were treated with dissection and end-to-end anastomosis in the same session. In case of nerve injury, the nerve was dissected and repaired, if necessary, in operated patients. In the mobilization of lower extremity fractures, patients treated with IM were allowed to bear weight as much as they could tolerate in the early postoperative period. In patients who received EF, PS and CT treatments, X-ray evaluations were made at the end of the 6th week and weight bearing was started as tolerated. Weekly or monthly follow-ups were performed after discharge.

Statistical Analysis

Categorical variables were expressed as numbers (%) and continuous variables were expressed as median (range). Conformity of continuous variables to normal distribution was evaluated with Kolmogorov-Smirnov and Shapiro-Wilk tests. Since the quantitative variables did not display normal distributions, more than two independent groups were compared using the Kruskal-Wallis test and two groups were compared using the Mann-Whitney U-test. The Chi-square test and Fisher Exact test were used, where appropriate, to compare the proportions in different groups. Pairwise comparisons of proportions were evaluated with the Bonferroni method in more than two groups. A p-value below 0.05 was considered as statistically significant. The Statistical Package for Social Sciences for Windows, version 26.0 (SPSS, IBM Corp., Armonk, N.Y., USA) was used to calculate the statistics.

Results

This study was performed in 52 cases with a mean age of 43 years. Fifty patients were males, and two were females. In total, 11 patients were treated with CT, 15 patients with PS, nine patients with IM surgery and 17 patients with EF.

There were 22 tibia, 20 femur, four humerus, four

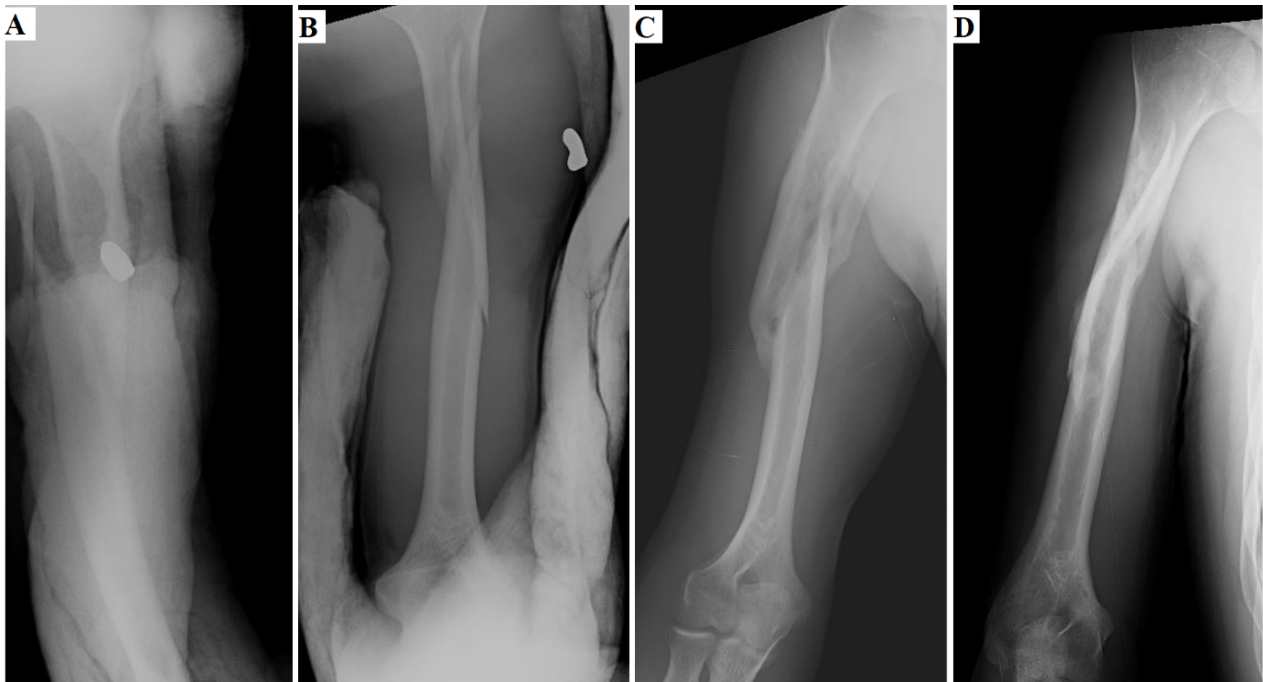


Figure 1. Fracture of the diaphysis of the humerus treated with conservative treatment (A,B: radiography images with splints, C,D: radiography images after union)

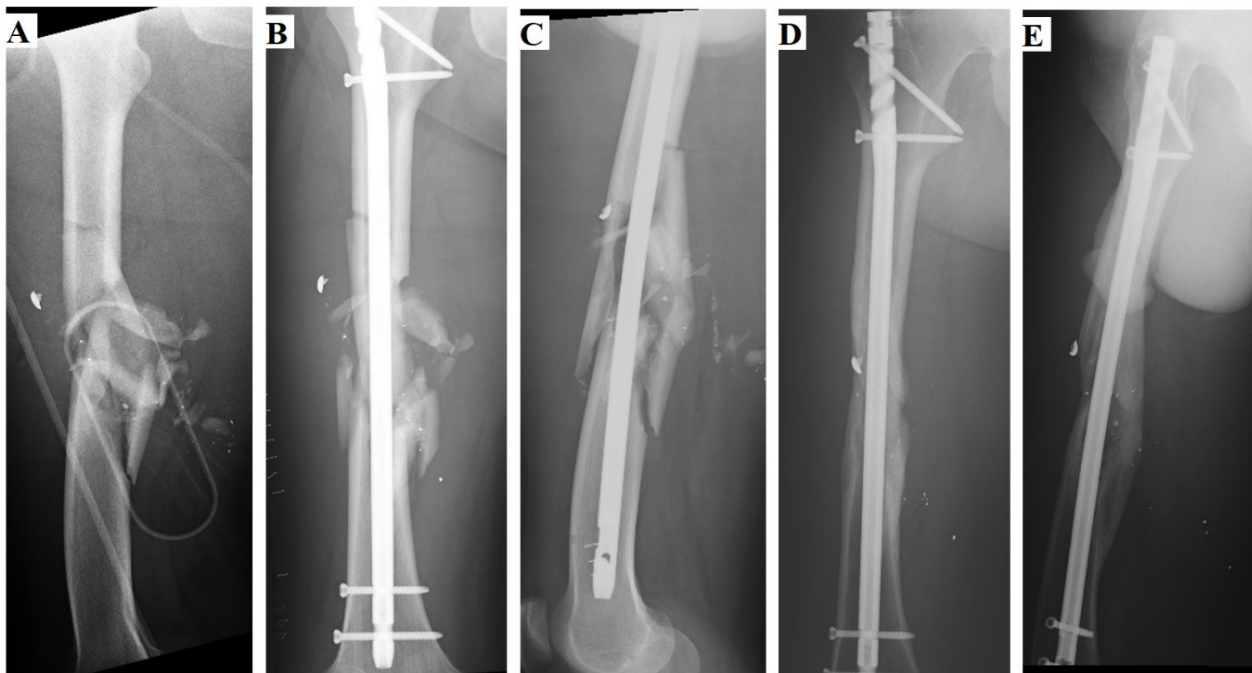


Figure 2. Internal fixation with intramedullary nail fixation in femoral diaphysis fracture (A: The first radiography image, B: Anterior-posterior radiography image after surgery, C: lateral radiography image after surgery, D: Anterior-posterior radiography image after union, E: Lateral radiography image after union)

ulna, and two radius fractures. Permanent sequelae occurred in 13 (25%) patients following treatment. The mean length of antibiotic use was 15 (5-45) days. Seven (13.5%) infections emerged during the treatment phase, and four (7.7%) were superficial, and three (5.8%) were deep infections. In cases treated with EF, infection occurred in five (29.4%) patients, four

of them being superficial infections.

Deep infection occurred in two patients (22.2%) treated with IM. Vascular injury was observed in three and nerve injury in eight patients. According to the GAC, fractures of 37 patients were classified as type 3A, 12 as type 3B, and three as type 3C open fractures.

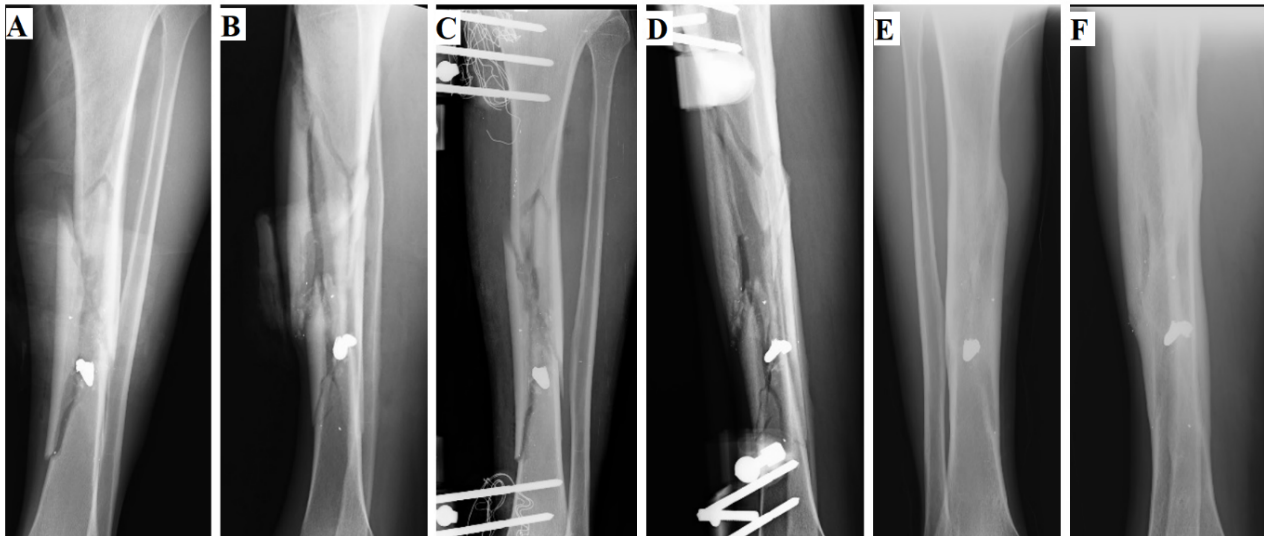

Figure 3. External fixation in tibia diaphysis fracture (A: The first anterior-posterior radiography image, B: The first lateral radiography image C: Anterior-posterior radiography image after surgery, D: Lateral radiography image after surgery , E: Anterior-posterior radiography image after union, F: Lateral radiography image after union)

Table 1 shows the overall characteristics of patients included in the study.

Table 1. General characteristics of patients included in the study.

Characteristic	n (%)
Age (Min-Max){years}	43 (15-73)
Gender	
Male	50 (96.2)
Female	2 (3.8)
Type of Treatment	
Conservative	11 (21.2)
Plate – Screw	15 (28.8)
Intramedullary	9 (17.3)
External Fixator	17 (32.7)
Fractured Bone	
Femur	20 (38.5)
Tibia	22 (42.3)
Humerus	4 (7.7)
Ulna	4 (7.7)
Radius	2 (3.8)
Gustilo-Anderson classification(%)	
3 A	37(71.2)
3 B	12(23)
3 C	3(5.8)
Additional Injury or Complication	
Deep Infection	3 (5.8)
Superficial Infection	4 (7.7)
Vascular Injury	3 (5.8)
Nerve Damage	8 (15.4)
Malunion	6 (11.5)
Sequela(shortness, osteomyelitis, limitation of movement and atrophy)	13 (25)

The mean follow-up period for all patients was 37.5 (25-60) months. While the mean time to union was 6.6 (1.5-15) months in all patients, this time was shorter with a mean of 2.5 months in patients treated with CT ($p<0.001$). Figure 4 shows the distribution of union time according to treatment type as a box plot.

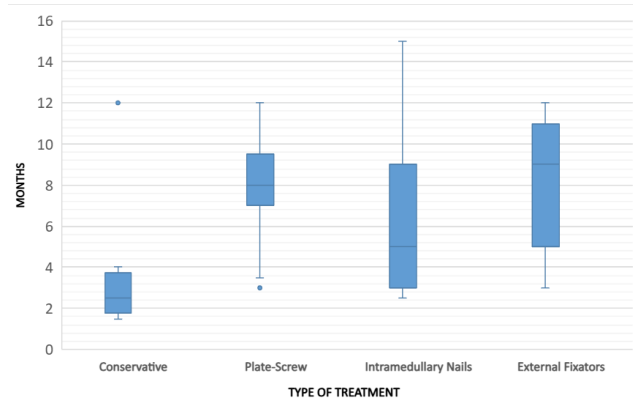


Figure 4. The distribution of union time and time to full function according to treatment type as represented in a box plot

When four treatment types were compared, no significant difference was found between the GAC fracture types. All patients undergoing CT were GAC type 3A fractures. One patient with vascular damage was treated with PS and two with EF, while one patient with nerve damage was treated with PS, four with IM and three with EF. No malunion was observed in any of the patients undergoing IM surgery. Four cases of malunion were observed in patients treated with EF. Table 2 shows the comparison of treatment types.

The distribution of permanent sequelae (shortness,

Table 2. Comparison of treatment types

	Conservative	Plate - Screw	Intramedullary	External Fixator	p
Age(Min-Max) (Years)	28 (15-62)	47 (23-73)	33 (23-47)	46 (32-56)	0.020
Fusion time (Min-Max) (Months)	2,5 (1.5-12)	8 (3-12)	5(2.5-15)	9(3-12)	0.001
Number of surgical procedures(Min-Max)	0	1 (1-3)	1 (1-3)	1 (1-4)	0.205
Gustilo-Anderson classification (%)					0.129
3 A	11(100)	11 (73.3)	5 (55.6)	10(58.8)	
3 B	0	3(20)	4(44.4)	5(29.4)	
3 C	0	1(6.7)	0	2(11.8)	
Sequela (%)	1 (9.1)	4 (26.7)	1 (11.1)	7 (41.2)	0.225
Infection(%)	0	0	2 (22.2)	5 (29.4)	0.026
Malunion(%)	1 (9.1)	1 (6.7)	0	4 (23.5)	0.408

osteomyelitis, limitation of movement and atrophy) according to the bones was seen in five (22.7%) tibia fractures, five (25%) femur fractures, one (25%) humerus fracture and two (50%) ulna fractures. Vascular injury was observed in 2(9.1%) of tibia fractures and 1(50%) of radius fractures. Nerve injury was observed in three (13.6%) tibia fractures, one (5%) femur fracture, two (50%) humerus fractures, one (25%) ulna fracture and one (50%) radius fracture. Deep infection developed in two (9.1%) tibia fractures and one (5%) femur fracture. Superficial infection developed in two (9.1%) tibia, one (25%) ulna and one (5%) femur fractures.

Discussion

Permanent sequelae were observed in 25% of the cases in our study, indicating the severity of FAFs injuries. In addition, the treatment of these fractures is difficult due to infection, vascular injury, nerve injury and soft tissue injury (9). There is limited data regarding the treatment of this injury (3,9).

The majority of patients in our study were men, with a rate of 96.2%. It is suggested that men are impacted by FAFs more than women because they have easier access to firearms and are more likely to engage in criminal activities (18,19). In several research, the mean age of FAFs was reported to be between 26.3 and 33.6 years; however, our study determined it to be 43 (13,18-22). The higher mean age compared to the literature may have caused a difference in the results of the study in terms of fracture union time or complications compared to the literature.

In our study, we observed that 80.8% of all long bone fractures in FAFs occurred in the lower extremities. In

a study of FAFs patients admitted to the emergency room, the lower extremities were reported as the most frequently injured location with a rate of 41.3% (18). A similar study reported the frequency of FAFs in upper extremity as 55.7% and the lower extremity was 43% (20). The femur has previously been reported as the most commonly fractured long bone in FAFs (7). In our study, tibia fractures were the most common (42.3%), while femoral fractures were the second most common (38.5%). We observed that these two bones had a relatively similar damage rate.

Superficial infection was observed in 7.7% of cases and deep infection in 5.8%. In a study evaluating FAFs, the rate of deep and superficial infections was reported as 5.7% and 15.1% respectively, and deep infection was not detected in patients treated non-operatively (22). Infection rates in IM procedures performed on FAFs have been found to be significantly variable in investigations, ranging from 0% to 2.5%, 26.1%, 28.2%, and 31% (21-24). In a trial where IM was performed on tibial FAFs, profound infection was observed in 6.5% and 17.4% of the groups with and without irrigation and debridement, respectively (21). In another trial comparing EF and IM treatment, there was no statistically significant difference between the two groups, but the infection rate in the IM group was reported as being 5.2% (9). A study evaluating the use of PS in the humeral fractures demonstrated that 1.6% of patients had deep infection (19).

In our study involving different bones in different extremities, it is not possible to make a definite judgement between treatment types. However, when the treatment groups were compared in general, no

significant difference was found between EF and IM groups in terms of infection. The infection rate was statistically higher in the IM and EF groups compared to the CT and PS groups ($p=0.026$). All superficial infections were observed in the EF group in our cases. The infection rates in our study are comparable to those reported in literature, despite the fact that the results are often highly variable. In the CT group, no GAC type 3B and 3C fractures were observed, while all were in class 3A. In addition, 73.3% of the PS group was type 3A, while 55.6% in the IM group and 58.8% in the EF group were type 3A. The incidence of type 3B and 3C fractures was found to be relatively higher in the IM and EF groups. This may help explain the higher infection rates in the IM and EF groups.

Despite the high probability of infection during FAFs treatment, there is no consensus on the usage of antibiotics (4,11). Although many physicians consider extensive debridement and complete removal of bullet from the body to be necessary, debridement and bullet excision can lead to additional complications (4,17). As suggested in literature, we only removed the fragments or bullet that were observed during surgery and no additional intervention was conducted for fragments located in deep tissues or that weren't visualized.

Several studies have assessed nonunion criterion (9,13,14,19). Since the predicted union time of each bone is different, we did not determine a specific nonunion time in our study involving multiple bones. In a study of femoral fractures after FAFs, union time was compared between the EF (mean 5.8 months) and IM (mean 3.1 months) groups and the authors found that the IM group required considerably less time to heal (mean union time: 5.8 and 3.1 months, respectively) (9). In the same study, no difference was observed between groups in terms of evaluation of union (9). In a study of femur fractures caused by high-speed FAFs treated with EF and delayed IM, the mean union time was determined to be 24 weeks (14). In our study, we observed a mean time of 8.59 months, which was longer than the time reported in literature. There was no significant difference when we compared treatment types. In our study, it was observed that CT can be successfully applied together with advanced surgical techniques in appropriate fracture cases. However, it should be kept in mind that patients treated with CT are selected from fractures with adequate fracture alignment and relatively less soft tissue damage. None of the patients treated with CT had major soft tissue

damage or neurovascular injury. This may explain why, in some respects, CT has fewer complications or more successful outcomes compared to surgical treatments. Additionally, it is known that there are many factors that affect fracture union positively or negatively (25-28).

Malunion rates after IM treatment of bone fractures caused by FAFs have been reported between 0% and 1.1% (15,29). In our study, this rate was found to be 11.5% in the general analysis of all treatment types. While malunion was not observed in patients treated with IM treatment, it was observed in 23.5% in EF treatment. Therefore, bone alignment follow-up should be performed well in EF treatment.

In FAFs, nerves may be damaged directly, indirectly, or through mechanisms related to transient cavitation (30,31). Direct injury is caused by direct contact between the object and a nerve. Indirect injury, on the other hand, is caused by compartment syndrome that results from the shock wave or transient cavitation generated by the object (30,31). The management of peripheral nerve damage in FAFs remains controversial (30). Of the treatment protocols, none have been established as the standard (32). In our study, nerves of patients who underwent open surgery were examined and, if necessary, repaired. In the event of a vascular damage, surgical intervention was conducted as a matter of urgency. Tokyay et al. reported the incidence of vascular and nerve injuries as 5.5% and 11.1%, respectively (33). In another study examining low-energy lower extremity FAFs cases, vascular injury and nerve injury were 6.1% and 1.4%, respectively (34). In a civilian upper extremity FAFs study, the rate of nerve injury in fractured patients was reported to be 43.1% (35). In our study, the rate of nerve injury was 15.4% and the rate of vascular injury was 5.8% in all extremities.

Limitations

The research is a retrospective and descriptive study. Since it included different clinics, the treatments were performed by different surgeons. Since the study included bone fractures in all extremities, no standardisation can be made for the results of treatment types. Due to the wide variety of treatment options, larger studies are needed to determine the ideal treatment of FAFs.

Conclusion

FAFs is an important injury with a 25% permanent

sequelae rate in the extremities. From admission to the emergency room to the conclusion of treatment, FAFs are challenging forensic cases for physicians. In addition to fractures, vascular and nerve injuries and soft tissue evaluation are important in the initial examination of patients. Treatment types are highly variable and far from standardized. CT, PS, IM, and EF therapies are effective in treating FAF-related long bone shaft fractures. In addition to modern surgical procedures, CT is still an important treatment option due to its shorter mean union time and low infection rate when conducted under the appropriate conditions.

References

1. Davies MJ, Wells C, Squires PA, et al. Civilian firearm injury and death in England and Wales. *Emerg Med J*. 2012;29(1):10–4.
2. Bäckman PB, Riddez L, Adamsson L, Wahlgren CM: Epidemiology of firearm injuries in a Scandinavian trauma center. *Eur J Trauma Emerg Surg*. 2020 Jun;46(3):641–647.
3. Muqango S, Kauta N, Held M, Mazibuko T, Keel MJB, Laubscher M, Ahmad SS: Gunshot injuries to the lower extremities: Issues, controversies and algorithm of management. *Injury*, Volume 51, Issue 7, July 2020, Pages 1426–1431.
4. Baum GR, Baum JT, Hayward D, MacKay BJ. Gunshot Wounds: Ballistics, Pathology, and Treatment Recommendations, with a Focus on Retained Bullets. *Orthopedic Research and Reviews* 2022;14 293–317.
5. Bartlett CS, Helfet DL, Hausman MR, Strauss E. Ballistics and gunshot wounds: effects on musculoskeletal tissues. *J Am Acad Orthop Surg*. 2000;8(1):21–36.
6. Stefanopoulos PK, Piniadis DE, Hadjigeorgiou GF, Filippakis KN. Wound ballistics 101: the mechanisms of soft tissue wounding by bullets. *Eur J Trauma Emerg Surg*. 2017;43(5):579–586.
7. Dougherty PJ, Vaidya R, Silverton CD, et al. Joint and long-bone gunshot injuries. *J Bone Joint Surg Am* 2009;91(4):980–97.
8. Gustilo RB, Anderson JT. Prevention of infection in the treatment of one thousand and twenty-five open fractures of long bones: retrospective and prospective analyses. *J Bone Joint Surg Am*. 1976;58:453–8.
9. Polat S, Balci S, Ergin OA, Esmâ A, Şen Ç, Kılıçoğlu Ö. A comparison of external fixation and locked intramedullary nailing in the treatment of femoral diaphysis fractures from gunshot injuries. *Eur J Trauma Emerg Surg* (2018) 44:451–455.
10. Grosse Perdekamp M, Kneubuehl BP, Serr A, Vennemann B, Pollak S. Gunshot-related transport of micro-organisms from the skin of the entrance region into the bullet path. *Int J Legal Med*. 2006;120(5):257–264.
11. Sathiyakumar V, Thakore RV, Stinner DJ, Obremskey WT, Ficke JR, Sethi MK. Gunshot-induced fractures of the extremities: a review of antibiotic and debridement practices. *Curr Rev Musculoskelet Med*. 2015;8(3):276–289.
12. Tejan J, Lindsey RW. Management of civilian gunshot injuries of the femur. A review of the literature. *Injury*. 1998;29(Suppl 1):SA18–22.
13. Dougherty PJ, Gherebeh P, Zekaj M, Sethi S, Oliphant B, Vaidya R. Retrograde Versus Antegrade Intramedullary Nailing of Gunshot Diaphyseal Femur Fractures. *Clin Orthop Relat Res*. 2013 Dec;471(12):3974–80.
14. Dar GN, Kangoo KA, Dar FA, Ahmed ŞT. External fixation followed by delayed interlocking intramedullary nailing in high velocity gunshot wounds of the femur. *Turkish Journal of Trauma & Emergency Surgery*. 2009;15(6):553–558
15. Cannada LK, Jones TR, Guerrero-Bejarano M, et al. Retrograde intramedullary nailing of femoral diaphyseal fractures caused by low-velocity gunshots. *Orthopedics*. 2009;32(3):162.
16. Franke A, Bieler D, Wilms A, et al. Treatment of gunshot fractures of the lower extremity: Part 1: incidence, importance, case numbers, pathophysiology, contamination, principles of emergency and first responder treatment. *Unfallchirurg*. 2014;117(11):975–6, 978–984.
17. Tosti R, Rehman S. Surgical management principles of gunshot-related fractures. *Orthop Clin North Am*. 2013;44(4):529–540.
18. Meral O, Sağlam C, Güllüpinar B, Aktürk ÖE, Beden S, Parlak İ: Investigation of firearm injury cases presented to training and research hospital's emergency service. *Ulus Travma Acil Cerrahi Derg*, January 2020, Vol. 26, No. 1
19. Cho E, Taylor A, Olson JJ, Entezari V, Vallier HA. Complications are infrequent after humeral shaft fractures due to low energy gunshot injuries. *J Orthop Trauma*. 2022 Sep 16.
20. Baumfeld D, Brito ASP, Torres MS, Prado KL, Andrade MAP, Campus TVO: Firearm-Related Fractures: Epidemiology and Infection Rate. *Rev Bras Ortop* 2020;55(5):625–628.
21. Donally CJ, Lawrie CM, Sheu JI, Gunder MA, Quinlan SM: Primary Intra-Medullary Nailing of Open Tibia Fractures Caused by Low-Velocity Gunshots: Does Operative Debridement Increase Infection Rates? *Surg Infect*. 2018 Apr;19(3):273–277.
22. Nguyen MP, Savakus JC, O'Donnel JA, Prayson NF, Reich MS, Golob JF Jr, McDonald AA, Como JJ, Vallier HA: Infection Rates and Treatment of Low-Velocity Extremity Gunshot Injuries. *J Orthop Trauma*. 2017 Jun;31(6):326–329.
23. Nowotarski P, Brumback RJ. Immediate interlocking nailing of fractures of the femur caused by low- to mid-velocity gunshots. *J Orthop Trauma*. 1994;8(2):134–41.
24. Mack AW, Freedman BA, Groth AT, et al. Treatment of open proximal femoral fractures sustained in combat. *J Bone*

Joint Surg Am. 2013;95(3):e13(1-8)

25. Giganti MG, Tresoldi I, Masuelli L, Modesti A, Grosso G, Liuni FM, et al. Fracture healing: from basic science to role of nutrition. *Front Biosci.* (2014) 19:1162-75.

26. Sheweita S, Khoshhal K. Calcium metabolism and oxidative stress in bone fractures: role of antioxidants. *Curr Drug Metab.* (2007) 8:519-25.

27. Lu LY, Loi F, Nathan K, Lin TH, Pajarinen J, Gibon E, et al. Pro-inflammatory M1 macrophages promote Osteogenesis by mesenchymal stem cells via the COX-2-prostaglandin E2 pathway. *J Orthopaed Res.* (2017) 35:2378-85.

28. The effect of quercetin on bone healing in an experimental rat model." *Joint Diseases and Related Surgery* 34.2 (2023): 365-373.

29. Nowotarski P, Brumback RJ. Immediate interlocking nailing of fractures of the femur caused by low- to mid-velocity gunshots. *J Orthop Trauma.* 1994;8(2):134-41.

30. Secer HI, Daneyemez M, Tehli O, Gonul E, Izci Y. The clinical, electrophysiological nerve injuries caused by gunshot wounds in adults: a 40-year experience. *Surg Neurol* 2008;69:143-52.

31. Oberlin C, Rantissi M. Gunshot injuries to the nerves. *Chir Main* 2011;30:176-82.

32. Topuz AK, Eroğlu A, Atabey C, Çetinkal A. Surgical treatment outcomes in peripheral nerve lesions due to gunshot injuries: assessment of 28 cases. *Ulus Travma Acil Cerrahi Derg* 2013;19 (3):235-240.

33. Tokyay A, Özkan S, Güven N, İsmailov U, Dikici A: First Intervention in Firearm Injuries and Management of Complications. *J Contemp Med* 2021;11(6):790-794

34. Abghari M, Monroy A, Schubl S, Davidovitch R, Egol K. Outcomes Following Low-Energy Civilian Gunshot Wound Trauma to the Lower Extremities: Results of a Standard Protocol at an Urban Trauma Center. *Iowa Orthop J.* 2015;35:65-69.

35. Engelmann EWM, Roche S, Maqungo S, Naude D, Held M. Treating fractures in upper limb gunshot injuries: the Cape Town experience. *Orthop Traumatol Surg Res* 2019;105(3):517-522.