

PAPER DETAILS

TITLE: Pneumoperitoneum Without Pneumothorax After Blunt Trauma

AUTHORS: Mesut YUR,Mehmet SIRIK,Cengiz Ömer ÖZDEMİR

PAGES: 255-258

ORIGINAL PDF URL: <https://dergipark.org.tr/tr/download/article-file/467735>



Pneumoperitoneum Without Pneumothorax After Blunt Trauma

Künt Travma Sonrası Pnömotorakssız Pnömooperitoneum

Mesut Yur¹, Mehmet Şirik², Cengiz Ömer Özdemir³

¹Atatürk Üniversitesi Tıp Fakültesi, Genel Cerrahi Anabilim Dalı, Erzurum; ²Adıyaman Üniversitesi Eğitim ve Araştırma Hastanesi, Radyoloji Anabilim Dalı; ³Nöroşirurji Anabilim Dalı, Adıyaman, Türkiye

ABSTRACT

Pneumoperitoneum usually indicates a surgical emergency because of visceral perforation in 85 to 95% of cases. Spontaneous pneumoperitoneum without any visceral perforation is a rare condition that surgeons faced with this problem. We reported a case of pneumoperitoneum with burst fracture of thoracic 12nd spine after a blunt trauma. A 27 years old man presented to emergency service after an industrial accident. His Glasgow coma score was 15 and in his abdominal examination, there was tenderness and muscular defense. Ct scan showed us free abdominal air anterior of the liver and burst fracture of thoracic 12nd spine. Firstly, laparotomy was performed but we couldn't observe any identifiable pathology for free air in abdomen. After closure of abdomen, instrumentation was performed for the spine. The patient was discharged on the 4nd postoperative day, but the cause of pneumoperitoneum remained obscure. After blunt trauma without pneumothorax, lonely pneumoperitoneum is a difficult problem for surgeons to operative or conservative treatment.

Key words: pneumoperitoneum; blunt trauma; acute abdomen

ÖZET

Pnömooperitoneum, %85–90 oranında visseral perforasyon olması nedeni ile acil cerrahiye gerektirir. Visseral perforasyonun olmadığı spontan pnömooperitoneum cerrahların karşılaştığı nadir bir durumdur. Bu çalışmada künt travma sonrası 12. torakal vertebrada çökme fraktürlü pnömooperitoneumu olan bir olgu sunuldu. Endüstriyel bir kaza sonrası acil servise getirilen 27 yaşında bir erkek hastada Glasgow koma skoru 15 idi ve karın fizik muayenesinde hassasiyet ve defans vardı. Bilgisayarlı tomografisi 12. torakal vertebrada çökme kırığı ve karaciğer anteriorunda serbest hava gösteriyordu. İlk olarak laparotomi yapıldı ancak karın içi serbest havayı açıklayacak bir patoloji bulunamadı. Karın kapatıldıktan sonra vertebra için enstrümantasyon yapıldı. Hasta postoperatif 4. gün taburcu edildi ama pnömooperitoneumun nedeni hala bilinmiyor. Pnömotorakssız olmadığı künt travma sonrası, yalnız pnömooperitoneum, cerrahi veya konservatif tedavi açısından cerrahlar için zor bir durumdur.

Anahtar kelimeler: pnömooperitoneum; künt travma; akut karın

Mesut Yur, Atatürk Üniversitesi Araştırma Hastanesi, Genel Cerrahi Kliniği
25030 Erzurum - Türkiye, Tel. 0505 818 10 91 Email. mesutyur@hotmail.com
Geliş Tarihi: 09.04.2016 • Kabul Tarihi: 23.01.2017

Introduction

Pneumoperitoneum (PP) denotes an abnormal collection of air in the peritoneal cavity. It results from a perforation of viscera in 90% of the cases and requires immediate surgical intervention¹. Spontaneous pneumoperitoneum (SPP) can be seen in literature^{2,3}. But, after blunt trauma, SPP is very rare. In some cases, we can see some PP reports with pneumothorax, pneumomediastinum or pneumocardia although PP has not seen without pneumothorax or with only spine injury¹⁻⁵.

Case Report

A 27 years old man presented our hospital (Adıyaman University Training and Research Hospital, Department of Emergency Service) 3 hours after a history of blunt trauma which falling down on his back from 2 meters height during his work. His vitals were normal (respiratory rate: 20/min, heart rate: 90/min and systolic blood pressure: 130 mm Hg). His coma score was 15 and neurologic examination was normal. His abdomen was distended with features of generalized peritonitis. Rectal examination was unremarkable. Blood tests are; White blood cell: 12000, Hematocrite: 40%, Hemoglobine: 13 mg/dl.

Urgent computed tomography (CT) performed and it showed us abdominal free air in abdomen (Figure 1, 2) and burst fracture of 12th spine (Figure 3). We didn't observe any other pathology. We decided to operate the patient and firstly laparotomy was performed. When we open the abdomen with midline incision, we didn't observe any perforation of viscera and diaphragm. The stomach and duodenum were fully mobilized, and lesser sac was explored, but no

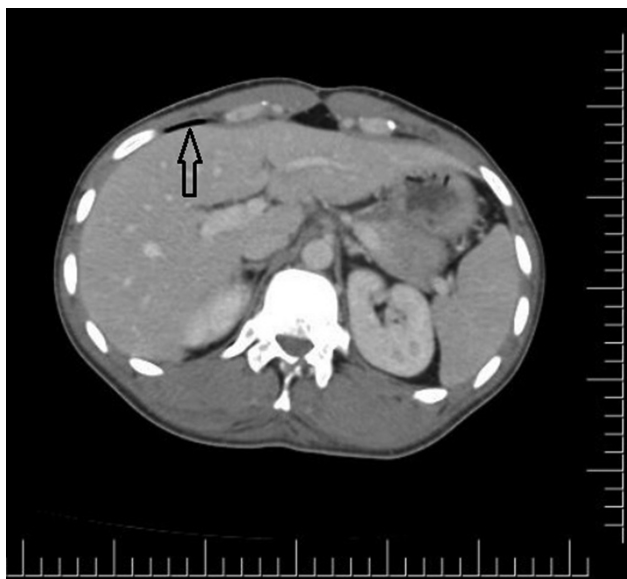


Figure 1. Transverse scan of CT showing (arrow shows the free air anterior of the liver).

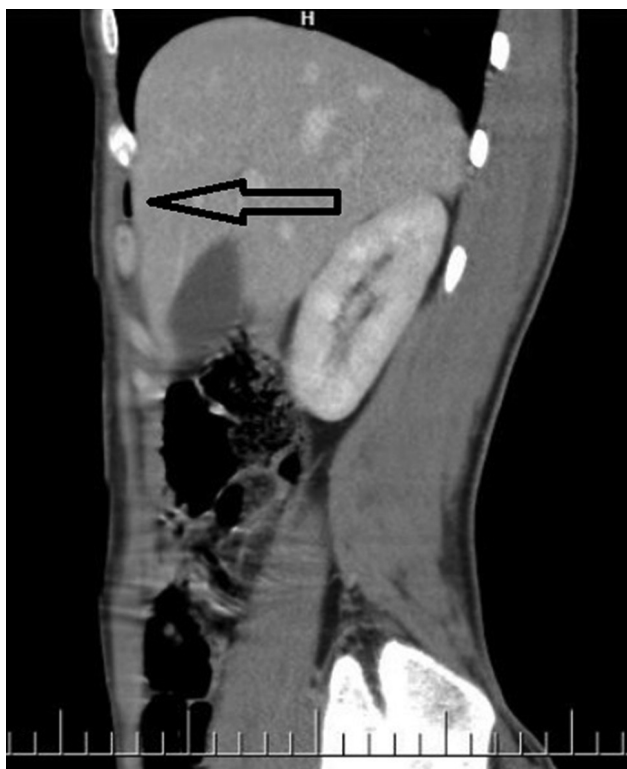

Figure 2. Sagittal scan of CT showing (arrow shows the free air anterior of the liver).

evidence of perforation was found in the distal esophagus, stomach and duodenum. The small bowel and colon also examined, but no leakage was observed and there was no evidence of pneumatosis cystoides intestinalis or other pathologies. Abdominal cavity

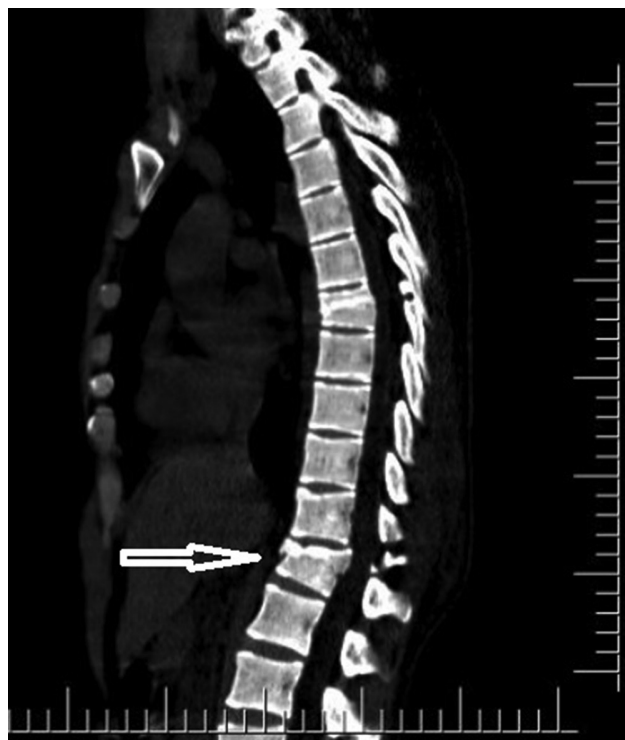


Figure 3. CT scan of vertebra (arrow shows the burst fracture of 12th spine).

filled with 2000 cc of normal saline and air was infused through the nasogastric tube into the stomach, but no air leakage was observed in upper gastrointestinal tract. Operation completed by placing a soft drain. After closure of abdomen, spine injury was repaired by specialist of neurosurgery.

The 4th postoperative day, patient discharged with oral nutrition without any complication.

Discussion

Pneumoperitoneum in trauma patients reliably indicates gastrointestinal perforation in 90% of cases and usually requires exploratory laparotomy¹. The other 10% of them are idiopathic or spontaneous. These cases are air leakage from pneumatosis cystoides intestinalis, a small perforated duodenal ulcer, a leak from colonic diverticulum, insufflation of air through the female genital tract, chronic obstructive pulmonary disease, cardiopulmonary resuscitation, mechanical ventilation, thoracic causes (such as barotraumas), pneumothorax and bronchoperitoneal fistulas.

Intermittent positive-pressure ventilation or thoracic causes (such as barotraumas) may lead to air being introduced into the abdominal cavity by direct passage

through diaphragmatic and microscopic pleural defects or through the mediastinum along the perivascular connective tissue, traveling retroperitoneally, and then rupturing into the peritoneal cavity.

No definitive explanation exists for the presence of PP in blunt trauma patients without concomitant pneumothorax. The speculation is that the free intraabdominal air in these patients may have resulted from intestinal micro perforations, which rapidly seal and leave behind no obvious clinical sequelae. This is akin to the well-described clinical entity of pneumatosis cystoides intestinalis, which is a rare cause of PP after blunt abdominal trauma⁶.

Pneumoperitoneum, after blunt trauma, can be seen due to many reasons described above. In cases after blunt trauma with pneumothorax-pneumomediastinum and pneumocardia, PP may be seen due to reasons not requiring surgery⁷⁻⁹. In most cases, PP has been seen with pneumothorax, pneumomediastinum or pneumocardia. In these cases, they did not find a surgical cause for pneumoperitoneum. Beside these reasons, PP can be seen spontaneously or with other reasons like insufflation of air through the female genital tract, chronic obstructive pulmonary disease, cardiopulmonary resuscitation, mechanical ventilation or others. But we can not see any PP case after blunt trauma like our case that not having pneumothorax, pneumomediastinum or pneumocardia and others causes.

In our case, the patient fell down on his back. PP was observed without pneumothorax and pneumomediastinum after blunt trauma. Furthermore, we didn't observe any other pathologies but for spine injury. So, trauma affected the spine firstly and abdomen affected indirectly. We couldn't say SPP for this patient. Because he was exposed to a blunt trauma.

Nishina et al. suggested non-operative approach in the setting of pneumoperitoneum if the following conditions are present; a thorough physical examination, no peritoneal signs, pneumothorax, negative diagnostic peritoneal lavage and gastrointestinal swallow series, no intraperitoneal effusion on ultrasonography or CT scan and close observation with repeated physical examinations and ultrasonography¹⁰. To rule out bowel leak, imaging with oral contrast may be needed. However, it may not be informative as the leak may be too small, it may have sealed, it may take long time to opacify the bowel, and the patient may be uncooperative.

Marek et al. evaluated 78 cases and concluded that CT scans may detect free air that is not always clinically significant. Of note, free fluid, seatbelt sign or radiographic signs of bowel trauma in the presence of pneumoperitoneum is highly predictive of injury and these patients should be explored¹¹.

With these information, PP after blunt trauma is a serious problem for surgeons. When there is no pneumothorax, pneumomediastinum or pneumocardia, we think that there may be a surgical cause. Because we can see free air in abdomen with pneumo-mediastinum-cardium-thorax. We can follow these patients conservatively under light of literature. But without these conditions, there may be a surgical cause. After knowing this patient, it becomes more difficult to decide a decision for PP after blunt trauma.

Conclusion

Pneumoperitoneum can be seen in many conditions. We can treat some PP patient conservatively when diagnose includes pneumothorax, pneumomediastinum, chronic obstructive pulmonary disease, cardiopulmonary resuscitation, mechanical ventilation or other knowing causes. But, if there is no explanatory cause, do we have to operate the patient to avoid missing intraabdominal injuries? We may not operate these patients and treat with conservative methods. But, it is a very difficult decision for surgeons treating conservatively without any explanatory causes like pneumothorax or pneumomediastinum after blunt trauma like this case. Conservative management for pneumoperitoneum in the absence of viscus perforation is a safe option in carefully selected cases.

References

1. MD magazine, Idiopathic pnemoperitoneum after blunt chest trauma, http://www.mdmag.com/journals/surgical-rounds/2008/2008-04/2008-04_02/2008.
2. Pitiakoudis M, Zazos P, Oikonomou A, Kirmanidis M, Kouklakis G, Simopoulos C. Spontaneous idiopathic pneumoperitoneum presenting as an acute abdomen: a case report. *J Med Case Rep* 2011;5:86.
3. Mularki RA, Mularski RA, Ciccolo ML, Rappaport WD. Nonsurgical causes of pneumoperitoneum. *West J Med* 1999;170(1):41-6.
4. Nayak Samir R, Anindita Mishra, Soren Dilip Kumar, S. Nagendra Babu Spontaneous pneumoperitoneum following blunt trauma chest - diagnostic dilemma - role of diagnostic laparoscope - a case report *IJCRR* 2013;5(10):51-6.

5. Di Saverio S, Filicori F, Kawamukai K, Boaron M, Tugnoli G. Combined pneumothorax and pneumoperitoneum following blunt trauma: an insidious diagnostic and therapeutic dilemma. *postgrad med j* 2011;87:75–8.
6. Gantt CB Jr, Daniel WW, Hallenbeck GA. Nonsurgical pneumoperitoneum. *Am J Surg* 1977;134(3):411–4.
7. O. Anderson, A. Yaakub, A. Sinha. Pneumoperitoneum associated with pneumopericardium and pneumomediastinum following blunt chest trauma. *Injury Extra* 2007;38:439–41.
8. Marco Assenza, Fabiola Passafiume, Lorenzo Valesini, Leonardo Centonze, Valentina Romeo, Claudio Modini. Pneumomediastinum and Pneumoperitoneum after Blunt Chest Trauma: The Macklin Effect. *J Trauma Treatment* 2012;1:107.
9. Ahmad R, Mohamad N, Latiff AKA, Ahmad Z, Idrus II. Pneumoperitoneum following blunt abdominal injury: Does it warrant laparotomy? *International Journal of Case Reports and Images* 2011;2(12):23–7.
10. Nishina M, Fujii C, Ogino R, Kobayashi R, Kohama A. Pneumoperitoneum and pneumoretroperitoneum in blunt trauma patients. *J Trauma* 2000;49:565–6.
11. Marek AP, Deisler RF, Sutherland JB, Punjabi G, Portillo A, Krook J, et al. CT scan-detected pneumoperitoneum: an unreliable predictor of intra-abdominal injury in blunt trauma. *Injury* 2014;45(1):116–21.