

PAPER DETAILS

TITLE: PREVALENCE AND CHARACTERISTICS OF PNEUMATIZED ARTICULAR EMINENCE
ON PANORAMIC RADIOGRAPHS: A RETROSPECTIVE STUDY AND LITERATURE REVIEW

AUTHORS: Gözde SERINDERE, Ceren AKTUNA BELGIN

PAGES: 332-339

ORIGINAL PDF URL: <https://dergipark.org.tr/tr/download/article-file/906872>

PREVALENCE AND CHARACTERISTICS OF PNEUMATIZED ARTICULAR EMINENCE ON PANORAMIC RADIOGRAPHS: A RETROSPECTIVE STUDY AND LITERATURE REVIEW

Panoramik Radyograflarda Pnömatize Artiküler Eminens Prevalansı ve Özellikleri: Retrospektif Bir Çalışma ve Literatür Taraması

Gözde SERİNDERE¹, Ceren AKTUNA BELGİN²

^{1,2}Hatay Mustafa Kemal University, Faculty of Dentistry, Department of Dentomaxillofacial Radiology, HATAY, TÜRKİYE

ABSTRACT

ÖZ

Objective: Pneumatized articular eminence (PAE) is an air filled cavity in temporal bone. The aim of this research was to evaluate the prevalence and characteristics of PAE using panoramic radiography.

Material and Methods: The panoramic radiographs of 1000 patients were analyzed to describe prevalence and characteristics of PAE. Patients with PAE had a mean age of 35 years with a range of 19–85 years. Gender, age, localization and locularity of pneumatization were noted.

Results: PAE was found in 19 (1.9%) patients with a mean age of 34.4. Twelve patients were female and seven patients were male. There was no statistically significant difference between gender and the presence of PAE ($p>0.05$). 12 unilateral and 7 bilateral cases were observed. Nine patients (47.4%) had PAE on the left side while three patients (15.8%) had PAE on the right side. Unilocular appearances were found in 7 patients (36.8%) while multilocular appearances were found in 11 patients (57.9%). One patient (5.3%) had both unilocular and multilocular types.

Conclusion: Awareness for this anatomical variation is important for differential diagnosis from other lesions and also for planning temporomandibular joint surgery. Because of fragile structure of bone with PAE, the surgeons should be careful during temporomandibular joint operations.

Amaç: Pnömatize artiküler eminens (PAE), temporal kemikte hava dolu bir boşluktur. Bu araştırmanın amacı, panoramik radyografi kullanılarak PAE prevalansını ve özelliklerini değerlendirmektir.

Gereç ve Yöntemler: PAE prevalansı ve özelliklerini tanımlamak için 1000 hastanın panoramik radyografileri analiz edildi. PAE görülen hastaların yaş ortalaması 35, yaş aralığı ise 19-85 arasındaydı. Cinsiyet, yaş, pnömatizasyonun lokalizasyonu ve lökularitesi kaydedildi.

Bulgular: Yaş ortalaması 34.4 olan 19 hastada (%1.9) PAE bulundu. 12 hasta kadın, 7 hasta erkekti. Cinsiyet ile PAE varlığı arasında istatistiksel olarak anlamlı fark bulunmamıştır ($p>0.05$). 12 unilateral ve 7 bilateral vaka gözlemlendi. Dokuz hastada (%47.4) sol tarafta PAE, üç hastada (%15.8) sağ tarafta PAE vardı. Yedi hastada (%36.8) uniloküler görünüm, 11 hastada (%57.9) multiloküler görünüm bulundu. Bir hastada (%5.3) hem uniloküler hem de multiloküler tip vardı.

Sonuç: Bu anatomik varyasyonu bilmek, diğer lezyonlardan ayırıcı tanı koymak ve ayrıca temporomandibular eklem ameliyatını planlamak için önemlidir. PAE bulunan kemiğin fragil yapısı nedeniyle, cerrahlar temporomandibular eklem operasyonlarında dikkatli olmalıdırlar.

Keywords: Pneumatized articular eminence, temporomandibular joint, panoramic radiography

Anahtar Kelimeler: Pnömatize artiküler eminens, temporomandibular eklem, panoramik radyografi



Correspondence / Yazışma Adresi:

Hatay Mustafa Kemal University, Faculty of Dentistry, Dept. Dentomaxillofacial Radiology, HATAY, TÜRKİYE

Phone / Tel: +905058659063

Received / Geliş Tarihi: 08.05.2019

ORCID NO: ¹0000-0001-7439-3554 ²0000-0001-7780-3395

Dr. Gözde SERİNDERE

E-mail / E-posta: gozdeserindere@mku.edu.tr

Accepted / Kabul Tarihi: 15.12.2019

INTRODUCTION

Pneumatization is an entity of air cell cavities of a bone. Pneumatized articular eminence (PAE) is also called as zygomatic air cell defect and is an anatomical variation. Pneumatization is observed in the zygomatic arch root and in the articular eminence (1). This variation was termed as PAE by Tyndall and Matteson (2). PAE was defined in three groups according to the incidence of temporal bone. First group is an asymptomatic radiolucent defect in the zygomatic process of the temporal bone. This appearance is similar with mastoid air cells. The second is that the defect extends to the front of the articular tubercle but does not extend beyond the zygomaticotemporal suture. Third is cases with no extension or cortical destruction in the zygomatic bone. PAE can be observed as unilateral or bilateral and have two locularity types as unilocular or multilocular (3,4).

Panoramic radiography (PR) technique was the initial modality to evaluate these variations as this method has more advantages than computed tomography such as lower cost and lower radiation dose (5). Additionally, it is used for routine dental examination so all patients referring to the clinic have PRs.

The aim of this study was to evaluate the prevalence and characteristics of PAE in adult patients and to discuss the results of other studies from different populations while presenting a brief literature review of the PAE.

MATERIALS AND METHODS

PRs of 1000 patients (464 males and 536 females) who applied for routine dental examination between the years of 2017 and 2018 at Hatay Mustafa Kemal University, Faculty of Dentistry were evaluated.

Ethical approval (Date: 30.11.2018; Decision number: 01/01) was provided by the ethics committee of the

Medical Faculty of Hatay Mustafa Kemal University. The mean age of the patients was 35 ranging from 19 to 85. Images with insufficient quality to observe articular eminence, the patients with the history of trauma, fracture or surgical operations in TMJ region were excluded from this study.

PRs were taken on 70 kVp and 10 mA using a Planmeca Promax Digital Panoramic X-ray machine (Planmeca Inc., Helsinki, Finland). The PR machine had CCD image dedector and 2.5 mm total aluminium filtration. All images were evaluated by two observers with the same Planmeca Romexis software program. The gender and age of the patients were recorded. The images with PAE were re-evaluated by two observers and both observers had the same results for all images with PAE.

The patients were divided into 4 age groups: 19-29, 30-39, 40-49, 50 and over years respectively. The localization of all PAE was noted. The locularity of PAE was classified as unilocular or multilocular based on the study of Tyndall and Matteson (2). When a single radiolucent defect was observed, unilocular PAE was noted. But several radiolucent small defects were described as multilocular PAE.

Statistical Analysis

The data obtained in this study were analyzed by SPSS 21 software package program. The chi-square test was used for the dependence of variables and the Mann-Whitey U test was used for comparison between groups. The interobserver agreement was examined by Kappa statistics. P values <0.05 were accepted to indicate statistical significance.

RESULTS

This study consisted of 1000 patients and 2000 articular eminens. The mean age was 35 ranging from

19 to 85. Of these patients, 464 (46.4%) were male and 536 (53.6%) were female.

Patients with PAE had a mean age of 34.4 years with a range of 19–55 years. Twelve patients were female and 7 were male. The mean age of males was 30.1 years with a range of 19–38 years while mean age of females was 38.7 years with a range of 20–55 years. The inter-observer agreement was assessed using the Kappa coefficient test. The Kappa value was 0.95 which showed a very good agreement between the two observers.

There was no statistically significant difference between gender and the presence of PAE ($p>0.05$). PAE was detected in 19 patients.

While the prevalence of PAE in males was 1.5%, this rate was 2.2% in females. PAE was mostly observed between the ages of 19 and 29. (Table 1). There was no statistically significant difference between age groups and the presence of PAE ($p>0.05$).

Seven (36.8%) of the patients had PAE bilaterally. Nine patients (47.4%) had PAE on the left side while three patients (15.8%) had PAE on the right side (Figure 1). Unilocular appearances were found in 7 (36.8%) patients while multilocular appearances were found in 11 (57.9%) patients. (Table 2 and Figure 2). Interestingly, in one patient (5.3%), multilocular appearance was observed on the right side while there was unilocular appearance on the left side (Figure 3).

Table 1. The prevalence of PAE by age and gender

		Patients (n)	PAE (n)	Prevalence (%)
Age (Years)	19-29	397	7	1.8 %
	30-39	276	5	1.8 %
	40-49	215	4	1.9 %
	50- over	112	3	2.7 %
Gender	Male	464	7	1.5%
	Female	536	12	2.2%
Total		1000	19	1.9 %

Table 2. Distribution of PAE by laterality and types

		PAE (n)	Prevalence (%)
Laterality	Right	3	15.8
	Left	9	47.4
	Bilateral	7	36.8
	Total	19	100.0
Type	Unilocular	7	36.8
	Multilocular	11	57.9
	Both unilocular and multilocular types	1	5.3
	Total	19	100.0

Table 3. Prevalence and features of pneumatized articular eminence in the previous studies with panoramic radiography.

Author	Sample size	PAE cases	Gender		Mean age of PAE cases	Unilateral /Bilateral	Unilocular/Multilocular
			M	F			
Bhalchim et al (11)	3000	59 (1.96%)	34	25	-	39/20	41/16 (2 patients had both types)
Carter et al (19)	2734	40 (1.5%)	20	20	49.6	32/8	-
Dasari et al (10)	1680	41 (2.4%)	-	-	-	26/15	-
Gadda et al (20)	400	11 (2.75%)	6	5	33.9	10/1	11/0
Hs et al (21)	600	15 (2.5%)	7	8	30.2	9/6	2/13
Kaugars et al (22)	784	8 (1.02%)	1	7	50.5	4/4	-
Khojastepour et al (9)	3098	64 (2.1%)	23	41	35.11	40/24	49/39 (Total 88 PAEs)
Kishore et al (23)	2500	63 (2.5%)	38	25	37.4	44/19	49/14
Nagaraj et al (12)	600	16 (2.7%)	10	6	-	11/5	9/7
Orhan et al (24)	1049	17 (1.62%)	9	8	11.2	10/7	10/7
Orhan et al (4)	1006	19 (1.88%)	7	12	36.6	12/7	10/16 (Total 26 PAEs)
Shokri et al (13)	1563	98 (6.2%)	33	65	22.8	64/34	52/46
Tyndall and Matteson (2)	1061	28 (2.6%)	13	15	32.5	23/5	17/16
Yavuz et al (25)	8107	83 (1.03%)	42	41	26.9	56/27	44/66
Present study	1000	19 (1.9%)	7	12	34.4	12/7	7/12

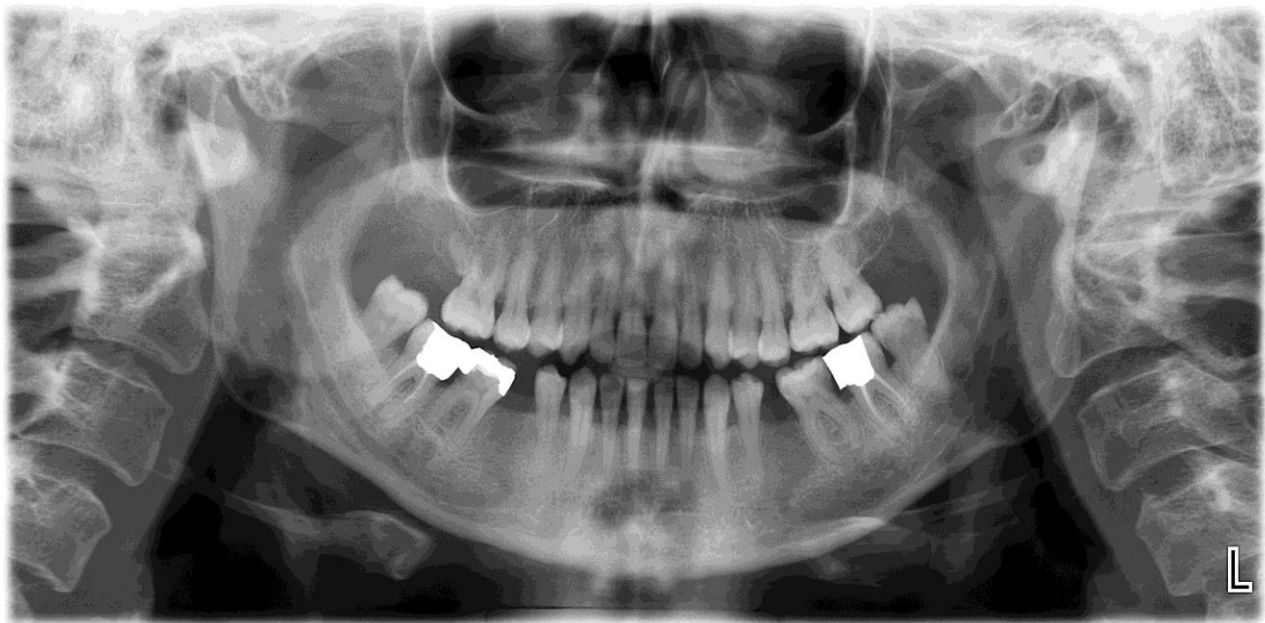


Figure 1: Bilateral PAE

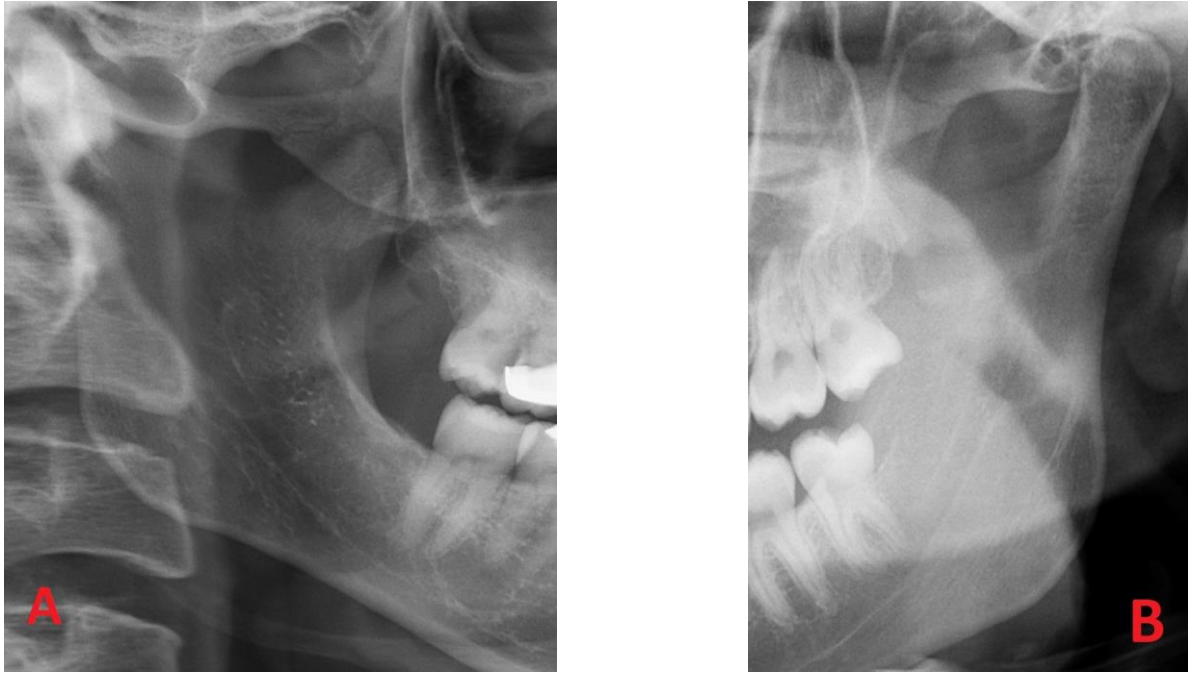


Figure 2: Unilocular (A) and multilocular type (B) PAE

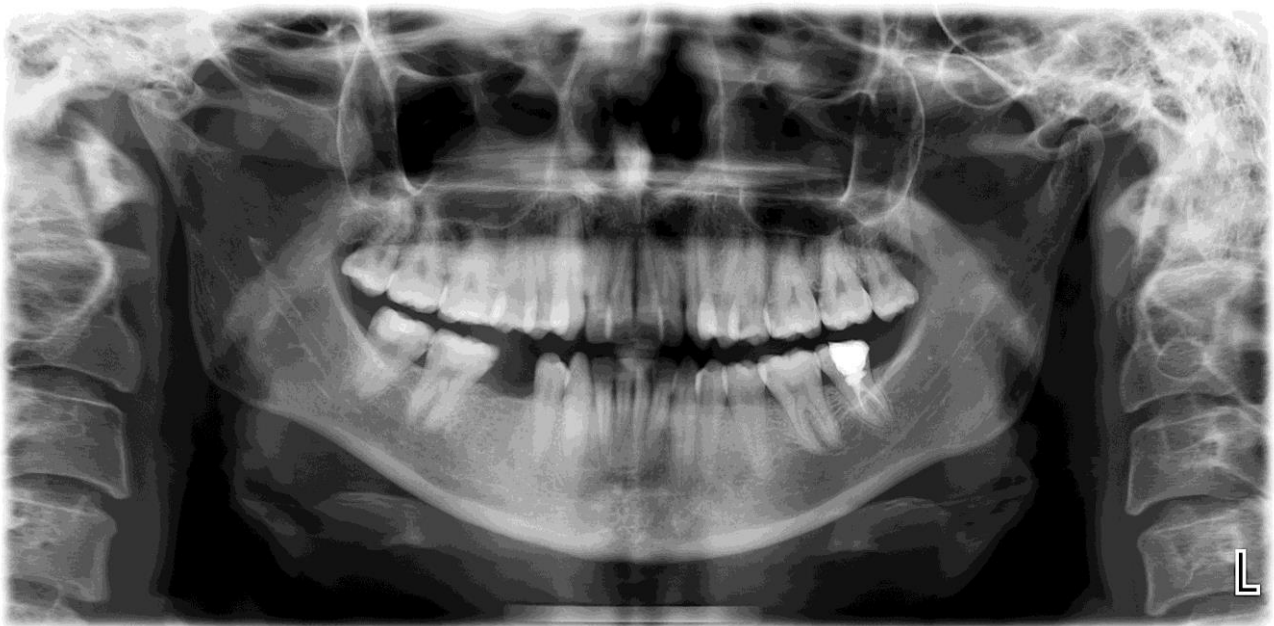

Figure 3: Multilocular PAE on the right and unilocular PAE on the left.

DISCUSSION

Since the resistance of the bone decreases in the presence of PAE, various disease processes such as

tumors, inflammations and fractures in this region can easily spread (6). Furthermore, due to this pneumatization, otitis media, otomastoiditis or ear tumors can easily spread and affect the TMJ (7,8).

Khojastepour et al. examined PAE prevalence on 3098 PRs and found PAE in 2.1% of cases (9). Similar to our study, it was reported that there was no significant difference in PAE for gender or different age groups. Dasari et al. also reported a similar result of PAE prevalence as 2.4% (10). However, the result closest to our study belonged to the studies of Bhalchim et al. (1.96%) and Orhan et al. (1.88%) (4,11). PAE was most commonly found between the age groups of 20-29 (4) and 15-34 (11). In our study, PAE was observed mostly between the ages of 19 and 29. Nagaraj et al. stated that 69% of PAE cases were unilateral and 56% of PAE cases were unilocular (12). In our study, 36.8% of PAE cases were bilateral and 57.9% of PAE cases were multilocular. Shokri et al. reported a higher prevalence as 6.2% with 65.3% of PAE cases being unilateral. Unilocular PAE cases were 53.06% while 46.94% were multilocular (13). The results showed no statistically significant difference regarding age and gender similar to our study. Also, in this study, the rate of unilocular appearance was found to be lower than the study of Shokri et al (13). Interestingly in the present study, both locularity types were observed in one patient. Bhalchim et al. reported two patients who had unilocular on side and multilocular on the other side (11). The detailed results of previous studies are showed in Table 3.

Diagnosis of PAE is important for the surgical operations. The entity of PAE increases the perforation risk and undesirable complications during surgery in TMJ region such as eminectomy and eminoplasty (5,14,15). PAE reduces bone resistance and provides an easier spread of infection and tumors. It also facilitates fracture formation (5). However, the treatment of PAE is not needed. Although PAE is asymptomatic, observation of the patient is necessary as the differential diagnosis of PAE includes lesions such as giant cell tumour, metastatic tumor, fibrous dysplasia, hemangioma, aneurysmal bone cyst and eosinophilic granuloma but all these lesions produce

painful expansion in the cheek area and destruction on radiographs (16).

PAE may be observed by using Waters' and Towne's projection, and submentovertex, transcranial view for TMJ, but sufficient observation of the zygomatic arch posterior side cannot be done with these modalities. PR is routinely preferred and is an easy method sufficient for imaging the zygomatic arch (17). However, a better observation is provided by using Cone Beam Computed Tomography (CBCT) in the mid-face region because superimpositions are removed (18). So, we observed that in the study with CBCT, a higher prevalence of PAE was reported in comparison to the studies with PR.

In conclusion, the prevalence of PAE in the present study was found to be similar to the previous studies with panoramic radiography. However, to the best of our knowledge, the two different locularity types that was seen in the same patient is a rare condition. The diagnosis of PAE is incidentally made but is important for reducing risks after surgery and to distinguish this entity from pathological lesions in this area. Further studies from other populations will be useful to better understand PAE's different clinical and radiological characteristics.

Acknowledgments: None related to the present manuscript.

Conflicts of Interest: No conflicts of interest to declare.

REFERENCES

1. Beaumont GD. The effects of exclusion of air from pneumatized bones. J Laryngol Oto. 1966;80(3):236-49.
2. Tyndall DA, Matteson SR. Radiographic appearance and population distribution of the pneumatized articular eminence of the temporal bone. J Oral Maxillofac Surg. 1985;43(7):493-7.

3. de Rezende Barbosa GL, Nascimento Mdo C, Ladeira DB, Bomtorim VV, da Cruz AD, Almeida SM. Accuracy of digital panoramic radiography in the diagnosis of temporal bone pneumatization: a study in vivo using cone beam computed tomography. *J Craniomaxillofac Surg.* 2014;42(5):477-81.
4. Orhan K, Delilbasi C, Cebeci I, Paksoy C. Prevalence and variations of pneumatized articular eminence: a study from Turkey. *Oral Surg Oral Med Oral Pathol Oral Radiol Endod.* 2005;99(3):349-54.
5. Miloglu O, Yilmaz AB, Yildirim E, Akgul HM. Pneumatization of the articular eminence on cone beam computed tomography: prevalence, characteristics and a review of the literature. *Dentomaxillofac Radiol.* 2011;40(2):110-4.
6. Betz BW, Wiener MD. Air in the temporomandibular joint fossa: CT sign of temporal bone fracture. *Radiology.* 1991;180(2):463-6.
7. Orhan K, Nishiyama H, Tadashi S, Shumei M, Furukawa S. MR of 2270 TMJs: prevalence of radiographic presence of otomastoiditis in temporomandibular joint disorders. *Eur J Radiol.* 2005;55(1):102-7.
8. Hadlock TA, Ferraro NF, Rahbar R. Acute mastoiditis with temporomandibular joint effusion. *Otolaryngol Head Neck Surg.* 2001;125(1):111-2.
9. Khojastepour L, Mirbeigi S, Ezoddini F, Zeighami N. Pneumatized Articular Eminence and Assessment of Its Prevalence and Features on Panoramic Radiographs. *J Dent (Tehran).* 2015;12(4):235-42.
10. Dasari B, Kiran R, Samatha Y, Sindu YU, Kartheeki B, Bindu HM, et al. Prevalence of Zygomatic Air Cell Defects in a South Indian Population- A Retrospective Study. *Dentistry.* 2016;6(8):390.
11. Bhalchim SG, Jugade SC, Ramaswami E, Gogri AA, Kadam SG, Umarji HR. Prevalence of pneumatized articular tubercle using panoramic radiography and cone beam-computed tomography: a retrospective study. *Contemp Clin Dent.* 2018;9(2):221-6.
12. Nagaraj T, Nigam H, Balraj L, Santosh H, Ghose N, Tagore S. A population-based retrospective study of zygomatic air cell defect in Bengaluru. *J Med Radiol Pathol Surg.* 2016;3(6):5-8.
13. Shokri A, Noruzi-Gangachin M, Baharvand M, Mortazavi H. Prevalence and characteristics of pneumatized articular tubercle: First large series in Iranian people. *Imaging Sci Dent.* 2013;43(4):283-7.
14. Hofmann T, Friedrich RE, Wedl JS, Schmelzle R. Pneumatization of the zygomatic arch on pantomography. *Mund Kiefer Gesichtschir.* 2001;5(3):173-9.
15. Ladeira DB, Barbosa GL, Nascimento MC, Cruz AD, Freitas DQ, Almeida SM. Prevalence and characteristics of pneumatization of the temporal bone evaluated by cone beam computed tomography. *Int J Oral Maxillofac Surg.* 2013;42(6):771-5.
16. Borahan M, Yildiz Sadikoglu A, Ulay G, Namdar Pekiner F. A Preliminary Study of Prevalence and Characteristics of Pneumatization of Articular Eminence on Cone Beam Computed Tomography. *European Journal of Research in Dentistry.* 2018;2(1):6-11.
17. Tyndall DA, Matteson SR. The zygomatic air cell defect (ZACD) on panoramic radiographs. *Oral Surg Oral Med Oral Pathol.* 1987;64(3):373-6.
18. De Vos W, Casselman J, Swennen GR. Cone-beam computerized tomography (CBCT) imaging of the oral and maxillofacial region: A systematic review of the literature. *Int J Oral Maxillofac Surg.* 2009;38(6):609-25.

19. Carter LC, Haller AD, Calamel AD, Pfaffenbach AC. Zygomatic air cell defect (ZACD). Prevalence and characteristics in a dental clinic outpatient population. *Dentomaxillofac Radiol.* 1999;28(2):116-22.
20. Gadda R, Patil NA, Salvi R. Zygomatic air cell defect: prevalence and characteristics in dental outpatient population. *J Contemp Dent.* 2012;2(3):69-72.
21. Hs S, Patil K, Vg M. Zygomatic air cell defect: A panoramic radiographic study of a south Indian population. *Indian J Radiol Imaging.* 2010;20(2):112-4.
22. Kaugars GE, Mercuri LG, Laskin DM. Pneumatization of the articular eminence of the temporal bone: prevalence, development, and surgical treatment. *J Am Dent Assoc.* 1986;113(1):55-7.
23. Kishore M, Panat SR, Kishore A, Aggarwal A, Upadhyay N, Agarwal N. Prevalence of Zygomatic Air Cell Defect using Orthopantomogram. *J Clin Diagn Res.* 2015;9(9):ZC09–ZC11.
24. Orhan K, Delilbasi C, Orhan AI. Radiographic evaluation of pneumatized articular eminence in a group of Turkish children. *Dentomaxillofac Radiol.* 2006;35(5):365-70.
25. Yavuz MS, Aras MH, Güngör H, Büyükkurt MC. Prevalence of the pneumatized articular eminence in the temporal bone. *J Craniomaxillofac Surg.* 2009;37(3):137-9.