

## PAPER DETAILS

TITLE: COUSIN SYNDROME; UNUSUAL GENETIC DISEASE PELVISCAPULAR DYSPLASIA  
AND CRANIOFACIAL DYSMORPHISM: A CASE REPORT AND REVIEW THE LITERATURE

AUTHORS: Hatice AGIR, Sahika Burcu KARACA

PAGES: 347-350

ORIGINAL PDF URL: <https://dergipark.org.tr/tr/download/article-file/2651212>

## COUSIN SYNDROME; UNUSUAL GENETIC DISEASE PELVISCAPULAR DYSPLASIA AND CRANIOFACIAL DYSMORPHISM: A CASE REPORT AND REVIEW THE LITERATURE

*Cousin Sendromu; Sıradışı Genetik Hastalık ve Pelviskapular Displazi ve Kraniofasiyal  
Dismorfizm: Bir Vaka Sunumu ve Literatürün İncelenmesi*

Hatice AĞIR<sup>1</sup>  Şahika Burcu KARACA<sup>2</sup> 

<sup>1</sup> Department of Physical Medicine and Rehabilitation, Şanlıurfa Training and Research Hospital, ŞANLIURFA, TÜRKİYE

<sup>2</sup> Department of Physical Medicine and Rehabilitation, Kırıkkale University School of Medicine, KIRIKKALE, TÜRKİYE

### ABSTRACT

Cousin Syndrome; also called pelviscapular dysplasia, is a genetic disease caused by TBX15 gene mutation, which is characterized by craniofacial dysmorphism and various musculoskeletal anomalies. Cousin Syndrome was first described in the literature by Cousin et al. in 1982 in two North African siblings. So far only three unrelated individuals have been reported in the literature with otozomal recessive mutations in TBX15. In our case, a 50-year-old female patient with Cousin syndrome who had pelvic and scapular hypoplasia accompanied by craniofacial dysmorphism, short stature and extremity, scoliosis, humeroradial synostosis, and rehabilitation results are presented. We wanted to contribute to the literature by describing the clinical features of a patient with Cousin Syndrome, which is very rare in the world. At the same time, we wanted to emphasize the importance of rehabilitation in this patient who has a wide range of musculoskeletal deformities and limitation in daily living activities due to a genetic skeletal dysplasia.

**Keywords:** Pelviscapular dysplasia, craniofacial dysmorphism, musculoskeletal anomalies, TBX15 gene

### ÖZ

Cousin Sendromu; pelviskapular displazi olarak da adlandırılan, kraniofasiyal dismorfizm ve çeşitli kas-iskelet anomalileri ile karakterize, TBX15 gen mutasyonunun neden olduğu genetik bir hastalıktır. Cousin Sendromu literatürde ilk olarak Cousin ve ark. 1982'de iki Kuzey Afrikalı kardeşle. Şimdiye kadar literatürde TBX15'te otozomal resesif mutasyonları olan sadece üç birey bildirilmiştir. Olgumuzda kraniofasiyal dismorfizm, boy ve ekstremité kısalığı, skolyoz, humeroradial sinostozun eşlik ettiği pelvik ve skapular hipoplazisi olan Cousin sendromlu 50 yaşında kadın hasta ve rehabilitasyon sonuçları sunulmaktadır. Dünyada çok nadir görülen bu sendromlu hastanın klinik özelliklerini anlatarak literatüre katkıda bulunmak istedik. Aynı zamanda genetik iskelet displazisi nedeniyle çok çeşitli kas- iskelet sistemi deformiteleri ve günlük yaşam aktivitelerinde kısıtlılığı olan bu hastada rehabilitasyonun önemini vurguladık.

**Anahtar Kelimeler:** Pelviskapular displazi, kraniofasiyal dismorfizm, kas-iskelet anomalileri, TBX15 geni



Correspondence / Yazışma Adresi:

Department of Physical Medicine and Rehabilitation, Şanlıurfa Training and Research Hospital, ŞANLIURFA, TÜRKİYE

Phone / Tel: +905541152590

Received / Geliş Tarihi: 14.09.2022

Dr. Hatice AĞIR

E-mail / E-posta: haticeagir10@hotmail.com

Accepted / Kabul Tarihi: 22.05.2023

## INTRODUCTION

Cousin Syndrome; also called pelviscapular dysplasia, is a genetic disease caused by TBX15 gene mutation, which is characterized by craniofacial dysmorphism and various musculoskeletal anomalies. Cousin Syndrome was described first by Cousin et al. in 1982 in two North African siblings. These two siblings, whose parents were first-degree cousins, having similar phenotypic features (congenital dwarfism, facial dysmorphism, and various skeletal anomalies including bilateral agenesis of the scapula and hypoplasia of the ilium ala and acetabulum responsible for hip dislocation) were suggested a new genetic syndrome (1). At that time, it was predicted that the disease was inherited autosomal recessively. So far only three unrelated individuals have been reported in the literature with otozomal recessive mutations in TBX15 (2,3).

In this article, we wanted to contribute to the literature by describing the clinical features of a patient with Cousin Syndrome, which is very rare in the world. At the same time, we wanted to emphasize the importance of rehabilitation in this patient who has a wide range of musculoskeletal deformities and limitations in daily living activities due to a genetic skeletal dysplasia. Written informed consent was obtained from the patient.

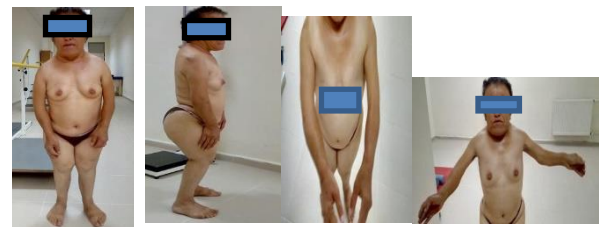## CASE REPORT

A 50-year-old female patient was admitted to our physical therapy outpatient clinic with complaints of difficulty in activities of daily living and widespread musculoskeletal pain. Our patient was born in a family with three children. The patient was of normal intelligence and memory, and had good communication skills. Due to family and social reasons, she had to leave her education in primary school level. She could read and write. There was no consanguineous marriage in the patient's family history. Her other two siblings were healthy. She had lost her mother due to osteosarcoma and was living with her father. She had a history of two plastic reconstructive surgeries and hysterectomy for

both ears. There was an internal fixator in the radius due to a fracture of the lower end of the left radius after a falling.

The general condition of the patient was good, she was cooperative. On physical examination, the patient's height was 118 cm (<3rd percentile), weight was 20 kg (<3rd percentile), and head circumference was 55 cm. In the facial image; she had macrocephaly, prominent frontal region, flattened nasal root, narrow palpable fissure, low set ears, dropping helix, prominent arched eyebrows, concha dysplasia, skin thickening, temporal baldness, hypertelorism, short neck distance, low hairline. In her general appearance, there was a short neck distance, short legs and trunk, scapular hypoplasia, atrophy of deltoid muscles, ankylosis in flexion posture in both elbows, flexion posture in hips and knees, increase in lumbar lordosis (Figure 1).

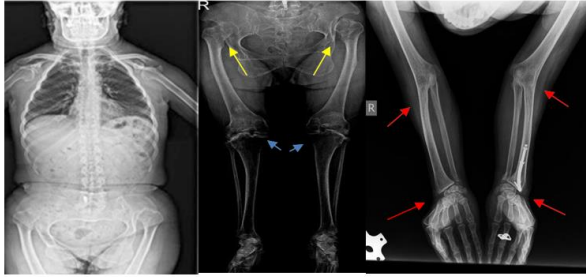
Cervical range of motion (ROM); flexion was open, extension was 0-40°. Bilateral shoulder abduction and flexion was 0-90°, internal and external rotation was 0-45°, both elbows were ankylosed by -20°, pronation and supination movements could not be made. Wrist and finger ROM was complete. However, the patient had difficulties in activities of daily living. Lumbar movements and hip ROM were complete. Left knee flexion was 0-60°. The right knee, ankle and joint range of motion were complete. The actual leg length of the patient was measured as 57.5 cm on the right and 56 cm on the left. No abnormality was detected in the neurological examination.



**Figure 1:** Phenotypic characteristics of the patient with cousin syndrome

On direct radiographs of the patient, there was scapular hypoplasia, fusion in the humeroradial joint, hypoplasia of the carpal bones, internal fixator inserted after

fracture in the left radius, diffuse arthrosis, bilateral hip dysplasia, grade 4 gonarthrosis, severe degenerative changes, widespread osteopenic appearance (Figure 2). Cranial magnetic resonance imaging revealed brachiocephaly, platybasia appearance, thick calvarium, cerebellar and cerebral atrophy, frontal prominence, fusion in the atlantoaxial region.



**Figure 2:** Scapular hypoplasia, fusion in the humeroradial joint, hypoplasia in the carpal bones, internal fixator inserted after fracture in the distal left radius, diffuse arthrosis, bilateral hip dysplasia, grade 4 gonarthrosis, severe degenerative changes, extensive osteopenic appearance (arrows)

A physical therapy and rehabilitation protocol was created for the patient. Exercises aimed at gaining independence in life activities, occupational therapy for the upper extremity, posture exercises, joint range of motion and stretching exercises were applied especially for the knee and both shoulders. Insoles were prescribed for the patient with 1.5 cm shortness in the left lower extremity. Walking training in proper posture was given with insoles reinforcement. The patient, who had osteopenic appearance and widespread musculoskeletal pain on the radiographs, was evaluated for osteoporosis with bone mineral densitometer. Vitamin D supplementation was given to the patient whose vitamin D was 20 ng/mL, and then bisphosphonate treatment was started.

At discharge, 10 degrees of gain was achieved in internal rotation and abduction of both shoulders. The pre-rehabilitation Health Assessment Questionnaire (Health Assessment Questionnaire-HAQ) score of the patient, who had difficulties in daily living activities due to the shortness and limitations in both upper and lower extremities, was found to be 33. The HAQ value decreased from 33 to 22 after treatment.

## DISCUSSION

Cousin syndrome, also called pelviscapular dysplasia (OMIM 260660), is characterized by short stature, craniofacial dysmorphism, and multiple skeletal anomalies. Cousin Syndrome is caused by a homozygous mutation in the TBX15 gene on chromosome 1p12 (1). The TBX15 gene controls the number of mesenchymal precursor cells and chondrocytes, and plays an important role in the formation of the vertebral column and cranium. This gene belongs to the T box family of genes encoding a phylogenetically conserved family of transcription factors that regulate various developmental processes (4,5).

The general clinical features of patients with Cousin Syndrome are the presence of systemic problems such as congenital heart defects, megacolon, renal anomalies and ocular findings accompanying different musculoskeletal system findings. Musculoskeletal system findings include pelvic and scapular hypoplasia, short stature and extremity accompanied by craniofacial dysmorphism, scoliosis, humeroradial synostosis, polydactyly, oligodactyly, brachydactyly. Typical dysmorphic facial findings seen in patients; frontal bossing, temporal baldness, hypertelorism, strabismus, narrow palpebral fissures, low-set ears, narrow auditory canals, hypoacusis, skin thickness, acneiform appearance, short neck structure, low hairline (6).

Following its description in two siblings in 1982, no new cases have been observed until the observation of two unrelated cases in 2008 who were homozygous for frameshift mutations in TBX15. So far only three unrelated individuals have been reported in the literature with recessive mutations in TBX15 (2). It was emphasized that a recessive disorder reported as scapulohumeral dysostosis by Elliott et al. in 2000 may be the same disorder as this disease reported by Cousin et al. in 1982 (7).

In our case, typical dysmorphic facial appearance, short stature and leg length, bilateral acetabular and iliac hypoplasia, bilateral scapular hypoplasia, fusion in the

humero radial joint were similar to other described cases. High cognitive level and communication skills were different from some cases defined as mental retardation. In terms of system involvement, there was moderate hearing loss. There was no cardiac involvement. While there were consanguineous marriages in all cases described in the literature, there was no history of consanguineous marriage in our case and her other siblings were healthy. As a result of the rehabilitation program applied to our patient with Cousin Syndrome, partial improvement in daily living activities and partial increase in functional capacity were detected. With this case example, it can be emphasized that even in genetic syndromes with permanent skeletal anomalies, improvement in daily living activities can be achieved, albeit partially, with a rehabilitation program.

*Conflict of Interest:* All authors declare that there is no conflict of interest.

*Researchers' Contribution Rate Statement:* All authors made substantial contributions to the article. Idea-planning: HA, ŞBK; analysis-interpretation: HA, ŞBK; data acquisition: HA, ŞBK; manuscript preparation HA, ŞBK and final manuscript approval HA.

*Support and Acknowledgment:* No financial support was received from any source for this work.

*Informed Volunteer/Consent Form:* Written informed consent was obtained from the patient for publication of this case report.

## REFERENCES

1. Cousin J, Walbaum R, Cegarra P, Huguet J, Louis J, Pauli A et al. Dysplasie pelvi-scapulaire familiale avec anomalies épiphysaires, nanisme et dysmorphies: Un nouveau syndrome? [Familial pelvi-scapular dysplasia with anomalies of the epiphyses, dwarfism and dysmorphism: A new syndrome? (author's transl)]. Arch Fr Pediatr. 1982;39(3):173-5.
2. Dikoglu E, Simsek-Kiper PO, Utine GE, Campos-Xavier B, Boduroglu K, Bonafé L et al. Homozygosity for a novel truncating mutation confirms TBX15 deficiency as the cause of Cousin syndrome. Am J Med Genet A. 2013;161A(12):3161-5.
3. Lausch E, Hermanns P, Farin HF, et al. TBX15 mutations cause craniofacial dysmorphism, hypoplasia of scapula and pelvis, and short stature in Cousin syndrome. Am J Hum Genet. 2008;83(5):649-55.
4. Ghosh TK, Brook JD, Wilsdon A. T-Box Genes in human development and disease. Curr Top Dev Biol. 2017;122:383-415.
5. Sheeba CJ, Logan MP. The Roles of T-Box Genes in vertebrate limb development. Curr Top Dev Biol. 2017;122:355-81.
6. Chong, AKS, Flores RP, Lee EH. Skeletal Dysplasias. In: Abzug, J., Kozin, S., Zlotolow, D. (eds) The Pediatric Upper Extremity. Springer, New York, NY, 2015:467-82.
7. Elliott AM, Roeder ER, Witt DR, Rimoin DL, Lachman RS. Scapuloiliac dysostosis (Kosenow syndrome, pelvis-shoulder dysplasia) spectrum: Three additional cases. Am J Med Genet. 2000;95(5):496-506.