

## PAPER DETAILS

TITLE: Acute Arterial Thrombosis Following Chemoterapy in Patient with Oral Cavity Carcinoma-  
Importance of Decision Making in Family Medicine Practice- A Case Report

AUTHORS: Nevena Ivanova

PAGES: 107-111

ORIGINAL PDF URL: <https://dergipark.org.tr/tr/download/article-file/3474270>

## CASE REPORT

 Nevena G. Ivanova<sup>1,2</sup>

<sup>1</sup> Department of Urology and General Medicine, Faculty of Medicine, Medical University of Plovdiv, Plovdiv, Bulgaria

<sup>2</sup> St Karidad MHAT, Karidad Medical Health Center, Cardiology, Plovdiv, Bulgaria

### Corresponding Author:

Nevena G. Ivanova  
mail: nevenai@yahoo.com

Received: 24.10.2023

Acceptance: 13.02.2024

DOI: 10.18521/kt.1375865

Konuralp Medical Journal

e-ISSN1309-3878

konuralptipdergi@duzce.edu.tr

konuralptipdergisi@gmail.com

www.konuralptipdergi.duzce.edu.tr

## Acute Arterial Thrombosis Following Chemoterapy in Patient with Oral Cavity Carcinoma- Importance of Decision Making in Family Medicine Practice- A Case Report

### ABSTRACT

Oral cancer is most common in developing countries, but is also seen in the rest of the world. Patients with tumors have a higher risk of thrombosis, assuming that the underlying pathophysiological mechanism is endothelial dysfunction. The presented case describes the development of acute vascular thrombosis in a patient with late diagnosed carcinoma after a consecutive chemotherapy. A 62-year-old man was diagnosed with squamous cell carcinoma of the floor of the oral cavity, with subsequent surgical resection, radiotherapy and chemotherapy with cisplatin, 5-fluorouracil and cetuximab were followed. 2 days after the last infusion, acute peripheral arterial thrombosis was developed. Cancer and antitumor therapy exert a synergistic effect on coagulation activation. A probable toxic damage to the vascular endothelium leads to a decreased expression of nitric oxide synthetase and, accordingly, vasodilation, a decrease in anticoagulants and an increase in the levels of procoagulants such as tissue factor, which activates coagulation and induces the activation of platelets. The general practitioner occupies a central role in the health care system in a number of countries. In order to be able to perform its complex activities and successfully solve diverse health problems it is necessary to possess specific knowledge and skills from various fields of medicine.

**Keywords:** Squamous Cell Carcinoma, Thrombotic Complications, General Practitioner, Primary Care.

## Ağız Kavitesi Karsinomlu Hastada Kemoterapi Sonrası Akut Arteriyel Tromboz-Aile Hekimliği Uygulamasında Karar Vermenin Önemi-Olgu Sunumu

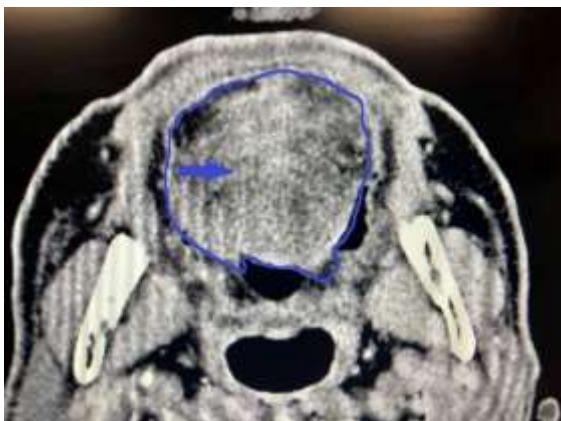
### ÖZET

Ağız kanseri en çok gelişmekte olan ülkelerde görülmekle birlikte dünyanın geri kalanında da görülmektedir. Altta yatan patofizyolojik mekanizmanın endotel disfonksiyonu olduğu varsayıldığında, tümörlü hastalarda tromboz riski daha yüksektir. Sunulan olguda, geç tanı alan karsinomlu bir hastada ardışık kemoterapi sonrasında gelişen akut vasküler tromboz anlatılmaktadır. 62 yaşındaki bir erkeğe ağız boşluğu tabanında skuamöz hücreli karsinom tanısı konuldu ve ardından cerrahi rezeksiyon, radyoterapi ve sisplatin, 5-florourasil ve setuksimab ile kemoterapi uygulandı. Son infüzyondan 2 gün sonra akut periferik arter trombozu gelişti. Kanser ve antitümör tedavisi pıhtılaşma aktivasyonu üzerinde sinerjistik bir etki gösterir. Vasküler endotelde olası bir toksik hasar, nitrik oksit sentetaz ekspresyonunun azalmasına ve buna bağlı olarak vazodilatasyona, antikoagülanların azalmasına ve pıhtılaşmayı aktive eden ve trombositlerin aktivasyonunu indükleyen doku faktörü gibi prokoagülanların seviyelerinde artışa yol açar. Pratisyen hekim birçok ülkede sağlık bakım sisteminde merkezi bir role sahiptir. Karmaşık faaliyetlerini gerçekleştirebilmek ve çeşitli sağlık sorunlarını başarıyla çözebilmek için tıbbın çeşitli alanlarından özel bilgi ve becerilere sahip olmak gerekir.

**Anahtar Kelimeler:** Skuamöz Hücreli Karsinom, Trombotik Komplikasyonlar, Pratisyen Hekim, Birinci Basamak Sağlık Hizmeti.

### CASE PRESENTATION

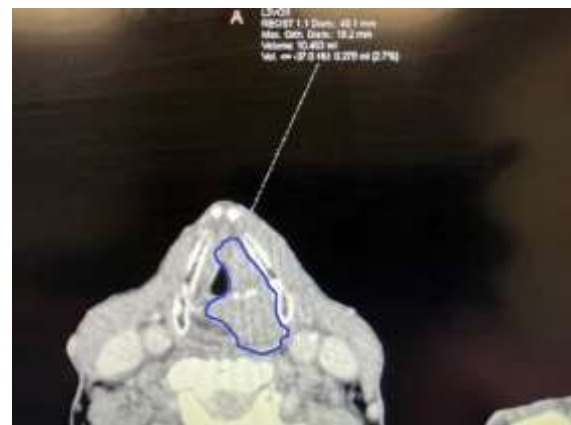A 62-year-old man, smoker for over 40 years, in October 2018 noticed a sore under the tongue. He visited his general practitioner (GP) who performed physical examination and local inspection of the oral cavity. He found ulceration under the tongue and concluded that it is a result of injury due to consumption of solid food. The doctor prescribed local therapy with gel containing glycerol-oxide-triester (TGO) in order to create a film that protects the wound from external mechanical and chemical irritations and stimulates the regeneration of the surrounding cells. In December of the same year, complaints of difficulty speaking and eating, difficulty in moving the tongue and loss of body weight appeared. After second examination by a general practitioner which revealed bigger pathological formation, he was referred and hospitalized in a maxillofacial surgery clinic. The local oral status revealed an ulcero-infiltrative lesion located in the anterior part of the floor of the oral cavity, involving the anterior third and the underlying soft tissues, as well as the ventral surface of the tongue. The neighboring teeth were of the third degree of mobility and with suspicion of lingual alveolar invasion in the area next to the premolars bilaterally. Local extraoral status revealed bilaterally enlarged lymph nodes with a size of about 2 cm, which were palpated in the right submandibular and in the left perimandibular site. A biopsy was performed, which demonstrated moderately differentiated squamous cell carcinoma of the floor of the oral cavity with massive regional lymph node metastases in extracapsular spread of the carcinoma. According to the TNM classification, T3M1Tx staging was accepted. Computed tomography (CT) revealed a tumor formation on the floor of the oral cavity with approximate dimensions of 40/40mm, involving part of the lower jaw and bilaterally enlarged perimandibular lymph nodes (Fig.1).



**Figure 1.** Computed tomography showing tumor formation on the floor of the oral cavity

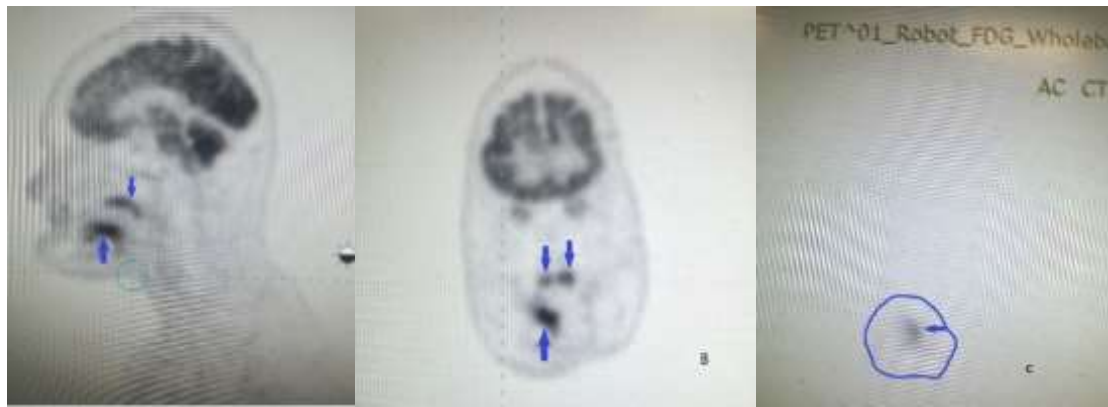The laboratory indicators showed the typical for an oncological disease deviations - iron-deficiency anemia - reduced erythrocytes  $3.1 \times 10^{12}/l$

(normal range for males  $4.2-6.2 \times 10^{12}/l$ ), hemoglobin 110g/l (normal range 140–180 g/l), hematocrit 0.27% (normal range 0.37%–0.55%), mean corpuscular volume 70 fl (MCV) [(normal range 82 – 98 fl)], iron 4.5  $\mu\text{mol}/l$  (normal range for males 5.83–34.5  $\mu\text{mol}/l$ ), increased total iron-binding capacity 82.4  $\mu\text{mol}/l$  (TIBC) [(normal range 44.8–71.6  $\mu\text{mol}/l$ )] ; erythrocyte sedimentation rate (ESR) 60 mm/h (normal range for males 1–15 mm/h), C-reactive protein (CRP) [(normal range 5–10 mg/l)]. After evaluation of the general and local status, as well as the results of the computed tomography, surgical treatment was initiated. Under general anesthesia with tracheal intubation, a radical bloc resection of the floor of the oral cavity, ventral surface of the tongue and cranial  $\frac{1}{2}$  of the height of the lower jaw, as well as bilateral selective cervical dissection was performed. Postoperatively, the patient was referred to a radiotherapy clinic, where radiotherapy was performed on the floor of the oral cavity and cervical chains on the right with a dose of up to 56 Gray and contralateral lymphatic chains on the left up to 50 Gray with the RapidARC technique in the period 01-03. 2019. In April 2023 due to complaints of a change in voice, difficulties in swallowing and breathing disorders, the patient was urgently admitted to the ear-nose-throat department. Local status revealed recurrence of tumor formation, and biopsy confirmed squamous cell carcinoma. A CT scan was performed which revealed a soft tissue lesion involving the left vocal fold, left thyroid cartilage, left aryepiglottic fold, left pharyngeal wall, and left partial epiglottis measuring approximately 40.1/19.2 mm. (Fig. 2).



**Figure 2.** Computed tomography showing soft tissue lesion involving the left vocal fold, left thyroid cartilage, left aryepiglottic fold, left pharyngeal wall, and left partial epiglottis

Subsequent the positron emission computed tomography (PET-CT) showed an increased metabolic activity was visualized in the area of the soft palate, the laryngopharynx, the right half of the floor of the oral cavity (Fig. 3A, Fig. 3B) and a cervical lymph node on the left (Fig. 3C).



**Figure 3.** PET-CT showing Increased metabolic activity in the area of the soft palate, the laryngopharynx, the right half of the floor of the oral cavity ( 3A, 3B) and a cervical lymph node on the left (3C)

Surgical treatment followed, with a total laryngectomy performed, after which the patient was referred for 6 consecutive courses of chemotherapy, once a week. Combination treatment with cisplatin 100mg, 5-fluorouracil 700mg, cetuximab 300 mg in a single intravenous infusion with Ntrium chloride 0.9% 500 ml. and lipegfilgrastim 6mg. single subcutaneous injection. was started. He was discharged form hospital in 07. 2023 and 2 days later complaints of sudden severe pain in the right lower extremity occurred. The patient approached his general practitioner by the phone and the initial treatment with nonsteroidal anti-inflammatory drugs was initiated. In several hours patient noticed pallor and coldness of the foot. Direct ambulatory consultation with the family doctor was provided who found weakened peripheral artery pulsations of the right lower extremity. According to these findings severe vascular complication was suspected. The patient was urgently referred and admitted to the vascular surgery department. Local status noted diminished palpable pulsations of the right femoral artery, absent distal, pale and cool foot. After a preoperative consultation with a cardiologist and an anesthesiologist, the surgical intervention was performed, during which it was established that the right common femoral artery was pulseless. Thrombendarterectomy (TEA) was performed, and the evacuated thrombus was cast-like (Fig. 4). Immediately after a strong pulse was restored and the patient was discharged from the operating room with stable hemodynamic parameters.



**Figure 4.** Thrombendarterectomy evacuated cast-like thrombus

## DISCUSSION

Cancer of the oral cavity occurs more often in men, usually after 50 years of age. At the beginning of the disease, the clinical presentation is atypical

and for a long time it is asymptomatic, which is why the diagnosis can be made late, when manifestations of involvement of adjacent structures or metastasis begin to dominate (1). Known premalignant lesions are leukoplakia and erythroplakia, which appear as white and red lesions, which requires a careful examination of the oral cavity by a dentist, otolaryngologist or general practitioner (2,3). These changes could be interpreted as inflammatory infiltrates or due to mechanical trauma, leading to possible diagnosis delay. Chemotherapy is a type of adjuvant therapy that is carried out with antitumor drugs, the most commonly used in oral cavity carcinomas being Cisplatin, Carboplatin, 5-fluorouracil (5-FU), Paclitaxel, Docetaxel, Hydroxyurea alone or in combination with other drugs (e.g. immunostimulators, targeted), which, however, leads to an increased risk of side effects, especially on the cardiovascular system. The two mechanisms by which the antineoplastic effect of these agents occurs are cytostatic (inhibition of cell division) and cytotoxic (destruction of the tumor cell) (4). Despite their targeted effect on the tumor, they also have a toxic effect on non-tumor cells by damaging them (5). An association with an increased risk of developing arterial and venous thrombosis has been established for some of the medications used for treatment. Platinum-based agents, such as **Cisplatin**, Carboplatin, Pyrimidine antagonists with representatives of **5-fluorouracil**, Gemcitabine, Anti-epidermal growth factor receptor antibodies ((EGFR)-**Cetuximab**, Bevacizumab) are included into this group (6,7). The exact mechanisms by which the development of thrombosis is not fully known. On the one hand, toxic damage to the vascular endothelium is assumed, which leads to a reduced expression of nitric oxide synthetase and, accordingly, vasodilation, and on the other, a decrease in anticoagulants and an increase in the levels of procoagulants such as tissue factor (TF), which activates coagulation. A third pathway of action involves the induction of platelet activation (8). Administration of 5-fluorouracil in rabbits has led to disruption of the endothelial monolayer, exposure of the subendothelial matrix, and

accumulation of platelet aggregates (9,10). Excessive EGF mediated cell growth are common in patients with a variety of malignancies, which is why antibody-based therapies that inhibit EGFR signaling, such as cetuximab, have been introduced. Patients treated with cetuximab are at a significantly higher risk of venous than arterial thrombosis, but studies are needed to clarify the reasons (11). Cancer is a separate risk factor for the occurrence of vascular thrombosis. Recently, there have been reported increasing number of arterial thrombotic events in cancer patients, which is associated with a 3-fold higher risk of death (12). Adverse vascular events include acute myocardial infarction or ischemia, stroke, peripheral or visceral thrombosis, which also determines the varied clinical presentation. Tumor cells can produce ligands including thrombin, adenosine diphosphate (ADP), thromboxane A<sub>2</sub>, metalloproteinases (MMPs) and TF. In response, the stimulation of platelet surface receptors (e.g., PAR-1 and PAR-4 receptors, P2Y<sub>12</sub> receptor, and thromboxane receptor) can mediate platelet activation (13,14.). In addition, cancer cells can express procoagulant factors. Tissue factor is the receptor for factor VII and site of activation of factor VII and factor VIIA. TF results in activation of coagulation cascade when it comes into contact with activated factor VIIa resulting in local generation of thrombin, the most potent platelet activator. During apoptosis of tumor cells which might be induced by chemotherapeutic agents, procoagulant factors are released and fibrinolytic are reduced such as antithrombin, proteins C and S which can lead to the development of arterial thrombosis (15).

## CONCLUSIONS

The presented clinical case demonstrates a patient with a rare tumor of the floor of the oral

cavity diagnosed late which metastasized due to delay in initial diagnosis. Cancer and antitumor therapy exert a synergistic effect on coagulation activation. Further studies are needed to elucidate the exact mechanisms by which these life-threatening events occur, as well as the need and indications for anticoagulant therapy during and after treatment in this significant group of patients. The general practitioner occupies a central role in the health care system in a number of countries and is labeled as the "gate keeper" as he is responsible for navigation of patients through the other floors of the health care system. In order to be able to perform its complex activities and successfully solve diverse health problems of its patients, it is necessary to possess specific knowledge and skills from various fields of medicine. Their acquisition has a direct relationship with the quality of practical exercises during student training. Expanding training to include simulators would help to develop and to refine the sophisticated process of diagnostic thinking and decision making. The specialization in general medicine in Bulgaria must also adapt to the specific needs of practicing in primary care. Physicians may benefit from including oral surgery topics in the training program. continuing medical education plays a significant role, but it is necessary to have personal motivation and mandatory regulations by the state as well to increase quality of health care services carried out by the general practitioners.

## Compliance with Ethics Requirements:

The author declares no conflict of interest regarding this article.

The author declares that the study was conducted in accordance with the Declaration of Helsinki. Informed consent was obtained from the patient included in the study.

No funding was received for this study.

## REFERENCES

1. Siegel R, Naishadham D, Jemal A. Cancer statistics, 2013. *Ca-Cancer J Clin.* 2013;63(1):11–30.
2. Montero PH, Patel SG. Cancer of the oral cavity. *Surg Oncol Clin N Am.* 2015;24(3):491–508.
3. Blot WJ, McLaughlin JK, Winn DM, Austin DF, Greenberg RS, Preston-Martin S, et al. Smoking and drinking in relation to oral and pharyngeal cancer. *Cancer research.* 1988;48(11):3282–7.
4. Malhotra V, Perry MC. Classical chemotherapy: mechanisms, toxicities and the therapeutic window. *Cancer Biol Ther.* 2003;2(4 suppl 1):S2–S4.
5. Nurgali K, Jagoe RT, Abalo R. Adverse effects of cancer chemotherapy: Anything new to improve tolerance and reduce sequelae?. *Front Pharmacol.* 2018;9:245.
6. Oppelt P, Bethadal A, Nayak L. Approach to chemotherapy-associated thrombosis. *Vasc Med.* 2015;20:153–61.
7. Canale ML, Bisceglia I, Lestuzzi C, Parrini I. ANMCO Cardio-Oncology Task Force. Arterial thrombosis in cancer: spotlight on the neglected vessels. *Anticancer Res.* 2019;39:4619–25.
8. Steven P G, Yohei MH, Raj SK, Reeves BN, Nigel M. Cancer Therapy–Associated Thrombosis. *Arteriosclerosis, Thrombosis, and Vascular Biology.* 2021;41:1291–305
9. Cwikiel M, Zhang B, Eskilsson J, Wieslander JB, Albertsson M. The influence of 5-fluorouracil on the endothelium in small arteries. An electron microscopic study in rabbits. *Scanning Microsc.* 1995;9:561–76.
10. Kinhult S, Albertsson M, Eskilsson J, Cwikiel M. Antithrombotic treatment in protection against thrombogenic effects of 5-fluorouracil on vascular endothelium: a scanning microscopy evaluation. *Scanning.* 2001;23:1–8.
11. Petrelli F, Cabiddu M, Borgonovo K, Barni S. Risk of venous and arterial thromboembolic events associated with anti-EGFR agents: a meta-analysis of randomized clinical trials. *Ann Oncol.* 2012;23:1672–9.

12. Navi BB, Reiner AS, Kamel H, Iadecola C, Okin PM, Elkind MSV, Panageas KS, DeAngelis LM, et al. Risk of arterial thromboembolism in patients with cancer. *J Am Coll Cardiol.* 2017;70(8):926-38
13. Mezouar S, Frère C, Darbousset R, Mege D, Crescence L. Role of platelets in cancer and cancer-associated thrombosis: Experimental and clinical evidences. *Thromb Res.* 2016;139:65-76
14. Connolly GC, Phipps RP, Francis CW. Platelets and cancer-associated thrombosis. *Semin Oncol.* 2014;41(3):302-10
15. Blann AD, Dunmore S: Arterial and venous thrombosis in cancer patients. *Cardiol Res Pract.* 2011;3:394740.