

PAPER DETAILS

TITLE: Sol Ventrikül Çikim Yolundaki Miksoma Benzeri Sklerotik Kalsifiye Kitlenin Cerrahi Tedavisi

AUTHORS: Atilla Sezgin,Hakki Tankut Akay,Bahadir Gültekin,Banu Bilezikçi

PAGES: 26-28

ORIGINAL PDF URL: <https://dergipark.org.tr/tr/download/article-file/106847>

Surgical Management of Myxoma Like Sclerotic Calcified Mass in Left Ventricle Outflow Tract

Atilla Sezgin, MD, Hakkı Tankut Akay, MD, Oktay Korun, MD, Bahadır Gültekin, MD, Banu Bilezikçi, MD*

ABSTRACT

In this short report, we present the successful surgical treatment of a patient who had an echocardiographic diagnosis of left ventricular mass during her routine controls. This patient was treated by surgical excision of the ventricular mass and after the pathological examination the diagnosis was "myxoma like sclerotic calcified mass". The postoperative course was uneventful, and the patient was discharged on day 7 of surgery. The follow-up period lasted for 2 years without any event and the echocardiograms revealed no residual or recurrent lesions. Surgical resection of intracardiac masses are necessary and safe treatment options but there is not a standardization about the type of surgical options. The localization of the mass has the key role in determining the type of the surgical approach. In this case aortotomy provided a good access and facilitated the exposure of this rare myxoma like sclerotic calcified mass.

Key Words: Myxoma, heart neoplasms, vimentin.

ÖZET

Sol Ventrikül Çıkım Yolundaki Miksoma Benzeri Sklerotik Kalsifiye Kitlenin Cerrahi Tedavisi

Bu olgu sunumunda rutin kontrolleri sırasında yapılan ekokardiografik incelemeler sırasında sol ventrikülde kitle tanısı alan hastanın başarılı cerrahi tedavisini takdim etmekteyiz. Bu hastada ventriküldeki kitle çıkarıldıktan sonra yapılan patolojik inceleme sonrasında tanı "miksoma benzeri kalsifik kitle" olarak şekillenmiştir. Ameliyat sonrası dönemi sorunsuz geçen hasta ameliyat sonrası 7. günde taburcu edilmiştir. Takip süresi 2 yıl sürmüş olup bu dönemde herhangi bir olay meydana gelmemiş ve ekokardiografik incelemede tekrarlayan ya da rezidüel bir lezyona rastlanmamıştır. İntrakardiyak kitlelerin cerrahi olarak çıkarılmaları gerekli ve güvenli yöntemlerdir ancak cerrahi seçenekler arasında bir standardizasyon mevcut değildir. Kitlenin yerleşimi cerrahi yaklaşımı belirlemede anahtar bir role sahiptir. Bu hastada aortotomi bu nadir görülen miksoma benzeri kitle için iyi bir görüş sağlamıştır.

Anahtar Kelimeler: Miksoma, kalp tümörleri, vimentin.

*Başkent University Faculty
of Medicine, Department of
Cardiovascular Surgery*

**Başkent University Faculty
of Medicine, Department
of Pathology*

*Received: June 21, 2010
Accepted: November 10, 2010*

Address for Reprints

Başkent University
Hospital, Department of
Cardiovascular Surgery
Fevzi Çakmak Cd.
10. Sk. No:45
Bahçelievler, Ankara
Telephone:
+90 312 212 68 68/1373
e-mail:
oktay_korun@hotmail.com

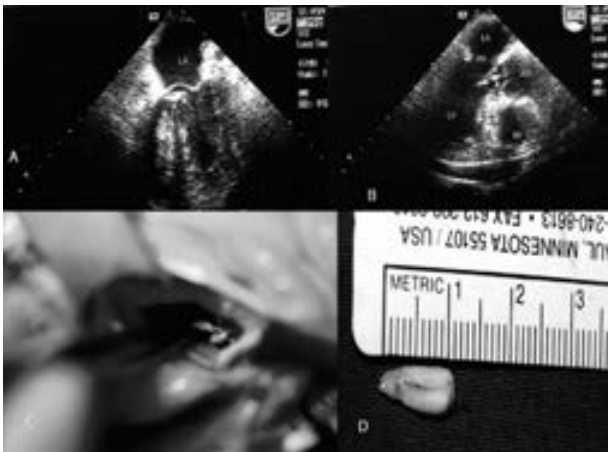
INTRODUCTION

Primary cardiac tumors are rare clinical entities with an incidence of 0.001% to 0.03% (1-3). The majority of these tumors are atrial myxomas, which can be successfully managed by surgical excision (2). Myxomas are usually localized in the left atrium (1-3). In this report we present a 58 year old female patient who had a diagnosis of left ventricular mass. She was treated by surgical excision of the mass and after the pathological examination the diagnosis was "myxoma like sclerotic calcified mass".

CASE REPORT

A 58 year old female patient was admitted to hospital for check-up controls. The patient had normal physical findings and normal biochemical parameters. Transesophageal echocardiogram revealed a 12x8x2 mm pedunculated mass in the left ventricular outflow tract (Figure 1 A, 1 B). The mass had no connection with valvular structures. Cardiac valves were functioning normally. There was no coronary artery stenosis in the coronary angiogram. After the evaluation of these data, surgical excision of the mass was planned.

Figure 1. Transesophageal Echocardiographic image of the mass. It is visible that the mass is within the left ventricle (1 A). The mass is seen on the left ventricle outflow tract (1 B). Intraoperative image of the mass (1 C). Image of the mass after the resection (1 D)



Surgical approach was through a median sternotomy in our case. Cardiopulmonary bypass was established using ascending aorta and bicaval venous cannulation. Myocardial protection was performed with cold crystalloid cardioplegic solution and topical cooling. Aorta was opened vertically and left ventricular outflow tract was evaluated. A pedunculated, solid, calcified, gray-white mass (attached to the left ventricle with a stalk with the dimensions 12x8x2mm) was detected 1.5 cm below the aortic valve, in the level of the commissure between the right and left aortic cusps. The mass was detached from the stalk when holding the mass by forceps. The re-

maining tissue was excised by shearing the stalk from the left ventricle wall (Figure 1 C, 1 D). The aortotomy was closed, and the patient was weaned off cardiopulmonary bypass without any problem. The pathologic sample was fixed 10 % formaline solution and preserved in paraffine block which was cut into serial sections of 4-5 micrometers thickness. The sections were stained by hematoxyline-eosine. Since we are interested in the origin of the lesion, we also applied immunohistochemical staining using the ABC (avidine-biotine complex) method. Deparaphinized sections were initially incubated with primary antibodies (Vimentine, monoclonal, Dako and von Willebrand factor) for 60 minutes at room temperature and the final reaction was visualized using 3,3 diaminobenzidine tetrahydrochloride (DAB). In the histopathologic examination, we observed that the lesion was consisted of mainly intense calcified hyalinized tissue. We also noted the features of granulation tissue, including numerous blood vessels. A small portion of the lesion contained myxomatous stroma interspersed with spindle shaped cells. Immunohistochemically, the cells stained positive both for vimentine and Von Willebrand factor particularly around the vessels.

The postoperative course was uneventful, and the patient was discharged home on day 7 of surgery. The follow-up period lasted for 2 years without any event and the echocardiograms revealed no residual or recurrent lesions.

DISCUSSION

Masses in the left ventricle are usually intracardiac tumors, thrombi or vegetations. Although primary tumors of the heart are rare, the myxoma is the most common benign primary heart tumor as it accounts for 0.3% of open-heart surgery (1-3). The most common localization of myxomas in the left ventricle is the left ventricle outflow tract (3). The patients with intracardiac masses can be either asymptomatic or the clinical presentations may be consisted of important hemodynamic symptoms mainly related to obstruction and embolic phenomena depending on the histologic features and localizations of these masses.

Myxomas occur in any chamber of the heart but approximately 75% originate from left atrium. The next most frequent site is the right atrium, where 10 to 20% are found. The remaining 6 to 8% are equally distributed between the left and right ventricles (4). Differential diagnoses of myxomas include thrombotic lesions and other cardiac tumors(5, 6). Myxoma comprises the majority of all benign cardiac tumors. It is followed by lipomas, papillary fibroelastomas, hemangiomas and other less common tumors. Distinguishing myxomas from calcified and fatty tumors is helpful to provide a better treatment.

The localization of the mass has the key role in determining the type of the surgical approach. Echocardi-

gram is a reliable diagnostic tool by not only providing the diagnosis but also giving opinions for the type of surgery.

Although the microscopic calcification has been reported in the histopathologic assessments of myxomas before, massive calcification is very rare (7,8). And usually the diagnosis is made coincidentally. Despite the Vimentine positivity in immunohistochemical studies in myxoma cases any mesenchymal cells can be stained by this type of colouring(7). For that reason we can not definitely comment that this mass in our patient was a myxoma. There are different results about the studies, related with endothelial markers. In some studies it is reported that myxomas are originated from the endothelium(8). On the other hand there are some studies reporting that endothelial markers are absent or present in a few of cases. According to these studies, the major component of the myxomas are the primitive mesenchymal cells which show minimal change or no change.

In our patient the gross examination of the mass caused us to diagnose the mass as a myxoma due to localization in left ventricle outflow tract, being pedunculated and fragile. The final diagnosis was myxoma like sclerotic calcified mass which is very rare because there was myxomatous stroma in a very small area despite the stain with vimentine.

Echocardiography has a key role in diagnosis. Trans-esophageal ecocardiography is especially useful since it can detect masses as small as 1 to 3 mm. Certain diagnosis is reached by the pathologic examination of the mass. Therefore the resection of the mass is important both for diagnosis and treatment. The surgical resection is the most effective treatment option because as the risk of worsened clinical courses especially presenting with manifestations due to embolus. The surgical access to these masses may vary depending on the location. In our case aortotomy approach provided a good access and facilitated the exposure of this rare myxoma like sclerotic calcified mass.

REFERENCES

1. N. Chakfe, J.G. Kretz, P. Valentin, B. Geny, H. Petit, S. Popescu et al, *Clinical presentation and treatment options for mitral valve myxoma. Ann Thorac Surg* 1997; 64 : 872-7.
2. S. Bjessmo and T. Ivert , *Cardiac myxoma: 40 years' experience in 63 patients. Ann Thorac Surg* 1997; 63 : 697-700.
3. Gurlertop Y, Yilmaz M, Erdogan F, Acikel M, Kose N. *Left Ventricular Outflow Tract Myxoma; Eur J Echocardiography* 2003;4;339-41.
4. McAllister HA, Fenoglio JJ Jr: *Tumors of the cardiovascular system, in Atlas of Tumor Pathology, Series 2. Washington, Armed Forces Institute of Pathology, 1978.*
5. *Calcified Left Ventricular Mass: Unusual Clinical, Echocardiographic, and Computed tomographic findings of primary cardiac osteosarcoma Mayo Clin. Proc.* 2000;75;743-7.

6. Özkan S, Akay T, Gültekin B, Arslan A, Sezgin A, Aşlamacı S *Intramyocardial Metastasis To The Left Ventricle From Renal Cell Carcinoma Türk Göğüs Kalp Damar Cerrahisi Dergisi.* 2005;13:249-51.

7. Schuger L, Ron N, Rosenman. *Cardiac myxoma a retrospective immunohistochemical study. Path Res Pract* 1987;182:63-6.

8. Lie JT. *Petrified cardiac myxoma masquerading as organized atrial mural thrombus Arch Pathol Lab Med* 1989;113:742-5.