

## PAPER DETAILS

TITLE: Newborn with an Intracardiac Mass Generated Secondary to Umbilical Vein Catheterization

AUTHORS: Aybala TONGUT, Ali Can HATEMI, Eylem TUNÇER, Ayse Bahar CEYRAN, Füsün

GÜZELMERİÇ, Ayse Inci YILDIRIM, Hakan CEYRAN

PAGES: 269-271

ORIGINAL PDF URL: <https://dergipark.org.tr/tr/download/article-file/595761>



# Newborn with an Intracardiac Mass Generated Secondary to Umbilical Vein Catheterization

Aybala Tongut<sup>1</sup>, Ali Can Hatemi<sup>1</sup>, Eylem Tunçer<sup>1</sup>, Ayşe Bahar Ceyran<sup>2</sup>,  
Füsün Güzelmeriç<sup>3</sup>, Ayşe İnci Yıldırım<sup>4</sup>, Hakan Ceyran<sup>1</sup>

<sup>1</sup> University of Health Sciences, Kartal Koşuyolu High Specialization Health Application and Research Center, Clinic of Pediatric Cardiovascular Surgery, İstanbul, Turkey

<sup>2</sup> İstanbul Göztepe Training and Research Hospital, Clinic of Pathology, İstanbul, Turkey

<sup>3</sup> University of Health Sciences, Kartal Koşuyolu High Specialization Health Application and Research Center, Clinic of Anesthesiology, İstanbul, Turkey

<sup>4</sup> University of Health Sciences, Kartal Koşuyolu High Specialization Health Application and Research Center, Clinic of Pediatric Cardiology, İstanbul, Turkey

## ABSTRACT

Umbilical vein catheterization is a routine procedure of neonatal intensive care units, and only rare complications associated with catheter malposition have been described in the literature. We herein present an infant boy (28 days old, 4 kg) with an intracardiac mass diagnosed after umbilical vein catheterization. The patient was referred to our clinic with a diagnosis of catheter migration and thrombosis, but this could not be confirmed during surgery. Pathological analysis of the excised intracardiac mass revealed nonbacterial thrombotic endocarditis. Our case confirms the essentiality of controlling the location of the umbilical venous catheter after its insertion.

**Key Words:** Neonate; thrombosis; umbilical venous catheter; nonbacterial thrombotic endocarditis

## Yeni Doğanda Umbilikal Ven Kateterizasyonu Malpozisyonuna Sekonder Gelişen İntrakardiyak Kitle

## ÖZET

Umbilikal ven kateterizasyonu yenidoğan yoğun bakım ünitelerinde santral venöz erişim için rutin olarak uygulanan girişimlerden biridir. Literatürde kateter malpozisyonuna sekonder gelişen nadir komplikasyonlar bildirilmiştir. Burada umbilikal ven kateterizasyonunu takiben intrakardiyak kitle tanısı ile kliniğimize yönlendirilen erkek yenidoğan bir olgu sunulmaktadır. Operasyonda kateter migrasyonu veya tromboz gözlenmezken eksize edilen intrakardiyak kitlenin patolojik tanısı nonbakteriyel trombotik endokardit ile sonuçlanmıştır. Umbilikal venöz kateterin uygun lokasyonda olduğunun kontrolü komplikasyonların önlenmesinde temel gerekliliktir.

**Anahtar Kelimeler:** Yenidoğan; tromboz; umbilikal ven kateterizasyonu; nonbakteriyel trombotik endokardit

## INTRODUCTION

Umbilical vein catheterization (UVC) is one of the easiest methods to access a central vein and is performed routinely in neonatal intensive care units. UVC is indicated in conditions when the infant is likely to require intravenous fluids/medications, parenteral nutrition, and therapeutic plasma exchange in the early postnatal period. Cardiac catheterization in the neonate via the umbilical vein with two-dimensional echocardiographic guidance has been described in the literature as an effective and safe approach<sup>(1)</sup>. However, UVC may seldom cause fatal complications, such as infection, venous thrombosis, catheter migration into the cardiac or portal system, and cardiac tamponade<sup>(2-4)</sup>.

## CASE REPORT

A 28-day-old, 4 kg, baby boy delivered by caesarean section at term from a 38-year-old mother in rural Turkey was referred to our clinic with a diagnosis of umbilical catheter migration. The mother had no complaint during pregnancy. No evidence of congenital malformations was found on her prenatal ultrasonographic examinations. There was no family history of

## Correspondence

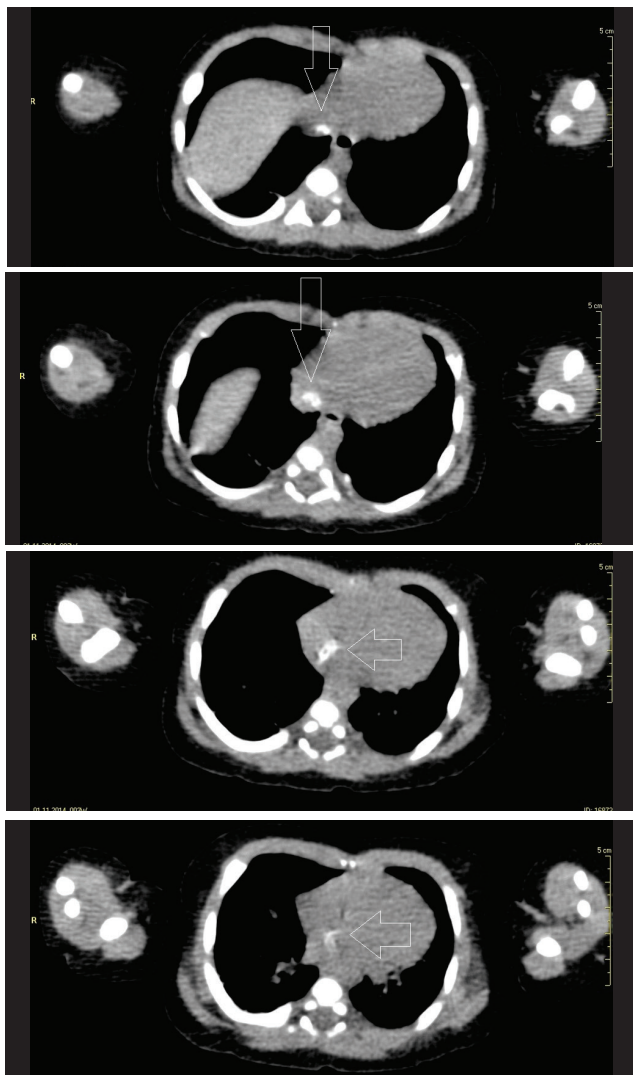
Aybala Tongut

E-mail: aybalatongut@gmail.com

Submitted: 24.12.2015

Accepted: 13.01.2016

© Copyright 2017 by Koşuyolu Heart Journal.  
Available on-line at  
www.kosuyoluheartjournal.com



**Figure 1.** Figure 1 depicts the mass extending from the inferior vena cava to the right atrium by CTA.

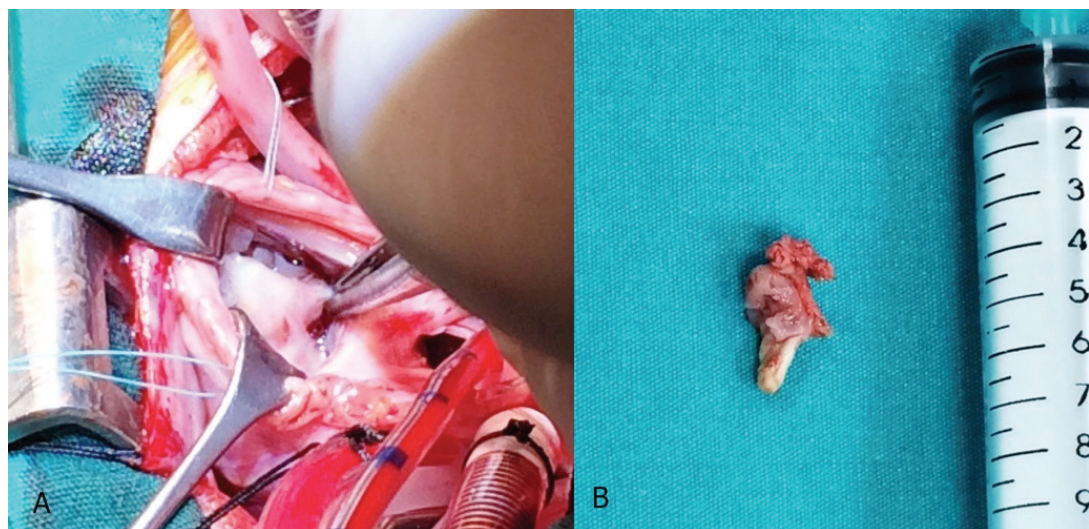
congenital heart defect. In the early postnatal period, following a sepsis diagnosis, intravenous antibiotherapy regimen was administered for 15 days by UVC. On the routine transthoracic echocardiography (TTE) after recovery, catheter migration and thrombosis was revealed. Computed tomography angiography (CTA) was performed on day 26 after birth, and the patient was referred to our clinic with suspicion of catheter migration and/or thrombosis (Figure 1). On admission, his general condition was good, and TTE revealed a mass suggestive of a thrombus or umbilical catheter migration into the right atrium, although these findings were not confirmed by an X-ray. To confirm the diagnosis and prevent potential embolic complications of the intracardiac mass, we decided to remove it.

### Surgical Procedure

Following median sternotomy, right atriotomy was performed, and a  $1 \times 1 \times 0.5$  cm solid tissue mass originating from the interatrial septum was carefully resected (Figure 2). Interatrial re-septation was accomplished with a fresh autologous pericardial patch. Following the operation, the patient was extubated on postoperative day 2 and discharged on postoperative day 10. Pathology of the intracardiac mass showed nonbacterial thrombotic endocarditis (NBTE) with vegetation consisting of calcification, which could be caused by endocardial trauma on the basis of malposition of the umbilical catheter (Figure 3).

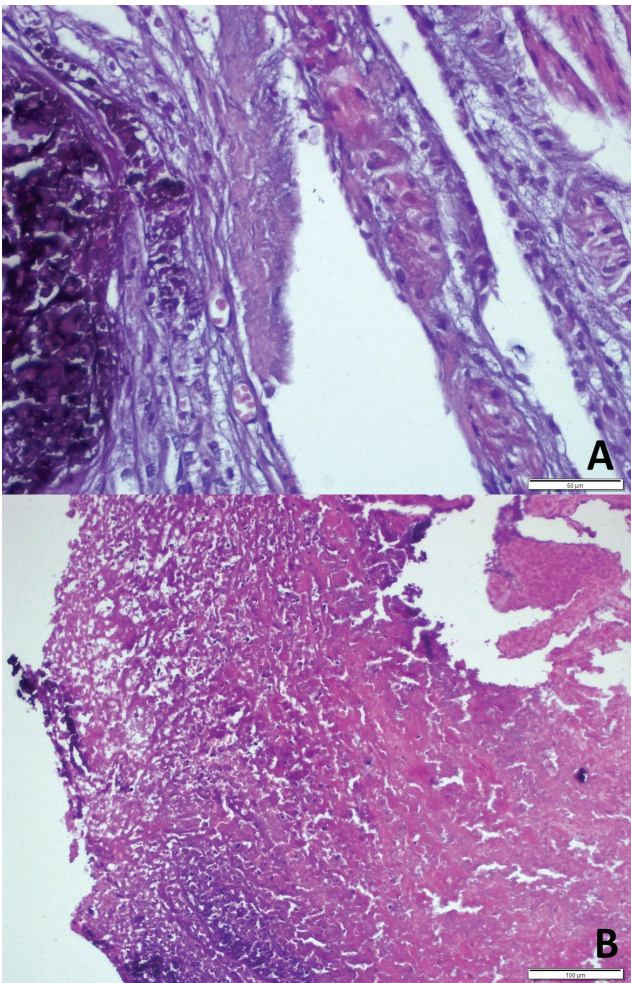
### DISCUSSION

The appropriate location for the tip of the umbilical vein catheter is typically the cephalad portion of the IVC or the IVC-RA junction. Complications due to UVC, such as necrotizing enterocolitis, portal vein thrombosis, and hepatic necrosis have been reported<sup>(4,5)</sup>. However, vegetations secondary to endocardial trauma are extremely rare<sup>(6)</sup>. Factors associated with thrombosis include endothelial damage during catheter placement, composition of the infusion solution, catheter characteristics, and the duration/location of catheter placement. Although some formulae are used to achieve the ideal position



**Figure 2.** (A,B) Operative photos show the intraoperative appearance of the mass.





**Figure 3. (A,B)** Microscopic examination of the surgical specimen nonbacterial thrombotic endocarditis (NBTE).

of the catheter, such as shoulder-umbilical length or umbilical stump-xiphisternum length, the optimal approach is utilizing ultrasound guidance or identification of its location using fluoroscopy<sup>(2,4,7)</sup>.

An umbilical vein catheter can cross the interatrial septum from the right to the left via a true atrial septal defect or, more likely, via a patent foramen ovale. These kinds of malpositions can result when the catheter is introduced by a pediatrician without imaging guidance<sup>(3)</sup>. Rare complications, including pericardial effusion, cardiac tamponade, arrhythmias, and thrombotic events, have also been reported<sup>(4,5)</sup>.

This case serves to illustrate an unusual clinical and surgical presentation of NBTE located at the interatrial septum secondary to endocardial trauma of UVC without thrombotic complication in a neonate.

NBTE is a disease characterized by the presence of intracardiac vegetations, which consist of fibrin and platelet aggregates, in the absence of inflammation or bacterial infection<sup>(8,9)</sup>. Vegetations are typically small and irregular in shape, easily friable, and

frequently a good source of emboli. Except vegetations, valvular tissues are free from pathologic processes, and inflammatory or reactive changes on valves are uncommon. NBTE has increasingly been recognized as a condition associated with an underlying disease, such as malignities, particularly mucinous adenocancer, autoimmune disorders, malnutrition, and impaired general conditions (e.g., acquired immune deficiency syndrome). NBTE is usually asymptomatic, and its ante-mortem diagnosis is possible. Correction of the underlying cause is essential for cure<sup>(8,9)</sup>.

Kim et al. reported the significant risk factors in neonates who had undergone UVC. A catheter being present for more than 6 days and intracardiac malposition of the catheter correlated with catheter-related thrombosis. The authors emphasize that the ideal position of the catheter should be assessed with imaging guidance during or after intervention of the abdomen and the chest<sup>(2)</sup>.

The main feature of this case is that the surgical findings of the mass could not be predicted as NBTE. Preoperative imaging by TTE or CTA could not indicate vegetations because of the presence of calcification and fibrosis of the endothelium in the course of the catheter, which mimicked the catheter.

In conclusion, NBTE should be considered as a benign complication related to an umbilical venous catheter of the neonate that can be successfully managed.

## REFERENCES

1. Ashfaq M, Houston AB, Gnanapragasam JP, Lilley S, Murtagh EP. Balloon atrial septostomy under echocardiographic control: six years' experience and evaluation of the practicability of cannulation via the umbilical vein. *Br Heart J* 1991;65:148-51.
2. Bothur-Nowacka J, Czech-Kowalska, Gruszfeld D, Nowakowska-Rysz M, Kosciesza A, Polnik D, et al. Complications of umbilical vein catheterisation. *Pol J Radiol* 2011;76:70-3.
3. Kim JH, Lee YS, Kim SH, Lee SK, Lim MK, Kim HS. Does umbilical vein catheterization lead to portal venous thrombosis? Prospective US evaluation in 100 neonates. *Radiology* 2001;219:645-50.
4. Schlesinger AE, Braverman RM, DiPietro MA. Neonates and umbilical venous catheters: normal appearance, anomalous positions, complications, and potential aid to diagnosis. *AJR Am J Roentgenol* 2003;180:1147-53.
5. Hermansen MC, Hermansen MG. Intravascular catheter complications in the neonatal intensive care unit. *Clin Perinatol* 2005;32:141-56.
6. Lopez JA, Ross RS, Fishbein MC, Siegel RJ. Nonbacterial thrombotic endocarditis: a review. *Am Heart J* 1987;113:773-84.
7. South M, Magnay A. Simple method for securing umbilical catheters. *Arc Child* 1988;63:750-1.
8. Mills SE, Carter D, Greenson JK, Reuter VE, Stoler MH. *Sternberg's Diagnostic Pathology Vol 1*, 50<sup>th</sup> ed. Lippincott Williams & Wilkins, 2010;1219-21.
9. Kumar V, Abbas AK, Aster JC. *Robbins and cotran pathologic basis of disease*. 9<sup>th</sup> ed. Elsevier Saunders, 2015:125.