

## PAPER DETAILS

TITLE: Prevention of intraabdominal adhesion using rifampicin alone or in combination with oxidized regenerated cellulose following ovariectomy in rats

AUTHORS: Damla Tugçe Okur, Sifanur Aydın, Sitkican Okur, Ayse Gölgeci Bedir, Ömer Tarık Orhun, Vefa Tohumcu, Serkan Yildirim, Yavuz Sağlam, Saab Elban

PAGES: 21-29

ORIGINAL PDF URL: <https://dergipark.org.tr/tr/download/article-file/4160136>

# Prevention of Intraabdominal Adhesion Using Rifampicin Alone or in Combination with Oxidized Regenerated Cellulose Following Ovariohysterectomy in Rats

Ratlarda Ovariohisterektomiye Takiben, Tek Başına veya Okside Rejenere Selüloz ile Birlikte Rifampisin Kullanılarak İntraabdominal Adezyonun Önlenmesi

Damla Tuğçe OKUR<sup>1</sup>  
Şifanur AYDIN<sup>1</sup>  
Sıtkıcan OKUR<sup>2</sup>  
Ayşe GÖLGELİ BEDİR<sup>2</sup>  
Ömer Tarık ORHUN<sup>3</sup>  
Vefa TOHUMCU<sup>1</sup>  
Serkan YILDIRIM<sup>4</sup>  
Yavuz Selim SAĞLAM<sup>4</sup>  
Şaab ELBAN<sup>1</sup>



<sup>1</sup>Department of Obstetrics and Gynecology, Faculty of Veterinary Medicine, Atatürk University, Erzurum, Türkiye.

<sup>2</sup>Department of Surgery, Faculty of Veterinary

<sup>3</sup>Medicine, Atatürk University, Erzurum, Türkiye.

<sup>4</sup>Department of Surgery, Faculty of Veterinary Medicine, Necmettin Erbakan University, Konya, Türkiye.

<sup>4</sup>Department of Pathology, Faculty of Veterinary Medicine, Atatürk University, Erzurum, Türkiye.



Geliş Tarihi/Received :21.08.2024  
Kabul Tarihi/Accepted :04.12.2024  
Yayın Tarihi/Publication Date :17.03.2025

Sorumlu Yazar/Corresponding author:

Damla Tuğçe Okur

E-mail: damla.tugce.okur@gmail.com

Cite this article: Okur, D. T., Aydın, Ş., Okur, S., Gölge Bedir, A., Orhun, Ö. T., Tohumcu, V., Yıldırım, S., Sağlam, Y. S., Elban, Ş. (2025). Prevention of Intraabdominal Adhesion Using Rifampicin Alone or in Combination with Oxidized Regenerated Cellulose Following Ovariohysterectomy in Rats. *Journal of Laboratory Animal Science and Practices*, 5(1), 21-29.

<https://doi.org/10.62425/jlasp.1536699>



Content of this journal is licensed under a Creative Commons Attribution-Noncommercial 4.0 International License.

## ABSTRACT

The objective of this study was to assess the efficacy of rifampicin, administered either alone or in combination with Surgicel (a oxidised regenerated cellulose-based product), in preventing the formation of intra-abdominal adhesions following ovariohysterectomy (OVH) in a rat model. Thirty-two female Wistar rats underwent OVH and were randomly assigned to one of four groups: a control group (C) treated with saline, a Surgicel application group (S), a rifampicin group (R), and a combination group receiving both Surgicel and rifampicin (S+R). Adhesion formation was assessed macroscopically and histopathological on postoperative day 28. In addition, immunohistochemical staining for Tumor necrosis factor alpha (TNF- $\alpha$ ) and immunofluorescent staining for Vascular endothelial growth factor (VEGF) were performed to assess inflammatory and angiogenic responses, respectively. Macroscopic and histopathological evaluations revealed that rifampicin (R) significantly reduced the severity and extent of adhesion formation compared to the control group. Interestingly, the S group exhibited adhesion rates comparable to the control, while the S+R group showed a moderate reduction in adhesions. Immunohistochemical and immunofluorescent findings supported the macroscopic observations, suggesting that rifampicin may attenuate the inflammatory and fibrogenic responses associated with adhesion formation. Rifampicin alone was found to be effective in reducing the formation and severity of intra-abdominal adhesions following OVH. The combination of Surgicel and rifampicin did not provide a synergistic effect, as Surgicel alone did not demonstrate a significant impact in preventing adhesions. These findings suggest that while Surgicel may be beneficial for hemostasis, caution is warranted due to its potential contribution to adhesion formation. Further research is needed to elucidate the pharmacokinetic and cellular mechanisms by which rifampicin may inhibit adhesion formation following abdominal surgery.

**Keywords:** Intraabdominal adhesions, Ovariohysterectomy, Postoperative complications, Rat model, Rifampicin, Surgicel.

## Öz

Bu çalışmanın amacı, tek başına veya okside rejenere selülozdan yapılan Surgicel ile birlikte uygulanan rifampisin, ovariohisterektomi (OVH) sonrası postoperatif intraabdominal adezyonları önlemedeki etkinliğini bir rat modelinde değerlendirmektir. Otuz iki dişi Wistar rata OVH uygulandı ve rastgele dört gruba ayrıldı: serum fizyolojik ile tedavi edilen bir kontrol grubu (C), Surgicel uygulama grubu (S), rifampisin uygulama grubu (R) ve hem Surgicel hem de rifampisin alan bir kombinasyon grubu (S+R). Yapışıklıkların gelişimi postoperatif 28. günde makroskopik ve histopatolojik olarak değerlendirilmiştir. Ayrıca, enflamatuar ve anjiyojenik yanıtları değerlendirmek için sırasıyla Tümör nekroz faktörü alfa (TNF- $\alpha$ ) için immünohistokimyasal boyama ve Vasküler endotelial büyüme faktörü (VEGF) için immünofloresan boyama yapılmıştır. Makroskopik ve histopatolojik değerlendirmeler, rifampisin uygulamasının (R) kontrole kıyasla adezyon oluşumunun yoğunluğunu ve şiddetini önemli ölçüde azalttığını ortaya koymuştur. Surgicel grubundaki adezyon skoru kontrol grubuna benzer orandayken, S+R grubunda adezyon ise orta düzeyde bir azalma göstermiştir. İmmünohistokimyasal ve immünofloresan bulgular makroskopik gözlemleri destekleyerek rifampisin adezyon oluşumuyla ilişkili enflamatuar ve fibrojenik yanıtları hafifletebileceğini göstermiştir. Rifampisin tek başına OVH sonrası karın içi yapışıklıkların oluşumunu ve şiddetini azaltma konusunda etkili olduğu gözlemlenmiştir. Surgicel ve rifampisin kombinasyonu sinerjik bir etki yaratmamıştır, çünkü tek başına Surgicel uygulaması yapışıklıkların önlenmesinde önemli bir etki göstermemiştir. Bu bulgular, Surgicel'in hemostaz için faydalı olmakla birlikte, adezyon oluşumuna potansiyel katkısı nedeniyle dikkatli olunması gerektiğini göstermektedir. Rifampisin abdominal cerrahi sonrası adezyon oluşumunu engelleyebileceği farmakokinetik ve hücresel mekanizmaların aydınlatılması için daha fazla araştırma yapılması gerekmektedir.

**Anahtar kelimeler:** İntraabdominal adezyon, Ovariohisterektomi, Postoperatif komplikasyonlar, Rat modeli, Rifampisin, Surgicel.

## Introduction

Adhesion formation is an inevitable outcome of any inflammatory condition or surgical intervention that causes damage to the peritoneum (Fatehi Hassanabad et al., 2021; Alonso et al., 2014). Despite the significant improvements achieved with surgical techniques, the issue of postoperative intraabdominal adhesion remains a chronic problem that has a substantial impact on surgical results and the quality of life of patients (Sirovy et al., 2023).

Ovariohysterectomy (OVH) is a preferred method for sterilization and treatment of various ovarian-uterine diseases, such as ovarian cysts, pyometra, neoplasms, and uterine rupture (Marvel, 2022; Rabbani, et al., 2023). Although OVH is a commonly performed procedure worldwide, it can result in serious complications including peritoneal adhesions (Demirel and Acar, 2019). The formation of intraabdominal adhesions, trauma to the serosa, inflammation following surgery on ischemic tissues, infection, and peritoneal damage caused by foreign substances are frequently observed outcomes (Akinrinmade et al., 2010; Ghobrial, et al., 2023). Intraabdominal adhesions, which are bands of fibrous tissue that form between the peritoneal surfaces of intraabdominal organs and/or the body wall, consist of cells and blood vessels and are subject to constant modification via complex signalling pathways (Alonso et al., 2014). The pathophysiology of adhesions, although not fully understood, is believed to stem from abnormal peritoneal healing, characterized by the secretion of an extensive extracellular matrix by fibroblasts in response to various cellular signals. These fibrous bands link abdominal organs or connect organs to the peritoneum, thereby disrupting the physiological movement of internal organs and often leading to severe clinical complications (Fu et al., 2005).

Several methods have been used to prevent the formation of postoperative adhesions, including minimizing tissue damage, eliminating fibrin, and inhibiting fibroblastic activity at the surgical site. Additionally, a wide range of agents, such as non-steroidal anti-inflammatory drugs, statins, metformin, aromatase inhibitors, fibrinolytic agents, corticosteroids, gonadotropin-releasing hormone agonists, and human amniotic membrane, have been investigated for the prevention of postoperative adhesions (Güney et al., 2017).

*Journal of Laboratory Animal Science and Practices*

Prophylactic adherence to appropriate local and systemic antibiotic use is crucial, as postoperative infections can lead to serious side effects such as delayed wound healing and increased risk of postoperative adhesion formation (Slatter, 2003). Rifampicin is a potent antibiotic predominantly employed in treating tuberculosis infections, both active and latent, as well as other diseases. It functions by inhibiting bacterial RNA synthesis, thereby impeding their growth and reproduction. As a local antibacterial agent, rifampicin is commonly administered after both major and minor surgery procedures to reduce the risk of wound infection (Falagas et al., 2005). Prevention of both minor and major intraabdominal hemorrhage is vital due to its potential to cause serious complications and fatalities post-surgery. To this end, meticulous maintenance of hemostasis during surgical operations is essential. Various methods, including the use of mechanical or thermal instruments and topical hemostatic agents, are employed to mitigate postoperative bleeding (Mavigök et al., 2019). Oxidized regenerated cellulose, commercially known as Surgicel, is a topical, absorbable hemostatic agent widely used to arrest bleeding and to prevent tissue adhesion (Ates et al., 2008; Zhang et al., 2015). Surgicel, a cellulose-based product, forms a gelatinous mass upon contact with blood, thereby facilitating clotting and is applied at the site of bleeding during surgery to reinforce hemostasis (Zhang et al., 2015).

Despite the widespread postoperative use of rifampicin and Surgicel, there remains a paucity of studies investigating the effects of these agents, both independently and in combination, on the development of postoperative adhesions. Therefore, this study aimed to evaluate the impact of rifampicin, either alone or concomitantly with Surgicel, on the formation of postoperative intraabdominal adhesions in rats following OVH.

## Methods

### Animals

Thirty-two female Wistar rats (average weight of 250 g) were obtained from the Medical Experimental Application and Research Center of Atatürk University for the current study. The animals were housed five per standard cage and were acclimated for one week prior to the beginning of the study. The rats were maintained under a humidity range of 40 to 60% and a constant temperature of  $22 \pm 2^\circ\text{C}$  with a 12:12h light:dark cycle. They were fed commercial chow

and water ad libitum. Atatürk University Local Board of Ethics Committee for Animal Experiments approved the experimental protocol (Protocol Date: 26.03.2024-Number: 66/3).

### Experimental Groups

Rats were randomly assigned to one of four groups, with eight animals each: C group (intraabdominal lavage following OVH with saline solution at the same dose as rifampicin administration), S group (Surgicel was applied following OVH), R group (rifampicin was administered following OVH), and S+R group.

**C Group:** The rats in this group (n=8), which was considered as the control group, were given only saline (1 mL) into the peritoneum before the last suture application while closing the abdominal region immediately after the operation.

**S Group:** In this group of rats (n=8), 2 × 1 cm absorbable hemostatic oxidised regenerated cellulose patch (PAHACEL®) (Altaylar Medikal, Ankara, Türkiye) was placed over the incision.

**R Group:** In this group of rats (n=8), 1 mL rifampicin SV (RIF; Koçak Farma, Türkiye, 125 mg/kg) was sprayed on the incision before the final suture application while closing the abdominal region immediately after OVH operation.

**S + R Group:** In rats in this group (n=8), 1 ml of rifampicin SV (RIF; Koçak Farma, Türkiye, 125 mg/kg) was instilled on 2 × 1 cm absorbable haemostatic oxidised regenerated cellulose and placed on the incision site before the final suture application while closing the abdominal region immediately after the OVH operation.

### Surgery

Rats were anaesthetised with an intramuscular injection of ketamine (Ketalar; Eczacibasi, Istanbul, Turkey, 50 mg/kg) and xylazine HCl (Rompun; Bayer Türk İlaç Ltd., Istanbul, Turkey, 10 mg/kg). The posterior abdominal region was sterilized, and a 2 cm midline incision was performed. The uterus was located just beneath the bladder, posterior to the colon. Following one of the uterine horns, the corresponding ovary was reached. The ovarian ligaments and the uterine suspensors were ligated and excised via blunt dissection. The ovary and uterus were subsequently removed according to standard surgical protocols. The abdominal wall was then closed with 3-0 silk sutures, completing the procedure. On postoperative day 28, the rats were euthanized, and the development of adhesions was evaluated via a second-look laparotomy through the

original incision.

### Macroscopic evaluation and adhesion score

On day 28 all rats were slaughtered using a lethal dose of sodium pentobarbital. Subsequently, an inverted U-shaped incision was created to access the abdominal cavity. The severity of intraabdominal adhesions was assessed by two pathologists. The degree of adhesion was scored as follows: grade 0 indicates no adhesions; grade 1 signifies thin filmy adhesions; grade 2 represents thick adhesions in a limited area; grade 3 denotes widespread thick adhesions; and grade 4 indicates grade 3 adhesions along with adherence of visceral organs to the abdominal wall (Zheng et al., 2013).

### Histopathological Evaluation

Peritoneal specimens from ovariectomized rats were fixed in a 10% formaldehyde solution for 48 hours and then subjected to routine tissue processing before being embedded in paraffin blocks. Sections of 4 µm thickness were cut from each block, and the prepared slides for histopathological examination were stained with hematoxylin and eosin (H&E). Light microscopy examination was performed using an Olympus BX 51 microscope (Japan). The histopathologic characteristics of the sections were graded as absent (-), mild (+), moderate (++), and severe (++++).

### Immunohistochemical Evaluation

For immunoperoxidase staining, tissue sections mounted on poly-L-lysine-coated slides were deparaffinized and rehydrated. Endogenous peroxidase activity was quenched with 3% hydrogen peroxide (H<sub>2</sub>O<sub>2</sub>) for 10 minutes. The sections were then subjected to antigen retrieval by boiling in a 1% citrate buffer solution (pH 6.1, 100X) and subsequently allowed to cool to room temperature. To reduce nonspecific background staining, sections were treated with a protein block for 5 minutes. The primary antibody against TNF-α (Cat No: sc-52746, dilution 1:100, Santa Cruz Biotechnology, USA) was then applied to the tissues and incubated following the manufacturer's protocol. Visualization was achieved using 3,3'-diaminobenzidine (DAB) as the chromogen. Light microscopy examination of the stained sections was performed using a Zeiss AXIO microscope (Germany).

### Immunofluorescence Evaluation

For immunofluorescence analysis, tissue sections affixed to poly-L-lysine-coated slides were deparaffinized and

rehydrated. Endogenous peroxidase activity was blocked using 3% H<sub>2</sub>O<sub>2</sub> for 10 minutes. The tissues were then heated in a 1% antigen retrieval solution (citrate buffer, pH 6.1, 100X) and allowed to cool to room temperature. Sections were incubated with a protein block for 5 minutes to minimize nonspecific background staining. The primary antibody against VEGF (Cat No: sc-7269, dilution 1:100, Santa Cruz Biotechnology, USA) was applied to the tissues and incubated as per the manufacturer's instructions. The sections were then incubated with a FITC-conjugated secondary antibody (Cat No: ab6785, dilution 1:1000) in the dark for 45 minutes. Following this, sections were counterstained using DAPI (Cat No: D1306, dilution 1:200, UK) in mounting medium for 5 minutes and covered with coverslips; all steps were performed while avoiding light exposure. Fluorescence microscopy was conducted using a Zeiss AXIO microscope with a fluorescence attachment (Germany).

### Statistical Analysis

Statistical analyses for the histopathological examinations were conducted using the GraphPad Prism version 8.0.2 software (San Diego, CA, USA), with a p-value of less than 0.05 considered indicative of statistical significance. The nonparametric Kruskal-Wallis test was employed to assess the differences between groups, while the Mann-Whitney U test was utilized for pairwise comparisons.

For quantifying the intensity of positive staining from immunohistochemical and immunofluorescence images, five random fields from each image were selected and analyzed using the ZEISS Zen Imaging Software. Statistical results were expressed as means and standard deviations (mean±SD) for the percentage of the area with positive staining. Normal distribution of the data was tested using Shapiro-Wilk test. One-way ANOVA, followed by the Tukey post hoc test, was performed to compare the proportion of immunoreactive cells and immunopositively stained areas against healthy control samples.

## Results

### Macroscopic Findings

After twenty-eight days following the surgery, the rats were sacrificed to determine the adhesion scores. Table 1 shows the varying adhesion scores in each group. Significant differences were found between the R and C, S

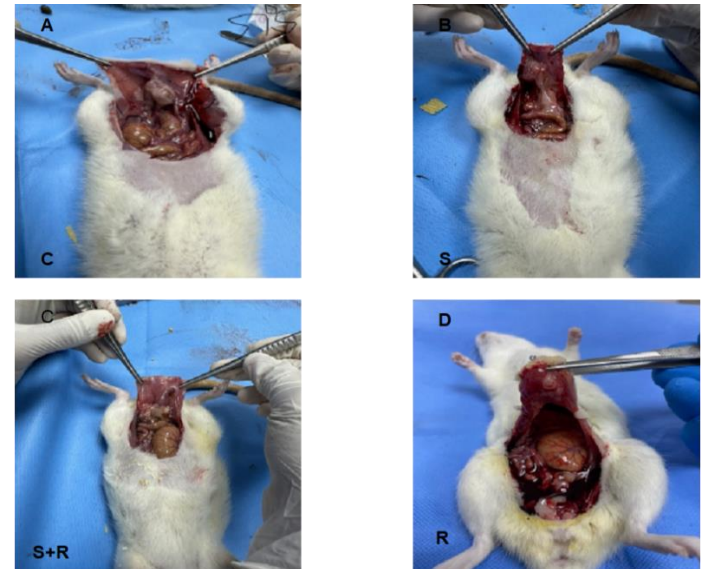
groups ( $p=0.022$  and  $p= 0.017$ , respectively, Table 1). However, no significant difference was observed between R and S + R group, and S and C group ( $p= .25$  and  $p= .32$ , respectively, Table 1, Figure 1).

**Table 1.** Macroscopic evaluation of adhesion score in Control (C), Surgicel (S), Rifampicin (R), and Rifampicin + Surgicel (R + S) groups.

**Table 1.** Kontrol (C), Surgicel (S), Rifampicin (R) ve Rifampicin + Surgicel (R + S) gruplarında yapışma skorunun makroskopik değerlendirmesi.

Groups	Adhesion score
C	3 (3-4) <sup>a</sup>
S	3 (2-4) <sup>a</sup>
R	1 (0-3) <sup>b</sup>
R + S	3 (2-4) <sup>ab</sup>

Different letters indicate significant difference between groups ( $p < .05$ ). Data are expressed as median (range).



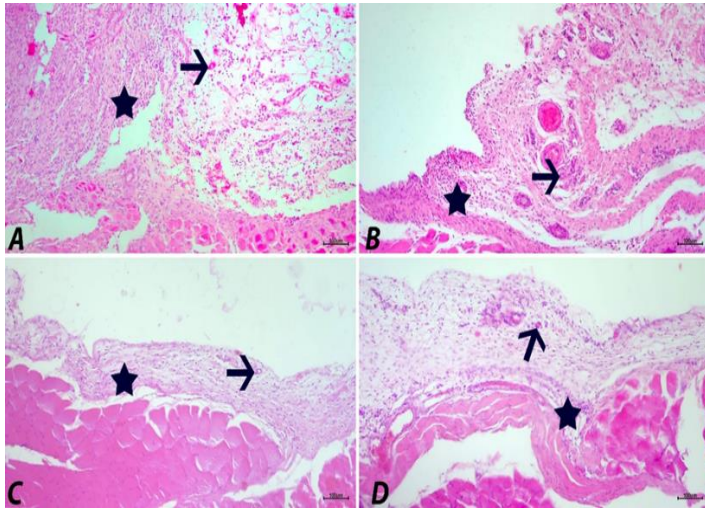
**Figure 1:** The macroscopic appearance of adhesion formation during and after twenty eight day. C group (A), S group (B), S + R (C) group, and R group (D).

**Şekil 1:** Yirmi sekiz gün boyunca ve sonrasında adezyon oluşumunun makroskopik görünümü. C grubu (A), S grubu (B), S + R (C) grubu ve R grubu (D).

### Histopathologic Findings

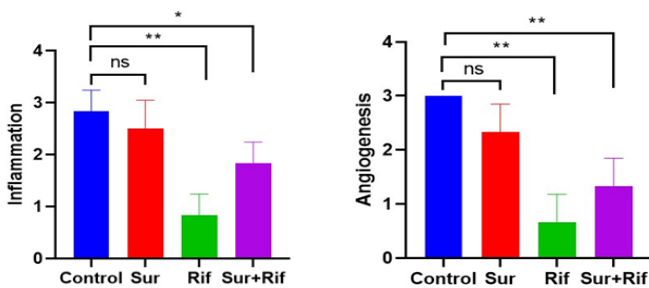
All procedures in the study were successfully completed without complications, and all findings were evaluated in a blinded manner by two pathologists. After the experimental induction of intraabdominal adhesions,

peritoneal tissue in the control (C) and Surgicel (S) groups showed severe oedematous thickening, inflammation, and angiogenesis, whereas the rifampicin (R) group exhibited only mild manifestations of these pathologies. The combination group (S + R) demonstrated moderate oedematous thickening, inflammation, and angiogenesis (Figure 2). The data and statistical analysis results of the histopathological findings are presented in Figure 3.



**Figure 2.** Peritoneum, C group (A), S group (B), R group (C) and S+R group (D). Angiogenesis (arrows) and inflammation (asterisks), H&E, Bar: 100 $\mu$ m.

**Şekil 2.** Periton, C grubu (A), S grubu (B), R grubu (C) ve S+R grubu (D). Anjiyogenez (oklar) ve inflamasyon (yıldız işaretleri), H&E, Bar: 100 $\mu$ m.



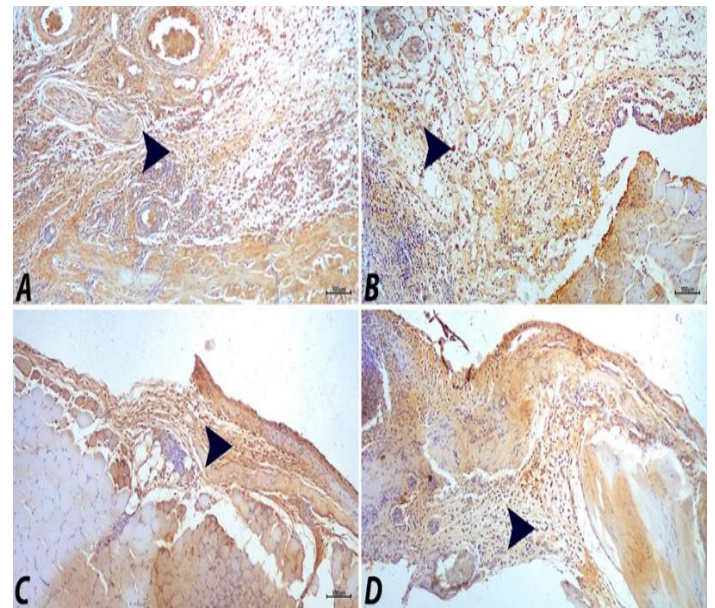
**Figure 3:** Histopathological findings and statistical analysis data in peritoneal tissue. Inflammation: (ns  $p = .5455$ , \*  $p = .0130$ , \*\*  $p = .0022$ ); Angiogenesis: (ns  $p = .0606$ , \*\*  $p = .0022$ , ns: no standard difference)  $n = 6$ .

**Şekil 3:** Periton dokusunda histopatolojik bulgular ve istatistiksel analiz verileri. İnflamasyon: (ns  $p = .5455$ , \*  $p =$

.0130, \*\*  $p = .0022$ ); Anjiyogenez: (ns  $p = .0606$ , \*\*  $p = .0022$ , ns: standart fark yok)  $n = 6$ .

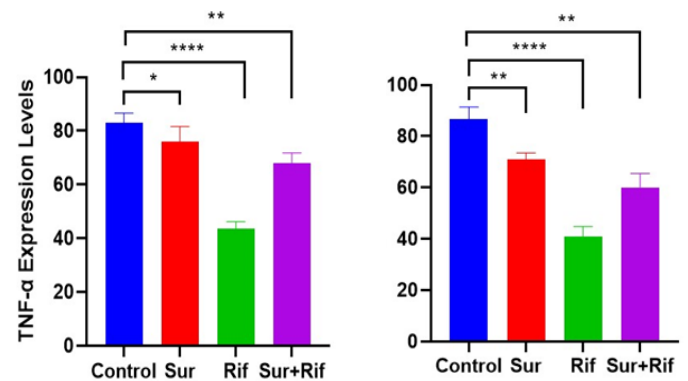
### Immunohistochemical Findings

Following the experimental induction of intraabdominal adhesions, peritoneal tissues exhibited varying levels of intracytoplasmic TNF- $\alpha$  expression. Severe expression was observed in the control (C) and Surgicel (S) groups, while the rifampicin (R) group displayed only mild expression. The combination group (S + R) showed moderate intracytoplasmic TNF- $\alpha$  expression (Figure 4). The corresponding data and the results of the immunohistochemical analysis are presented in Figure 5.



**Figure 4:** Peritoneum, C group (A), S group (B), R group (C) and S+R group (D). Intracytoplasmic TNF- $\alpha$  expression in inflammatory cells (arrowheads), IHC-P, Bar: 100 $\mu$ m.

**Şekli 4:** Periton, C grubu (A), S grubu (B), R grubu (C) ve S+R grubu (D). İnflamatuvar hücrelerde intrasitoplazmik TNF- $\alpha$  ekspresyonu (ok başları), IHC-P, Bar: 100 $\mu$ m.



**Figure 5:** Immunohistochemical and immunofluorescence findings and statistical analysis data in peritoneal tissue. TNF-a (\*  $p = .0230$ , \*\*  $p = .0012$ , \*\*\*\*  $p < .0001$ ), VEGF (\*\*  $p = .0038$  (Cont vs Sur), \*\*  $p = .0015$  (Cont vs Sur+Rif), \*\*\*\*  $p < .0001$ )  $n = 10$ .

**Şekil 5:** Periton dokusunda immünohistokimyasal ve immünofluorans bulguları ve istatistiksel analiz verileri. TNF-a (\*  $p = .0230$ , \*\*  $p = .0012$ , \*\*\*\*  $p < .0001$ ), VEGF (\*\*  $p = .0038$  (Cont vs Sur), \*\*  $p = .0015$  (Cont vs Sur+Rif), \*\*\*\*  $p < .0001$ )  $n = 10$ .

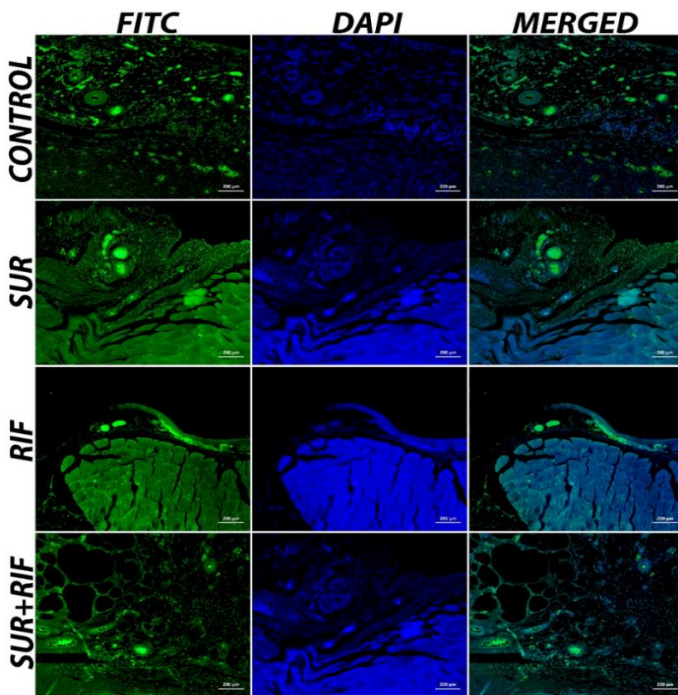
### Immunofluorescence Findings

Following the experimental induction of intraabdominal adhesions, the peritoneal tissue demonstrated severe VEGF expression in the control (C) and Surgicel (S) groups. In contrast, the rifampicin (R) group exhibited mild VEGF expression, while the combination group (S + R) showed moderate VEGF expression (Figure 6). The data and results of the statistical analysis for the immunofluorescence staining are presented in Figure 5.

intraabdominal adhesion in rats undergoing OVH. The study showed that rifampicin may decrease the intensity and quantity of adhesion development in rat following OVH.

Multiple compounds are used to prevent postoperative abdominal adhesions, but appropriate adhesion barriers must not harm peritoneal mesothelial cells, accelerate peritoneal wound healing, be absorbed in an optimal time frame (within 48-72 hours), be applied in the specified dose, and provide separation between surfaces (Aysan et al., 2005).

Oxidized regenerated cellulose (ORC) based hemostatic materials have gained popularity in several surgical fields because to their ease of use, biocompatibility, bactericidal effects, and tissue absorption (Franceschini, 2019). The effectiveness of ORC in preventing adhesions has been consistently shown in randomized controlled trials conducted in both animals and humans (Larsson, 1996; Mais et al., 1995). Surgicel is a commercial product made of ORC that is sold and used as a hemostatic agent in many surgical fields (Gray et al., 2001). Surgicel prevents adhesion formation by transforming into a gelatinous mass that covers damaged peritoneal surfaces. Under these conditions, degradation by hydrolysis takes around 28 days and provides an effective coating over the damaged area throughout the first healing stage (Ates et al., 2008). However, although Surgicel is expected to have anti-adhesion effects, it was found to be as effective as the control group in our adhesion score study. Previous studies have shown that Surgicel is not effective in preventing adhesions in animal models (Nishimuta et al., 1983; Shimanuki et al., 1987) Many animal studies with different methodologies and results have been conducted to determine the effects of Surgicel on adhesion development in experimental rat models. McGaw et al. (1988) sacrificed all rats on the 7th day post-operation and reported that the use of Surgicel reduced the formation of abdominal adhesions, whereas Hoffman et al. (2009) reported that both the Surgicel group and the control group had similar adhesion scores. Güney et al. (2017) reported that the development of pelvic adhesions was significantly higher in the Surgicel group compared to the control group over a period of 14 days in rats. In a previous study (Yavuz et al., 2021) has reported that to better determine the effectiveness of Surgicel in preventing adhesion, analysis should be conducted on the 28th day after the experimental surgery.



**Figure 6:** VEGF expression in peritoneal, vascular endothelial cells (FITC), IF, Bar: 200µm.

**Şekil 6:** Peritoneal, vasküler endotelial hücrelerde VEGF ekspresyonu (FITC), IF, Bar: 200µm.

### Discussion

The present study assessed the effects of rifampicin alone or in combination with Surgicel on postoperative

The findings of our study were inconsistent with the results of previous studies (Güney et al., 2017; McGAW et al., 1988). These differences may be explained by examining the impact of Surgicel on the OVH procedure by postoperative day 28. Surgicel undergoes complete hydrolysis within 28 days, after which its adhesion-inhibiting properties diminish (Ates et al., 2008). Reports indicate that Surgicel is fully absorbed and disappears from the body within 2-6 weeks (Barnard et al., 2009; Tompeck et al., 2020). Considering that studies evaluating the adhesion-preventive effects of Surgicel (McGAW et al., 1988) were conducted before the 28-day postoperative mark, there may be a risk of false positive outcomes. Surgicel inhibits adhesion formation by forming a gelatinous mass that coats injured surfaces, a process effective for up to 28 days. The carboxyl groups on oxidized cellulose can lower the pH when applied to bleeding sites, acting as a scaffold for solid fibrin clot formation (Zhang et al., 2020). Although this acidic environment offers potential benefits such as antimicrobial properties and enhanced clotting, it also presents challenges like the deactivation of clotting factors, increased local inflammation, and delayed healing (Pereira et al., 2018). Acidification prompts mesothelial cells to increase the production of plasminogen activator inhibitor type-1 (PAI-1) (Bergström et al., 2006), the primary inhibitor of tissue plasminogen activator in the peritoneal cavity. Elevated PAI-1 levels hinder fibrin breakdown, potentially increasing postoperative adhesion formation (Falk et al., 2001). Based on our findings, Surgicel may exhibit proliferative and inflammatory effects following the early phase, when its adhesion-protective properties have been noted in previous studies.

Rifampicin is a commonly used local antibiotic due to its broad spectrum, excellent tissue penetration, and low side effect profile (Suresh et al., 2023). In our study, it was determined that rifampicin alone slows down or halts the formation of adhesion and prevents the adhesions from reaching maturity. Together with the adhesion score, the data showed that rifampicin was useful in preventing adhesion. In previous years, studies have been conducted showing that Rifampicin reduces adhesion. Our results align with previous research indicating that rifampicin effectively inhibited adhesion in the context of preventing intraabdominal infections (Jallouli et al., 2009; Ergin et al., 2017). Although S + R group is in the middle level of preventing adhesion, it may be due to the fact that RIF treats adhesions caused by inflammation and foreign body reaction induced by Surgicel, which increases the severity

and extent of adhesions. Antibiotics prevent bacteria from sticking to animal cells by either stopping the production of adhesion molecules on the bacterial surface or changing bacterial protein production to disrupt their capacity to bind to receptors on animal cells (Lorian et al., 1987). Rifampicin has been suggested to prevent adhesion in both groups by triggering this mechanism. We hypothesize that rifampicin decreases collagen production and inhibits fibroblast proliferation, hence slowing down or halting adhesion formation (Oncel et al., 2001).

This study focuses on examining the adhesion promotion or inhibition of these products at a single point across time. The 28th day was chosen to evaluate adhesions in these models, since the effect of surgery ends after 4-6 weeks. A more comprehensive study might be planned to evaluate adhesions at different time intervals, such as on the 7th day, which is often recognized as a standard time frame. More pharmacokinetic and cellular studies are needed to determine the clinical use of rifampicin and/or Surgicel in preventing adhesion formation.

### Conclusion

Overall, the findings obtained from macroscopic evaluations, immunohistochemistry, immunofluorescence, and adhesion scores were consistent with each other. Although the intraoperative and postoperative advantages of Surgicel are undeniable, the results of this study have shown that these materials should be used judiciously considering the risks they may pose. Furthermore, when used to prevent infectious formation rifampicin during OVH and other intraabdominal gynaecological operations, it may potentially limit adhesion formation.

**Ethics Committee Approval:** Ethics committee approval was received for this study from the ethics committee of Ataturk University (Protocol Date: 26.03.2024- Number: 66/3).

**Peer-review:** Externally peer-reviewed.

**Author Contributions:** DTO: Writing – original draft, Visualization, Methodology, Investigation, Formal analysis. ŞA, SY, YSS: Visualization, Investigation, Supervision. SO, AG, ÖTO: Writing – review & editing, Formal analysis, Validation ŞE, VT: Conceptualization, Validation, Supervision, Investigation

**Declaration of Interests:** The authors declare that they have no competing interest.

**Funding:** The authors declared that this study has received no financial support.

### References

Akinrinmade, J. F., & Lawal, A. O. (2010). Gross and histologic evaluation of abdominal adhesions associated



- with chromic catgut and polypropylene sutured enteropexies in dog. *International Journal of Morphology*, 28(4), 1221-1225. DOI:10.4067/S0717-95022010000400037
- Alonso, J. D. M., Alves, A. L. G., Watanabe, M. J., Rodrigues, C. A., & Hussni, C. A. (2014). Peritoneal response to abdominal surgery: The role of equine abdominal adhesions and current prophylactic strategies. *Veterinary Medicine International*, 2014(1), 279730. <https://doi.org/10.1155/2014/279730>
- Ates, U., Ata, B., Ortakuz, S., Seyhan, A., & Urman, B. (2008). Prevention of adhesion formation following ovarian surgery in a standardized animal model: Comparative study of Interceed and double layer Surgicell. *Journal of Obstetrics and Gynaecology Research*, 34(1), 12-17. <https://doi.org/10.1111/j.1447-0756.2007.00684.x>
- Aysan, E., Demir, M., Kinaci, E., & Basak, F. (2005). Complications of intestinal milking: Experimental model. *ANZ Journal of Surgery*, 75(5), 322-325. <https://doi.org/10.1111/j.1445-2197.2005.03307.x>
- Barnard, J., & Millner, R. (2009). A review of topical hemostatic agents for use in cardiac surgery. *The Annals of Thoracic Surgery*, 88(4), 1377-1383. <https://doi.org/10.1016/j.athoracsur.2009.02.092>
- Bergström, M., Falk, P., & Holmdahl, L. (2006). Effect of acidosis on expression of mesothelial cell plasminogen activator inhibitor type-1. *Surgical Endoscopy*, 20, 1448-1452. DOI: 10.1007/s00464-005-0283-6
- Demirel, M. A., & Acar, D. B. (2012). Ovarian remnant syndrome and uterine stump pyometra in three queens. *Journal of Feline Medicine and Surgery*, 14(12), 913-918. <https://doi.org/10.1177/1098612X12451373>
- Ergin, İ., & Demirel, M. A. (2017). Kedi ve Köpeklerde Abdominal Cerrahi ve Jinekolojik Operasyonlar Sonrası İntra-Abdominal Adezyon Oluşumu ve Medikal Olarak Önlenmesi. *Erciyes Üniversitesi Veteriner Fakültesi Dergisi*, 14(1), 61-72.
- Falagas, M. E., & Vergidis, P. I. (2005). Irrigation with antibiotic-containing solutions for the prevention and treatment of infections. *Clinical Microbiology and Infection*, 11(11), 862-867. <https://doi.org/10.1111/j.1469-0691.2005.01201.x>
- Falk, K., Björquist, P., Strömqvist, M., & Holmdahl, L. (2001). Reduction of experimental adhesion formation by inhibition of plasminogen activator inhibitor type 1. *British Journal of Surgery*, 88(2), 286-289. <https://doi.org/10.1046/j.1365-2168.2001.01647.x>
- Fatehi Hassanabad, A., Zarzycki, A. N., Jeon, K., Dundas, J. A., Vasanthan, V., Deniset, J. F., & Fedak, P. W. (2021). Prevention of post-operative adhesions: A comprehensive review of present and emerging strategies. *Biomolecules*, 11(7), 1027. <https://doi.org/10.3390/biom11071027>
- Franceschini, G. (2019). Internal surgical use of biodegradable carbohydrate polymers. Warning for a conscious and proper use of oxidized regenerated cellulose. *Carbohydrate Polymers*, 216, 213-216. <https://doi.org/10.1016/j.carbpol.2019.04.036>
- Fu, F., Hou, Y., Jiang, W., Wang, R., & Liu, K. (2005). Escin: Inhibiting inflammation and promoting gastrointestinal transit to attenuate formation of postoperative adhesions. *World Journal of Surgery*, 29, 1614-1620. DOI: 10.1007/s00268-005-7870-5
- Gray, C. F., Redpath, T. W., Bainton, R., & Smith, F. W. (2001). Magnetic resonance imaging assessment of a sinus lift operation using reoxidised cellulose (Surgicel®) as graft material. *Clinical Oral Implants Research*, 12(5), 526-530. <https://doi.org/10.1034/j.1600-0501.2001.120514.x>
- Ghobrial, S., Ott, J., & Parry, J. P. (2023). An overview of postoperative intraabdominal adhesions and their role on female infertility: A narrative review. *Journal of Clinical Medicine*, 12(6), 2263. <https://doi.org/10.3390/jcm12062263>
- Güney, G., Kaya, C., Oto, G., Yıldırım, S., Özdemir, H., & Tokmak, A. (2017). Effects of quercetin and surgicel for preventing adhesions after gynecological surgery: A rat uterine horn model. *Journal of Obstetrics and Gynaecology Research*, 43(1), 179-184. <https://doi.org/10.1111/jog.13185>
- Hoffmann, N. E., Siddiqui, S. A., Agarwal, S., McKellar, S. H., Kurtz, H. J., Gettman, M. T., & Ereth, M. H. (2009). Choice of hemostatic agent influences adhesion formation in a rat cecal adhesion model. *Journal of Surgical Research*, 155(1), 77-81. <https://doi.org/10.1016/j.jss.2008.08.008>
- Jallouli, M., Hakim, A., Znazen, A., Sahnoun, Z., Kallel, H., Zghal, K., Hammami, A., & Mhiri, R. (2009). Rifamycin lavage in the treatment of experimental intra-abdominal infection. *Journal of Surgical Research*, 155(2), 191-194. <https://doi.org/10.1016/j.jss.2008.03.041>
- Larsson, B. (1996). Efficacy of Interceed in adhesion prevention in gynecologic surgery: A review of 13 clinical studies. *The Journal of Reproductive Medicine*, 41(1), 27-34.
- Lorian, V., & Ernst, J. (1987). Effects of antibiotics on bacterial structure and their pathogenicity. *Pathologie-Biologie*, 35(10 Pt 2), 1370-1376.
- Mais, V., Ajossa, S., Piras, B., Guerriero, S., Marongiu, D., & Melis, G. B. (1995). Prevention of de-novo adhesion formation after laparoscopic myomectomy: A randomized trial to evaluate the effectiveness of an oxidized regenerated cellulose absorbable barrier. *Human Reproduction*, 10(12), 3133-3135. <https://doi.org/10.1093/oxfordjournals.humrep.a135873>

- Marvel, S. J. (2022). Concepts in sterilization. *Veterinary Clinics: Small Animal Practice*, 52(2), 419-436.
- Mavigök, E., Bakacak, M., Yazar, F. M., Bakacak, Z., Yaylali, A., Boran, Ö. F., & Bahar, A. Y. (2019). A comparison in an experimental rat model of the effects on adhesion formation of different hemostatic methods used in abdominopelvic surgery. *Ginekologia Polska*, 90(9), 507-512. DOI: 10.5603/GP.2019.0088
- McGaw, T., Elkins, T. E., DeLancey, J. O., McNeely, S. G., & Warren, J. (1988). Assessment of intraperitoneal adhesion formation in a rat model: Can a procoagulant substance prevent adhesions?. *Obstetrics & Gynecology*, 71(5), 774-778.
- Nishimura, K., Bieniarz, A., Nakamura, R. M., & diZerega, G. S. (1983). Evaluation of oxidized regenerated cellulose for prevention of postoperative intraperitoneal adhesions. *The Japanese Journal of Surgery*, 13, 159-163.
- Oncel, M., Kurt, N., Remzi, F. H., Sensu, S. S., Vural, S., Gezen, C. F., Dalkilic, G., & Olcay, E. (2001). The effectiveness of systemic antibiotics in preventing postoperative, intraabdominal adhesions in an animal model. *Journal of Surgical Research*, 101(1), 52-55. <https://doi.org/10.1006/jsre.2001.6245>
- Pereira, B. M., Bortoto, J. B., & Fraga, G. P. (2018). Topical hemostatic agents in surgery: Review and prospects. *Revista do Colégio Brasileiro de Cirurgiões*, 45, e1900. <https://doi.org/10.1590/0100-6991e-20181900>
- Rabbani, A. H., Naseer, O., Hussain, K., Shahid, M., Ullah, Q., Ahmad, A. S., Qureshi, A. R., & Wadood, F. (2023). Small Animal Ovariohysterectomy and Avoidance of Associated Complications in Pet Practices Across Pakistan: A Current Perspective. *Small Animal Advances*, 2(4), 38-43. <https://doi.org/10.58803/saa.v2i4.18>
- Shimanuki, T., Nishimura, K., Montz, F. J., Nakamura, R. M., & Dizerega, G. S. (1987). Localized prevention of postsurgical adhesion formation and reformation with oxidized regenerated cellulose. *Journal of Biomedical Materials Research*, 21(2), 173-185. <https://doi.org/10.1002/jbm.820210203>
- Sirovy, M., Odlozilova, S., Kotek, J., Zajak, J., & Paral, J. (2023). Current options for the prevention of postoperative intra-abdominal adhesions. *Asian Journal of Surgery*, 47, 77-82. <https://doi.org/10.1016/j.asjsur.2023.10.001>
- Slatter, D. H. (Ed.). (2003). Textbook of small animal surgery (Vol. 1). Elsevier Health Sciences.
- Suresh, A. B., Rosani, A., Patel, P., & Wadhwa, R. (2023). Rifampin. In StatPearls. StatPearls Publishing.
- Tompeck, A. J., Dowling, M., Johnson, S. B., Barie, P. S., Winchell, R. J., King, D., Slatore, C., Coughlin, S. R., & Narayan, M. (2020). A comprehensive review of topical hemostatic agents: The good, the bad, and the novel. *Journal of Trauma and Acute Care Surgery*, 88(1), e1-e21. DOI: 10.1097/TA.0000000000002508
- Yavuz, A., Öner, G., Taş, M., & Çınaroğlu, S. (2021). The Effects of an Absorbable Hemostat Produced From Oxidized Regenerated Cellulose on Adhesion Formation in a Rat Model. *Medical Journal of Bakirkoy*, 17(2), 166-172. DOI: 10.4274/BMJ.galenos.2021.30075
- Zhang, F., Bonidie, M. J., Ventrelli, S. M., & Furlan, A. (2015). Intraovarian oxidized cellulose (Surgicel) mimicking acute ovarian pathology after recent pelvic surgery. *Radiology Case Reports*, 10(4), 39-41. <https://doi.org/10.1016/j.radcr.2015.08.002>
- Zhang, S., Li, J., Chen, S., Zhang, X., Ma, J., & He, J. (2020). Oxidized cellulose-based hemostatic materials. *Carbohydrate Polymers*, 230, 115585. <https://doi.org/10.1016/j.carbpol.2019.115585>
- Zheng, Z., Zhang, W., Sun, W., Li, X., Duan, J., Cui, J., Feng, G., & Mansour, H. M. (2013). Influence of the carboxymethyl chitosan anti-adhesion solution on the TGF- $\beta$ 1 in a postoperative peritoneal adhesion rat. *Journal of Materials Science: Materials in Medicine*, 24, 2549-2559.