

## PAPER DETAILS

TITLE: The effects of safranal against bisphenol AF on some reproductive parameters in male new zealand rabbits

AUTHORS: Muhammed ETYEMEZ,Mehmet Sükrü GÜLAY

PAGES: 207-217

ORIGINAL PDF URL: <https://dergipark.org.tr/tr/download/article-file/2517034>

# The effects of safranal against bisphenol AF on some reproductive parameters in male new zealand rabbits

Muhammed Etyemez<sup>1</sup>, Mehmet Şükrü Gülay<sup>2</sup>

<sup>1</sup>Department of Physiology, Faculty of Veterinary Medicine, Hatay Mustafa Kemal University, Hatay, Türkiye

<sup>2</sup>Department of Physiology, Faculty of Veterinary Medicine, Burdur Mehmet Akif Ersoy University, Burdur, Türkiye

## Key Words:

bisphenol AF  
male  
rabbit  
reproduction  
safranal

Received : 30.06.2022  
Accepted : 30.11.2022  
Published Online : 31.12.2022  
Article Code : 1138340

## Correspondence:

M. ETYEMEZ  
(metyemez82@gmail.com)

## ORCID

M. ETYEMEZ : 0000-0003-0497-1878  
MŞ. GÜLAY : 0000-0002-4960-1152

This article was produced from the doctoral thesis titled "Protective role of safranal on the possible subacute effects of Bisphenol Af in Male New Zealand Rabbits".

## ABSTRACT

Bisphenol AF (BPAF) is used as an analog of the endocrine disruptor Bisphenol A (BPA), whereas safranal is a powerful antioxidant obtained from the saffron plant. In the current study, the possible effects of BPAF and Safranal on some spermatological parameters, reproductive hormones, oxidant/antioxidant enzymes, and histopathological parameters were investigated. A total of 24 male New Zealand rabbits were divided into 4 groups (n= 6 for each group). The groups and the treatments they received by oral gavage for 9 weeks are as follows: The control group received by oral gavage 1 ml/day of corn oil, the BPAF group received by oral gavage 20 mg/kg/day of bisphenol AF, the Safranal group received by oral gavage 100 mg/kg/day safranal, and the treatment group received by oral gavage 20 mg/kg/day bisphenol AF and 100 mg/kg/day safranal. Although the spermatological parameters (sperm concentration, ejaculate volume, progressive motility, ejaculate weight, seminal plasma total protein, and pH) prior to the experiment revealed no differences among the groups, BPAF treatment reduced sperm quantity and motility at the end of the study. BPAF treatments also had a negative impact on testicular MDA and GSH levels. It also caused seminiferous tubule degeneration in testicular tissue. On the other hand, the administration of safranal with BPAF decreased estrogen levels while increasing sperm concentration and motility to control group levels. Thus, the results suggested that safranal could have a beneficial effect in reducing BPAF-induced tissue damage. In conclusion, BPAF may have potentially harmful to the male reproductive system and safranal may exhibit a protective effect against BPAF exposure.

## INTRODUCTION

Bisphenol AF (2,2-bis(4-hydroxyphenyl)-hexafluoropropane; BPAF) is a fluorinated BPA derivative with two methyl groups substituted by trifluoromethyl groups. It is used as a monomer in the production of specialized polymers, such as fluoropolymers and fluoroelastomers, polyesters, polyamides, and polyimides. It can also be used found in electronic components (Song et al., 2014). BPA and its derivatives can also be found in the liquid and solid parts of canned foods and beverages, as well as cosmetics and personal care items (Jagne et al., 2016). BPA manufacture has been restricted in recent years due to rising BPA exposure rates and growing public concern about harmful health impacts (Ma et al., 2019). BPA is currently listed 5th on the Environmental Protection Agency's Toxicological Priority Index (EPA, 2010). The development and production of alternative chemicals to replace BPA has been encouraged in recent years by strict regulations and restrictions on BPA. As a result, a number of chemicals known as "BPA analogs" have been utilized as a substitute for BPA in the production of polycarbonate plastics and epoxy resins (Riaz et al., 2021). Parallel to this, the United States (USA) National Institute of Health (NIH) has approved the use of Bisphenol AF (BPAF), an organofluoride chemical created by

replacing the methyl hydrogens of BPA with fluorine and a structural analog of BPA (NIH, 2022).

Despite its increasing use, the number of studies on BPAF is still limited. BPAF exposure has been proven to have negative effects on steroidogenesis in studies (Siracusa et al., 2018). BPAF at a concentration of 1 mg/L reduced testosterone levels and affected testicular morphology in male zebrafish (Yang et al., 2016; Shi et al., 2015). BPAF disrupted the blood-testicular barrier and has a negative impact on sperm quality in mice (Wu et al., 2019). It is known that offsprings exposed to BPAF before and after birth have lower testicular testosterone levels and have significantly more alterations in genes involved in cell differentiation and meiosis (Li et al., 2016). These findings suggest that BPAF may be a more potent endocrine disruptor than BPA (Siracusa et al., 2018).

Safranal is a potent antioxidant produced by the saffron (*Crocus sativus*) plant's secondary metabolism (Hosseinzadeh and Sadeghnia, 2005; Hosseinzadeh et al. 2003). Safranal has also been shown to have anti-inflammatory (Alayunt et al., 2019), anticancer (Zhang et al., 2018), antimicrobial (Khayyat and Elgendy, 2018), antihyperglycemic (Kianbakht and Hajjaghahae, 2011), and neuroprotective (Sadeghnia et al., 2017) ef-

fects. Saffron, as an antioxidant, improves sperm morphology and motility in infertile men (Heidary et al., 2008). Saffron supplementation reduces the damage to sperm DNA caused by exercise stress (Maleki et al. 2016). It can also eliminate chromatin abnormalities in sperm (Mardani et al., 2014). Saffron helps protect the integrity of the sperm membrane (Vaez et al., 2014) and improved epididymal sperm parameters in rats exposed to cadmium (Asadi et al., 2014). In the testis tissue of diabetic rats, safranal has an antioxidative effect, indicating that it may protect against oxidative stress (Ataei and Rahbarian, 2020).

Therefore, the current study aimed to investigate the potential therapeutic effects of safranal against the possible negative effects of BPAF on some oxidant-antioxidant, histopathological, hormones and male reproductive parameters in male New Zealand White rabbits.

## MATERIALS AND METHODS

### *Experimental Animal Material and Experimental Protocol*

Hatay Mustafa Kemal University Rectorate Animal Experiments Local Ethics Board approved the study protocol (2020/07-1;15/12/2020). In the present study, a total of 24 male New Zealand rabbits (*Oryctolagus cuniculus*) aged 8-10 months were used (n=6). The body weight of the rabbits was between 2400 and 2800 grams at the start of the experiment. They were fed standard pellet feed containing 9% raw ash, 20% crude protein, 14% crude fiber, 0.5% calcium, 0.5% phosphorus, and 0.2% sodium (Mirisan Yem ve Yag Sanayi, Hatay, Türkiye). The rabbits were acclimated for two weeks at a 50-55% humidity, a temperature of  $22\pm 2$  °C, and a 14:10 hour light: dark cycle prior to the experiment. The experimental period was 9 weeks long [49 days (one spermatogenesis time) + 14 days (sperm storage and transport time in the epididymis)]. Weekly measurements of live weight and feed intake were recorded. Oral gavage applications were performed every day between 17:00 and 18:00.

After a two-week adaptation period, the rabbits were randomly divided into four study groups, each with six rabbits: Control group (C; 1 ml corn oil/day, orally), BPAF group (BF; 20 mg/kg/day Bisphenol AF [Alpha-Aesar A18370.14, Haverhill, Massachusetts, USA] in 1 ml corn oil, orally), Safranal group (SF; 100 mg/kg/day safranal [Sigma-Aldrich W338907, St. Louis, Missouri, USA] in 1 ml corn oil, orally), BPAF+Safranal group (B+S; 20 mg/kg/day Bisphenol AF + 100 mg/kg/day safranal in 1 ml corn oil, orally). There was no statistical difference in the live weights of the rabbits in the groups at the start of the study.

A total of 25 ml of blood was obtained from rabbits via the ear artery one hour after the last oral gavage administration. Blood was collected into EDTA coated (for whole blood and plasma) and non-anticoagulant tubes (for serum). The blood samples were kept at +5-6 °C until they were centrifuged (2000 rpm for 20 minutes) within 30 minutes to obtain serum and plasma samples.

After 24 hours of the last oral gavages, rabbits were euthanized under general anesthesia with isoflurane. The left tes-

ticles were washed with chilled saline at +4 °C before being stored in a deep freezer at -80 °C for the measurement of ELISA and oxidative stress parameters. Right testicles were sent for histopathological examination in formaldehyde.

### *Hormone Assays*

Hormone analysis kits were assembled in accordance with the manufacturer's instructions (Bioassay Technology Laboratory, China). Serum, testicular, and seminal plasma testosterone (BT-LAB E0039Rb Rabbit Testosterone ELISA Kit, Standart Curve Range: 0.2-90ng/ml, Intra-Assay: CV<8%, Inter-Assay: CV<10%) and estradiol hormone (BT-LAB E0274Rb Rabbit Estrogen ELISA Kit, Standart Curve Range: 0.5-100ng/L, Intra-Assay: CV<8%, Inter-Assay: CV<10%) levels were assessed using rabbit-specific ELISA kits.

### *Semen Collection*

Rabbits were accustomed to the artificial vagina for 14 days before the study began. Ejaculates were collected once a week through the artificial vagina and directly into graded and warmed glass tubes. After the gel portion of the ejaculate was removed, the volume and weight were measured. Ejaculate samples were stored in a +32°C water bath until spermatological analyses (Ata A., 2018).

### *Semen Analysis*

Ejaculate volume, weight, sperm pH, concentration, and motility were assessed in ejaculates collected at the start and end of the study from rabbits (Ata A.,2018). Hydrogen ion concentrations were measured immediately after the collections using a pH meter (Orion Ross Ultra pH/ATC Triode, Orion 3 Star pH benchtop, Thermo Scientific, USA). The phosphate saline buffer was used to dilute sperm samples ten times. The percentage of sperm motility was determined using a phase-contrast microscope (400X magnification, Nikon E 200) with a heating plate (37.8 °C). Three distinct areas were scanned, and the averages were calculated and expressed as a percentage (%) under the microscope.

Following gel removal, the volume of ejaculate was measured using a graduated tube. A precision balance was used to weigh the ejaculate samples. Sperm count was performed on a Thoma slide with 400 times magnification under the same microscope in 0.1 ml of formalin saline solution. The sperm concentration and ejaculate volume values were used to calculate the number of sperm in the total ejaculate.

Following the measurements, the remaining ejaculates were centrifuged at 2000 rpm for 20 minutes to separate the seminal plasma, and 10µL of the resulting seminal plasma was then added to a refractometer (Atago, SPR-N, Japan) to quantify the total seminal plasma protein levels (SPTP).

### *Oxidant and Antioxidant Parameters*

Testicular tissue samples were homogenized at a 1:10 ratio with 1.15 % KCl and half of this homogenate was used for malondialdehyde (MDA) analysis. The other half was centrifuged for 1 hour at 5000 g (+4 °C), the supernatants were separated, and glutathione (GSH), glutathione peroxidase (GPx),

and catalase (CAT) analyses were carried out from these supernatants. The level of MDA in the study was measured by the method of Ohkawa et al. (1979). The method developed by Beutler et al. (1963) was used to determine the level of reduced GSH. The activity of the CAT and GPx enzyme was assessed using the methods of Aebi (1984) and Beutler (1975), respectively. Protein analyses were carried out from the supernatant generated from the homogenate using the technique of Lowry et al. (1951).

#### *Histopathological Examination*

The testicles were dehydrated by passing through graded alcohol after being fixed in 10% formaldehyde for 48 hours. After embedding in paraffin, the tissues were washed with xylene, cut at a thickness of 4-5  $\mu\text{m}$ , stained with Hematoxylin Eosin (Luna, 1968), and inspected for histological alterations under a microscope (Olympus BX50-F4, Tokyo, Japan) at 10-40-100X magnification.

#### *Statistical Analysis*

All values are expressed as mean  $\pm$ SD (Standard Deviation). For statistical analysis, the SAS statistical program's PROC ANOVA was used. The Tukey test was used to compare results with statistical differences. When the difference between groups was  $P < 0.05$ , the difference was regarded as significant in all statistical applications.

### RESULTS

The rabbits had no clinical problems during the course of the experiment. No differences among the groups from the initial sperm samples collected were apparent: sperm concentration, ejaculate volume, progressive motility, ejaculate weight, seminal plasma total protein, and pH were similar in both groups (Table 1). On the other hand, the SF and C groups had the highest sperm concentrations from samples collected at the end of the study (Table 2). Compared to the B+S group, sperm concentrations in the BF group decreased substantially. The total sperm count calculated from the ejaculate volume and sperm concentration data did not differ across the groups. Similarly, the ejaculate volume, testis weights, and epididymis weights did not differ significantly among the groups (Table 2).

There was no difference among the groups for initial serum estrogen and testosterone levels (Table 3). However, there were significant differences in the estrogen levels apparent from the samples taken at the end of the study (Table 4). Estrogen levels were lowest in SF and B+S groups, and there was a significant difference in serum estrogen levels between BF and B+S groups. Moreover, the amount of estrogen in testicular tissue also differed significantly across groups. The lowest levels of estrogen in testicular tissues were in the SF and B+S groups. When compared to the BF group, the B+S group also had significantly lower testicular estrogen levels. However, serum, seminal plasma, and testicular testosterone levels did not statistically differ among the groups.

It is seen that this hormone has the lowest values in SF and B+S groups in serum. Although the serum estrogen amount was at the highest values in the BF group, it was not significant compared to the C group. However, it was found at significantly higher levels compared to the SF and B+S groups. In the analyzes performed on testicular tissue, the amount of estrogen hormone varied significantly between the groups. Estrogen levels in the testicles of the SF group were the lowest compared to the C and BF groups. In the B+S group, statistically significant lower values were observed compared to the BF group. There was no statistical difference between the groups in other reproductive parameters.

Table 5 presents the oxidant-antioxidant enzymes tested in the current study. None of the treatments altered GPx and CAT levels. On the other hand, serum MDA levels were significantly elevated in the BF group. The addition of safranal was able to lower the MDA in the B+S group. Rabbits in the BF group had also significantly lower serum GSH levels when compared to the rabbits in SF and C groups.

Histopathological examination of the testis tissue showed that the basement membrane, germinative epithelium of the seminiferous tubules, Sertoli cells, and Leydig cells in the interstitial area had normal histological features for the rabbits in the C group (Figure 1,2,3). The morphology of the majority of the tubules in the testicles of the rabbits in the BF group was damaged, and some of them were atrophied (Figure 4,5,6,7). Although the tubules in the B+S group were mostly morpho-

**Table 1.** Initial spermatological parameters (mean $\pm$ SD) of New Zealand White rabbits prior to the experimental procedure.

	C	BF	SF	B+S	P=
Sperm Concentration( $\times 10^6/\text{mm}^3$ )	272.83 $\pm$ 81.25	227.66 $\pm$ 77.1	257.83 $\pm$ 52.82	244.66 $\pm$ 55.19	0.698
Sperm Motility(%)	62.50 $\pm$ 5.24	54.16 $\pm$ 12.81	60.83 $\pm$ 9.7	61.66 $\pm$ 6.83	0.393
Ejaculate Volume(ml)	0.63 $\pm$ 0.26	0.76 $\pm$ 0.24	0.73 $\pm$ 0.28	0.85 $\pm$ 0.18	0.519
Ejaculate Weight(mg)	0.828 $\pm$ 0.296	0.755 $\pm$ 0.211	0.841 $\pm$ 0.252	0.848 $\pm$ 0.207	0.905
Sperm pH	6.80 $\pm$ 0.04	6.80 $\pm$ 0.13	6.82 $\pm$ 0.10	6.80 $\pm$ 0.06	0.987
SPTP(mg/dl)	2.35 $\pm$ 0.32	2.41 $\pm$ 0.51	2.43 $\pm$ 0.46	2.38 $\pm$ 0.49	0.989
Total sperm (ejaculate volume X concentration, $\times 10^6/\text{ml}$ )	175.03 $\pm$ 80.3	171.88 $\pm$ 78.1	179.13 $\pm$ 50.0	210.78 $\pm$ 72.4	0.768

C= Control group, BF= Bisphenol AF group, SF= Safranal group, B+S= Bisphenol AF+Safranal group. SPTP = Seminal Plasma Total Protein.

**Table 2.** Effects of BPAF and/or safranal on some reproductive parameters (mean±SD) of New Zealand White Rabbits.

	C	BF	SF	B+S	P=
Sperm Concentration(x10 <sup>6</sup> /mm <sup>3</sup> )	284.2 <sup>a</sup> ± 67.41	194.0 <sup>b</sup> ± 65.72	305.83 <sup>a</sup> ± 35.27	246.66 <sup>ab</sup> ± 43.55	0.012
Sperm Motility(%)	64.16 <sup>a</sup> ± 5.84	45.0 <sup>b</sup> ± 8.94	67.5 <sup>a</sup> ± 8.21	63.33 <sup>a</sup> ± 6.05	0.000
Ejaculate Volume(ml)	1.01 <sup>a</sup> ± 0.27	0.85 <sup>ab</sup> ± 0.10	1.0 <sup>a</sup> ± 0.23	0.91 <sup>ab</sup> ± 0.24	0.557
Ejaculate Weight(mg)	0.96 ± 0.37	0.77 ± 0.19	0.98 ± 0.33	0.88 ± 0.33	0.654
Sperm pH	6.83 ± 0.05	6.75 ± 0.11	6.86 ± 0.1	6.8 ± 0.04	0.183
SPTP (mg/dl)	2.43 ± 0.46	2.43 ± 0.5	2.28 ± 0.41	2.48 ± 0.48	0.892
Testicular Weight(gr)	3.33 ± 0.20	3.14 ± 0.19	3.15± 0.19	3.16± 0.23	0.368
Epididymis Weight(gr)	0.77 ± 0.09	0.78 ± 0.07	0.80 ± 0.08	0.79 ± 0.08	0.888
Total sperm (ejaculate volume X concentration, x10 <sup>6</sup> /ml)	304.0 ±155.4	167.9±68.15	312.1 ±105.0	227.8 ±80.3	0.096

C= Control group, BF= Bisphenol AF group, SF= Safranal group, B+S= Bisphenol AF+Safranal group. SPTP = Seminal Plasma Total Protein.

**Table 3.** Initial serum estrogen and testosterone concentrations (mean±SD) of New Zealand White rabbits prior to the experimental procedure.

	C	BF	SF	B+S	P=
Estrogen(ng/L)	21.52±2.56	19.05±2.14	19.38±2.21	21.51±3.98	0.293
Testosterone(ng/ml)	12.13±0.90	11.57±0.87	11.79±0.84	11.29±1.31	0.540

C= Control group, BF= Bisphenol AF group, SF= Safranal group, B+S= Bisphenol AF+Safranal group.

**Table 4.** Effects of BPAF and/or safranal on serum, seminal plasma and testicular testosterone and estrogen levels (mean±SD) of New Zealand White Rabbits.

	C	BF	SF	B+S	P=
Serum Estrogen (ng/L)	20.36 <sup>ab</sup> ± 5.02	21.80 <sup>a</sup> ± 4.82	15.31 <sup>bc</sup> ± 4.25	14.88 <sup>c</sup> ± 2.87	0.023
Seminal Plasma Estrogen (ng/L)	29.19 ± 8.94	33.7 ± 5.68	36.8 ± 7.51	33.51 ± 12.35	0.546
Testicular Estrogen (ng/L)	20.92 <sup>ab</sup> ± 3.96	29.84 <sup>a</sup> ± 7.49	8.07 <sup>c</sup> ± 9.15	11.28 <sup>bc</sup> ± 12.18	0.001
Serum Testosteron (ng/ml)	12.01 ± 1.99	11.61 ± 1.57	12.17 ± 0.84	11.17 ± 2.05	0.741
Seminal Plazma Testosteron (ng/ml)	42.69 ± 4.63	37.65 ± 4.09	44.70 ± 5.67	44.92 ± 12.73	0.343
Testicular Testosteron (ng/ml)	75.5 ± 14.7	66.5 ± 16.5	75.9 ± 22.5	68.7 ± 16.3	0.731

C= Control group, BF= Bisphenol AF group, SF= Safranal group, B+S= Bisphenol AF+Safranal group. Different superscript letters (a, b, c) in the same line show statistically significant differences between groups as “±”.

**Table 5.** Effects of BPAF and/or safranal on some oksidant-antioxidant parameters (mean±SD) in testis tissues of New Zealand White Rabbits.

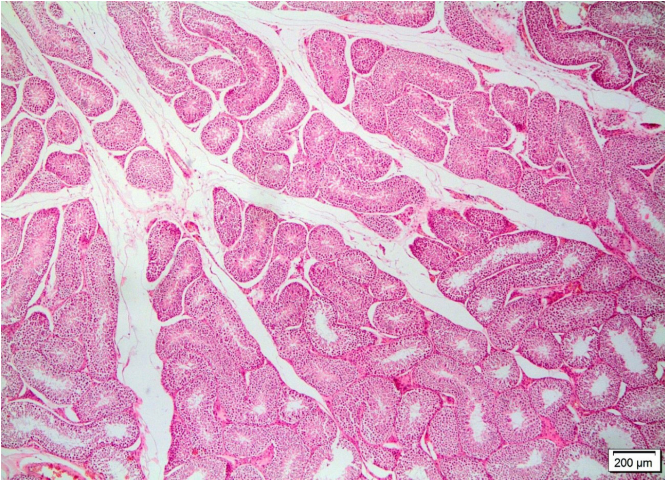
	C	BF	SF	B+S	P=
MDA(nmol/gr protein)	3.67 <sup>c</sup> ±0.47	16.30 <sup>a</sup> ±6.16	4.64 <sup>c</sup> ±1.00	8.77 <sup>b</sup> ±0.55	0.0001
GSH(nmol/gr protein)	1.74 <sup>ab</sup> ±0.20	1.43 <sup>b</sup> ±0.17	1.84 <sup>a</sup> ±0.21	1.97 <sup>a</sup> ±0.36	0.0094
GPx(IU/gr protein)	26.95±3.52	25.93±2.49	26.69±2.67	25.95±2.11	0.8846
CAT(IU/gr protein)	91.35±5.88	90.13±4.84	90.99±6.02	88.93±5.37	0.8770

C= Control group, BF= Bisphenol AF group, SF= Safranal group, B+S= Bisphenol AF+Safranal group. MDA=Malondialdehyde, GSH=Reduced Glutathione, GPx= Glutathione Peroxidase, CAT= Catalase. Different superscript letters (a, b, c) in the same line show statistically significant differences between groups as “±”.

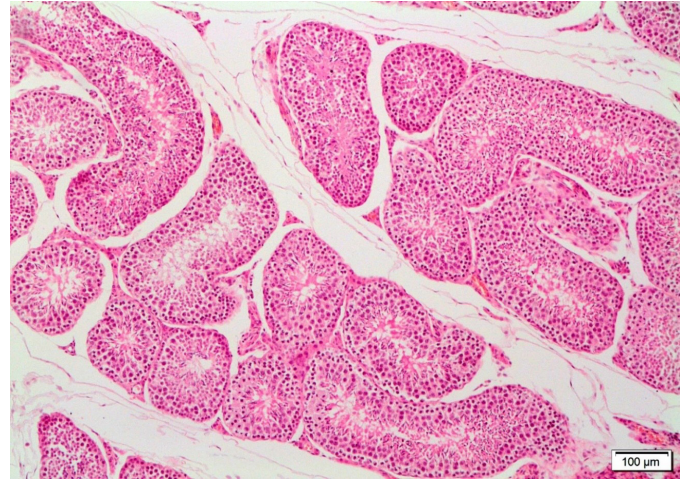
logically normal, morphological changes in some tubules and the interstitial area, including Leydig cells were present (Figure 8,9,10). There was also a slight deterioration in the spermatogenic cell line in the degenerated tubules, as well as a few vacuoles in some germinative cells. However, these changes were milder compared to the changes in the BF group. The basal

genetic cell line in the degenerated tubules, as well as a few vacuoles in some germinative cells. However, these changes were milder compared to the changes in the BF group. The basal

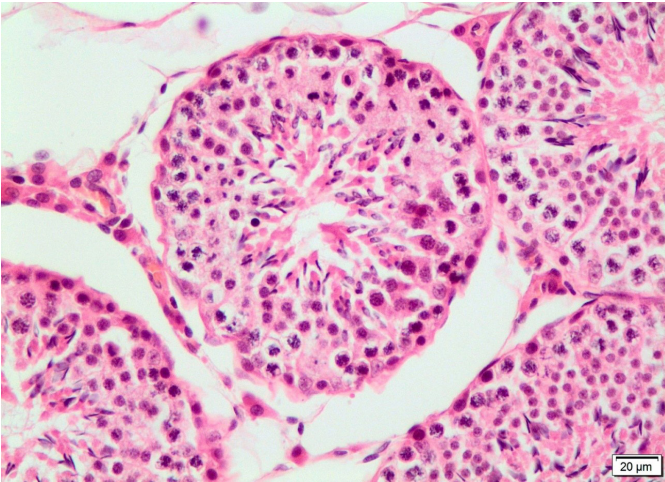




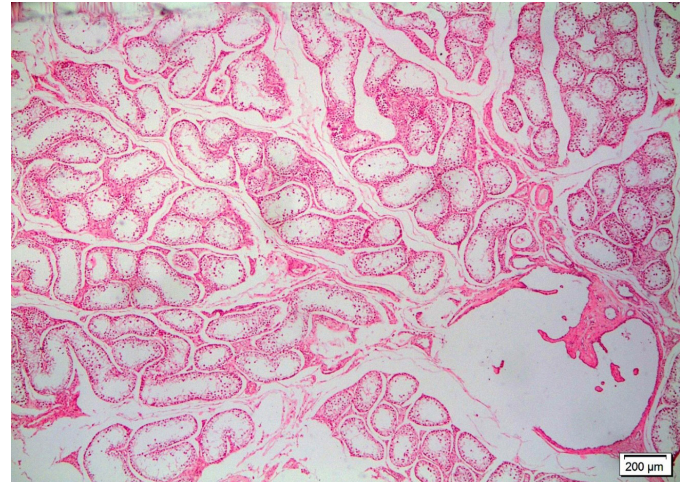
**Figure 1.** Microscopic view of the normal histological structure of testicular tissue of the control group. H.E. x40



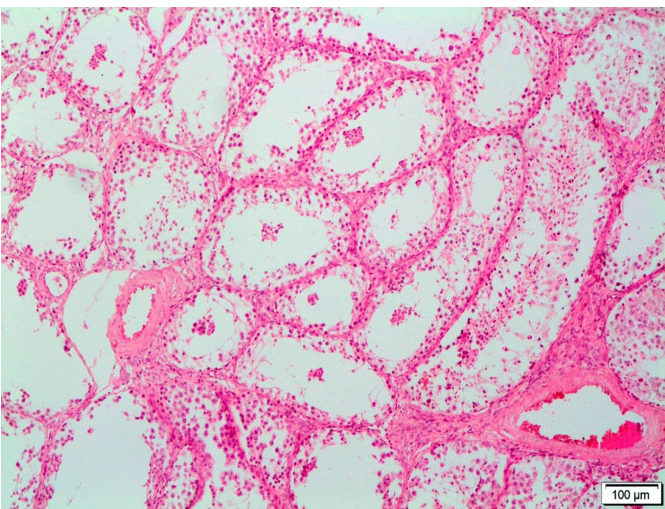
**Figure 2.** Close microscopic view of the normal histological structure of the testicular tissue of the control group. H.E. x100



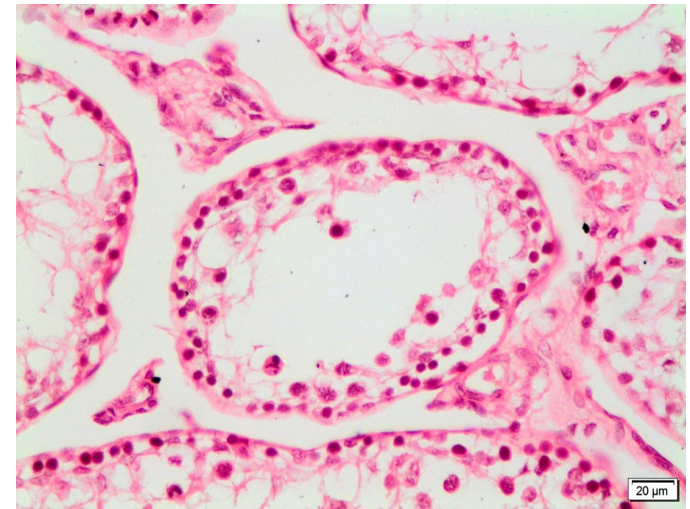
**Figure 3.** A closer microscopic view of the normal histological structure of testicular tissue belonging to the control group. H.E. x400



**Figure 4.** Microscopic view of testicular tissue belonging to the BPAF group. H.E. x40

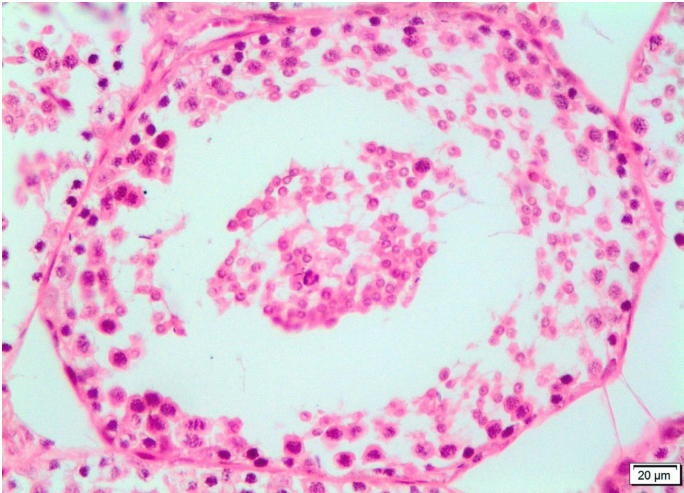


**Figure 5.** Close microscopic view of seminiferous tubules whose structures are completely destroyed in the testicular tissue of the BPAF group. H.E. x100

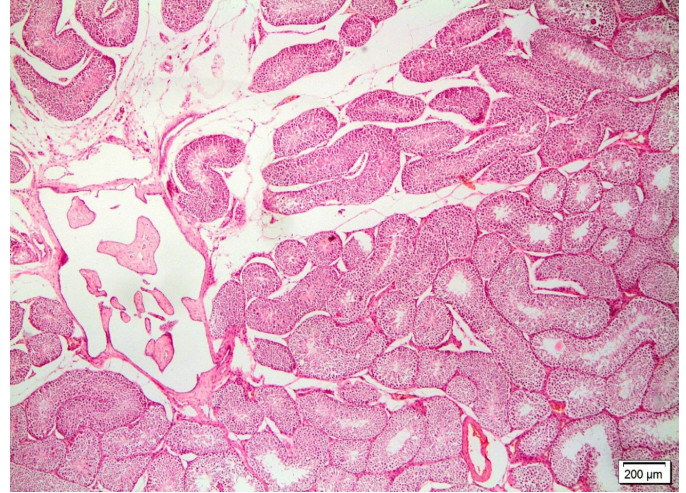


**Figure 6.** Closer microscopic view of degenerative and necrotic changes in the seminiferous tubule, whose structure is completely destroyed in the testicular tissue of the BPAF group. H.E. x400

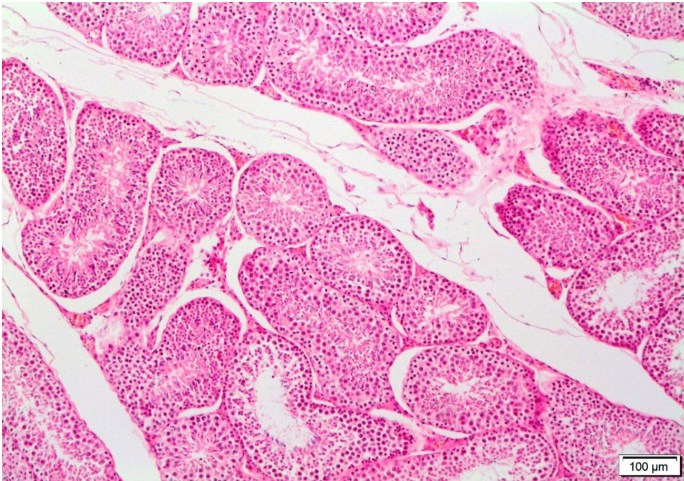




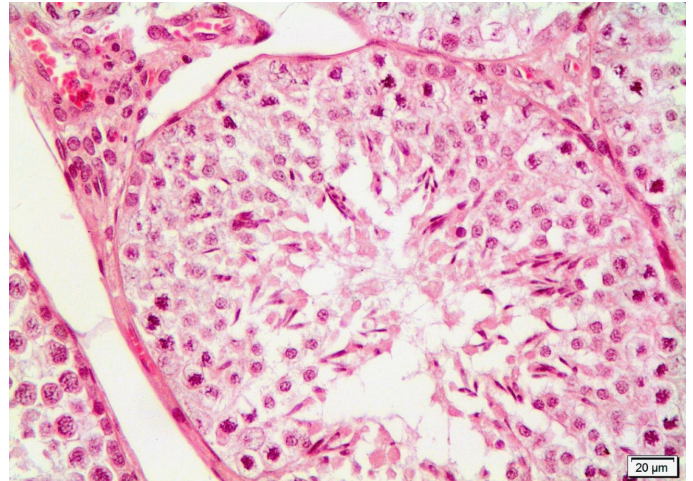
**Figure 7.** Microscopic view of germinative epithelial cells spilling into the lumen in a degenerated tubule of testicular tissue belonging to the BPAF group. H.E. x400



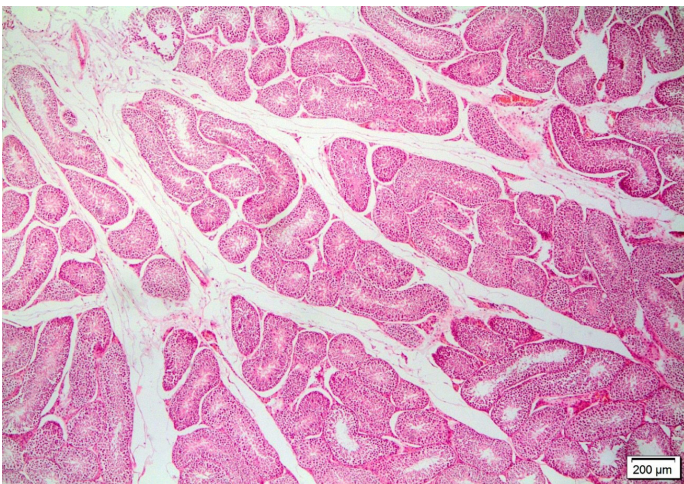
**Figure 8.** Microscopic view of the nearly normal histological structure of testicular tissue belonging to the BPAF+Safranal group. H.E. x40



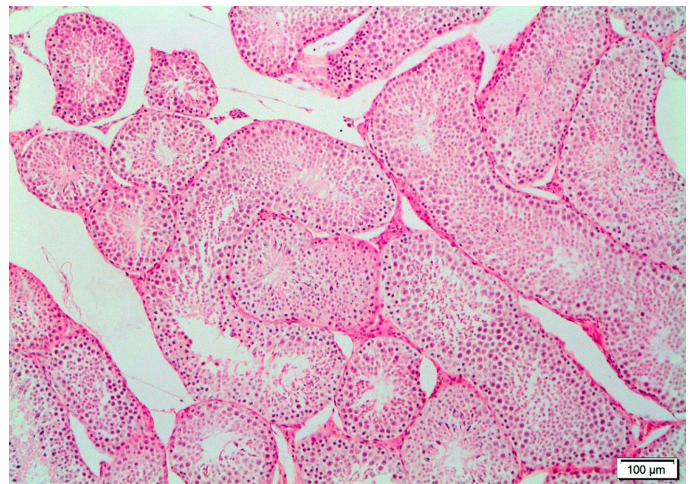
**Figure 9.** Close microscopic view of the nearly normal histological structure of the testicular tissue belonging to the BPAF+Safranal group. H.E. x100



**Figure 10.** Near-normal microscopic appearance of germinative epithelial cell lines and Leydig cells in the interstitium and vascular structures in the testis tissue of the BPAF+Safranal group. H.E. x400

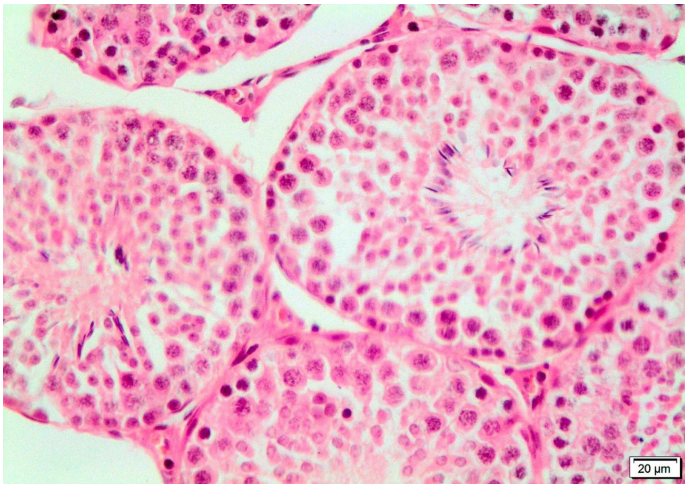


**Figure 11.** Microscopic view of the normal histological structure of testis tissue belonging to the Safranal group. H.E. x40



**Figure 12.** Close microscopic view of the normal histological structure of the testis tissue belonging to the Safranal group. H.E. x100





**Figure 13.** A closer microscopic view of the normal histological structure of the testis tissue belonging to the Safranal group. H.E.  $\times 400$

membrane, spermatogonia forming the spermatogenic cell lines in the tubular wall, spermatogonia, spermatocytes and spermatid cells, and the interstitial area including the supporting cells Sertoli cells and Leydig cells of the SF group had a histological structure similar to the C group, and spermatogenesis continued normally (Figure 11,12,13).

## DISCUSSION

The current study indicated that BPAF has some negative effects on the male rabbits' reproductive system. The results suggested that an oral 20 mg/kg of BPAF every day may lower fertility rates, particularly by lowering sperm concentration and motility. Additionally, when compared to other groups, BPAF tended to increase serum and testicular estrogen levels. As seen in zebrafish, BPAF can strongly bind to estrogenic receptors and might cause an elevation in estrogen secretion (Moreman et al., 2017). Another study also supports our findings that BPAF exposure resulted in increased estrogen levels in both male and female zebrafish (Yang et al., 2016). BPAF decreased serum testosterone levels and testicular weights in rats at a dose of 10 mg/kg, but no change occurred in estradiol levels at the same dose. In the same study, an increase in MDA levels was observed at a 200 mg/kg dose (Yu et al., 2022). In a different study, although serum and testicular estrogen levels were not affected, serum testosterone levels were reduced. It also caused morphological alterations in mice sperm, and reduced sperm mobility (Gao et al., 2022). Feng et al. (2012) reported that BPAF decreased testosterone levels by directly altering testicular function in male mice. In contrast to this study, BPAF exposure elevated the testicular testosterone levels in 23-day-old male rats (Li et al., 2016). The current study confirms earlier findings that BPAF reduces sperm quality and has a detrimental effect on male reproductive processes due to its estrogenic activity. Thus, BPAF should be taken into account as a possible cause of infertility (Wu et al., 2019; Rehfeld et al., 2020; Shi et al., 2015).

BPAF may have caused oxidative damage in testicular tissues by increasing the level of MDA and depleting antioxidant

levels such as GSH. In a rat study, BPAF increased testicular MDA levels while decreased antioxidant levels, which confirms our findings (Tian et al., 2022). According to previous reports, administering BPAF to mice did not change the level of MDA in the liver tissue (Meng et al., 2019). MDA is one of the most significant by-products of membrane lipid peroxidation, and the production of might, therefore, aggravate membrane damage. In the current study, the testicular tissue MDA levels increased only in the BPAF treated group compared to the controls. However, safranal addition to BPAF was able to reduce testicular MDA levels in the B+S group. Thus, similar to BPA, BPAF may also result in oxidative stress and tissue deterioration in male rabbits (Karabulut and Gulay, 2022). Furthermore, safranal can be helpful in lowering oxidative stress since antioxidants are chemicals that scavenge free radicals formed as a result of oxidative stress.

The testosterone hormone is produced by Leydig cells from cholesterol. It is essential for the development of the male reproductive system and spermatogenesis (Ye et al., 2011). Testosterone is required for the completion of meiosis during spermatocyte development. Testosterone is also important in preventing the premature release of spermatid. Moreover, testosterone facilitates the discharge of mature sperms into the lumen of the seminiferous tubule (Xiao et al., 2014). In rats, experimental oral administration of BPAF resulted in a substantial decrease in the expression levels of genes and proteins involved in cholesterol production, transport, and steroid biosynthesis activities (Feng et al., 2012). It has been established that BPAF exposure affects testosterone levels by altering genes and proteins in the testosterone biosynthesis pathway (Fic et al., 2015). BPAF has also been shown to reduce serum (Feng et al., 2012; Yu et al., 2022), plasma, and testicular testosterone levels in male laboratory animals (Huang et al., 2020) and in male zebrafish (Yang et al., 2016). However, the current study failed to show a significant change in testicular and serum testosterone levels due to BPAF. However, BPAF dose and species differences may be responsible for the discrepancy between the current study and the current literature.

BPA and its analogs have been shown to generate oxidative stress in plasma, testis, and sperm, resulting in impairment of spermatogenesis (Gules et al., 2019, Ullah et al., 2019). Increased oxidative stress in testicular tissue causes sperm quality to decline and testicular abnormalities due to Leydig, Sertoli, and germ cell dysfunction (Yusoff et al., 2017). BPAF has been demonstrated to inhibit the regeneration of Leydig cells by reducing testosterone synthesis, downregulating the expression of critical steroidogenesis-related genes, and inducing ROS and apoptosis/autophagic cell death (Yu et al., 2022). It has also been found to promote cytoskeleton dysregulation in Sertoli cells and to impair the cellular homeostasis that Sertoli cells execute in the seminiferous epithelium to maintain spermatogenesis. It has been stated that BPAF exposure in mice has a dose-dependent negative effect on blood-testicular barrier integrity, sperm quantity, and sperm quality (Wu et al., 2019). BPAF was found to significantly impair blood-testicular barrier integrity and sperm count, as well as promote human ovarian granulosa cell-like cell death (Huang et al., 2020, Wu et al., 2019). In pubertal rats, BPA lowered daily sperm out-



put (Herath et al., 2004). BPA exposure has been linked to reproductive disorders, such as decreased testicular weight and sperm count, hormonal abnormalities, and poor spermatogenesis (Wang et al., 2016). Similarly, BPAF exposure at various levels reduced testis, epididymis, and body weights in rats (Yu et al., 2022). In the current study, BPAF exposure reduced sperm concentration ratio and sperm motility in male rabbits. The present study suggests that oxidative damage caused by BPAF in the testicular tissue might be the cause of the decrease in these parameters. Safranal treatment significantly reduced the negative effect of BPAF on sperm motility. Thus, safranal could protect testicular tissue from the harmful effects of BPAF and improve spermatological parameters.

Histopathological findings in our study support other spermatological findings. BPAF can cause the disruption of the seminiferous tubules in testicular tissue (Sutherland et al., 2019). Studies in many animal species, including mice, zebrafish, *Xenopus laevis* (an African clawed frog), and chicken embryos have shown that the histological structure of testicles was compromised due to BPAF exposure (Wu et al., 2019; Yang et al., 2016; Mentor et al., 2020; Cai et al., 2020). BPA exposure has been linked to histological abnormalities in testicles and epididymis, including degeneration, blockage, atrophy, and the loss of germinal cells in rats (Aydoğan et al., 2010). In the current study, the basement membrane, germinative epithelium of the seminiferous tubules, Sertoli cells, and Leydig cells in the interstitial area were normal in C and SF groups. However, the majority of the tubules in testicular tissues were distorted and some were atrophied in rabbits that had only been exposed to BPAF. Although mild morphological abnormalities were seen in some tubules and the interstitial area, most of the tubules in the B+S group were morphologically close to normal.

The majority of exogenous antioxidants are phytochemicals derived from plants (Sarangarajan et al., 2017). It is emphasized that safranal has significant antioxidant activity and may be useful in treating disorders induced by oxidative stress (Rahaiee et al., 2015). Safranal helps to stabilize cell membranes by scavenging ROS and lowering the peroxidation of unsaturated membrane lipids. As a result, safranal may have therapeutic value in conditions where radical scavenging action is important, such as neurodegenerative disorders (Samarghandian et al., 2015). Safranal possesses antioxidant properties and has been shown to lower lipid peroxidation and MDA levels in rats in vivo experiments (Hosseinzadeh et al., 2009). The MDA levels in testicular tissue were considerably lower in the B+S group. This also suggests the probability that longer-term safranal use might help to maintain desired MDA levels in BPAF-exposed rabbits. In diabetic rats, Ataei and Rahbarian (2020) support this positive effect of safranal.

GSH is thought to be the most essential intracellular hydrophilic antioxidant, protecting cells from free radical damage (Pandey and Rizvi 2010). BPAF exposure reduces GSH levels in testicular tissue and induces oxidative damage in rats (Tian et al., 2022). In our study, BPAF exposure significantly decreased the GSH levels in testicular tissue. The treatment with safranal stabilized the GSH levels in testicular tissues of

rabbits in the B+S group. The antioxidant enzyme glutathione peroxidase functions as a structural protein in the spermatozoa's mitochondrial capsules and is necessary for the early stage of spermatogenesis (Schneider et al., 2009). Both BPA and BPAF have been shown to cause oxidative stress by down-regulating antioxidant defense system expression, including a decrease in superoxide dismutase (SOD) and catalase (CAT) activity in zebrafish and human vascular endothelial cells (Gu et al., 2020). However, it has been reported that BPAF exposure in mice does not result in a significant difference in SOD, CAT, and GSH-Px enzyme activity in liver tissue (Meng et al., 2019). Thus, it should be noted that different criteria such as animal species, BPAF dose, and duration of the study may affect the outcome.

## CONCLUSION

The results of this study revealed that exposure to BPAF resulted in oxidative stress and altered estrogen hormone levels in the testicular tissue of male rabbits. These negative alterations possibly had a negative impact on the sperm parameters as well as the histological structure of testicular tissue. It is likely that the effects of BPAF at larger doses would be more evident. The study suggests that safranal exhibited antioxidant activity in testicular tissue and might mitigate the harmful effects of BPAF on testicular tissue. Additional studies at various doses and time intervals could be useful to fully characterize the effects of BPAF in rabbit testicular tissue and the protective effects of safranal.

## DECLARATIONS

### Ethics Approval

This study was ethically approved by Hatay Mustafa Kemal University Rectorate Animal Experiments Local Ethics Committee with the number 2020/07-1 (15/12/2020).

### Conflict of Interest

The authors declare that they have no competitive interests.

### Consent for Publication

Not applicable.

### Author contribution

Idea, concept and design: M.E, M.Ş.G

Data collection and analysis: M.E, M.Ş.G

Drafting of the manuscript: M.E, M.Ş.G

Critical review: M.E, M.Ş.G

### Data Availability

Data supporting the findings of this study are available from the corresponding author upon reasonable request.

### Acknowledgements

The authors thank Assoc. Dr. Ahmet Uyar for his histopathological evaluations.

## REFERENCES

1. Aebi, H. (1984). "Catalase in vitro", *Methods in enzymology*, 105, 121-126.

2. Alayunt, Ö.N., Lacine, A., Karafakioğlu, Y.S., Sevimli, S. (2019). 'Assessment of Anti-inflammatory and Antioxidant Properties of Safranal on CCl<sub>4</sub>-Induced Oxidative Stress and Inflammation in Rats', *Anais da Academia Brasileira de Ciências*, 91.
3. Asadi, M.H., Fariba, Z., Arash, S., Mehdi, A., Majid, S., Morteza, K., Abazar, Y., Rafieh, A.M. (2014). 'Saffron improves epididymal sperm parameters in rats exposed to cadmium', *Nephro-urology monthly*, 6.
4. Ata, A., Yildiz-Gulay, O., Güngör, S., Balic, A., & Gulay, M. S. (2018). The effect of carob (*Ceratonia siliqua*) bean extract on male New Zealand White rabbit semen. *World Rabbit Science*, 26(3), 209-215.
5. Ataei, G., & Rahbarian, R. (2020). Investigating the effect of safranal on Bax and Bcl2 and oxidative stress levels in testis tissue of streptozotocin-induced diabetic rats. *KAUMS Journal (FEYZ)*, 24(1), 10-20.
6. Aydoğan, M., Korkmaz, A., Barlas, N., & Kolankaya, D. (2010). Pro-oxidant effect of vitamin C coadministration with bisphenol A, nonylphenol, and octylphenol on the reproductive tract of male rats. *Drug and Chemical Toxicology*, 33(2), 193-203.
7. Beutler, E. (1963). 'Improved method for the determination of blood glutathione', *J. lab. clin. Med.*, 61: 882-88.
8. Beutler, E. (1975). 'Glutathione in red blood cell metabolism', *A manual of biochemical methods*: 112-14.
9. Cai, M., Li, Y. Y., Zhu, M., Li, J. B., & Qin, Z. F. (2020). Evaluation of the effects of low concentrations of bisphenol AF on gonadal development using the *Xenopus laevis* model: A finding of testicular differentiation inhibition coupled with feminization. *Environmental Pollution*, 260, 113980.
10. Feng, Y., Yin, J., Jiao, Z., Shi, J., Li, M., & Shao, B. (2012). Bisphenol AF may cause testosterone reduction by directly affecting testis function in adult male rats. *Toxicology letters*, 211(2), 201-209.
11. Fic, A., Mlakar, S. J., Juvan, P., Mlakar, V., Marc, J., Dolenc, M. S., Brober, K., & Mašič, L. P. (2015). Genome-wide gene expression profiling of low-dose, long-term exposure of human osteosarcoma cells to bisphenol A and its analogs bisphenols AF and S. *Toxicology in Vitro*, 29(5), 1060-1069.
12. Gao, Z., Liu, S., Tan, L., Gao, X., Fan, W., Ding, C., Li, M., Tang, Z., Shi, X., Luo, Y., & Song, S. (2022). Testicular toxicity of bisphenol compounds: Homeostasis disruption of cholesterol/testosterone via PPAR $\alpha$  activation. *Science of The Total Environment*, 836, 155628.
13. Gu, J., Wang, H., Zhou, L., Fan, D., Shi, L., Ji, G., & Gu, A. (2020). Oxidative stress in bisphenol AF-induced cardiotoxicity in zebrafish and the protective role of N-acetyl N-cysteine. *Science of the Total Environment*, 731, 139190.
14. Gules, O., Yildiz, M., Naseer, Z., & Tatar, M. (2019). Effects of folic acid on testicular toxicity induced by bisphenol-A in male Wistar rats. *Biotechnic & Histochemistry*, 94(1), 26-35.
15. Herath, C. B., Jin, W., Watanabe, G., Arai, K., Suzuki, A. K., & Taya, K. (2004). Adverse effects of environmental toxicants, octylphenol and bisphenol A, on male reproductive functions in pubertal rats. *Endocrine*, 25(2), 163-172.
16. Heidary, M., Vahhabi, S., Nejadi, J. R., Delfan, B., Birjandi, M., Kaviani, H., & Givrad, S. (2008). Effect of saffron on semen parameters of infertile men. *Urology Journal*, 5(4), 255-259.
17. Hosseinzadeh, H., Gholarnreza, K., Maryam, N. (2003). "Antidepressant effect of *Crocus sativus* L. stigma extracts and their constituents, crocin and safranal, in mice." In *I International Symposium on Saffron Biology and Biotechnology*, 650, 435-45.
18. Hosseinzadeh, H., Hamid, R.S. (2005). 'Safranal, a constituent of *Crocus sativus* (saffron), attenuated cerebral ischemia induced oxidative damage in rat hippocampus', *J Pharm Pharm Sci*, 8: 394-99.
19. Hosseinzadeh, H., Modaghegh, M. H., & Saffari, Z. (2009). *Crocus sativus* L.(Saffron) extract and its active constituents (crocin and safranal) on ischemia-reperfusion in rat skeletal muscle. *Evidence-Based Complementary and Alternative Medicine*, 6(3), 343-350.
20. Huang, M., Liu, S., Fu, L., Jiang, X., & Yang, M. (2020). Bisphenol A and its analogues bisphenol S, bisphenol F and bisphenol AF induce oxidative stress and biomacromolecular damage in human granulosa KGN cells. *Chemosphere*, 253, 126707.
21. Jagne, J., White, D., & Jefferson, F. (2016). Endocrine-disrupting chemicals: adverse effects of bisphenol A and parabens to women's health. *Water, Air, & Soil Pollution*, 227(6), 1-10.
22. Karabulut, H., & Gulay, M. S. (2022). Investigation of BPA Toxicity in Male New Zealand White Rabbits. *European Journal of Veterinary Medicine*, 2(2), 6-12.
23. Khayyat, S., Eman, E. (2018). 'Safranal epoxide—A potential source for diverse therapeutic applications', *Saudi pharmaceutical journal*, 26: 115-19.
24. Kianbakht, S., Hajiaghace, R. (2011). 'Anti-hyperglycemic effects of saffron and its active constituents, crocin and safranal, in alloxan-induced diabetic rats', *Journal of Medicinal Plants*, 3: 82-89.
25. Li, J., Nan, S., Ruina, C., Yixing, F., Bing, S., Xuejiang, G., Hongxia, Z., Jiayin, D. (2016). 'Gestational and lactational exposure to bisphenol AF in maternal rats increases testosterone levels in 23-day-old male offspring', *Chemosphere*, 163: 552-61.
26. Lowry, O.H., Nira, J.R., Lewis, F., Rose, J.R. (1951). 'Protein measurement with the Folin phenol reagent', *Journal of biological chemistry*, 193: 265-75.
27. Luna LG (1968). *Manual of Histologic Staining Methods of the Armed Forces Institute of Pathology*. McGraw-Hill Book Co. Newyork, p- 32.
28. Ma, Y., Liu, H., Wu, J., Yuan, L., Wang, Y., Du, X., Wang, R., Marwa, P.W, Petlulu, P., Chen, X., & Zhang, H. (2019). The adverse health effects of bisphenol A and related toxicity mechanisms. *Environmental research*, 176, 108575.



29. Maleki, B.H., Bakhtyar, T., Frank, C.M., Fakhreddin, Y.N., Mehdi, Y. (2016). 'Saffron supplementation ameliorates oxidative damage to sperm DNA following a 16-week low-to-intensive cycling training in male road cyclists', *Journal of Functional Foods*, 21: 153-66.
30. Mardani, M., Ahmad, V., Shahnaz, R. (2014). 'Effect of saffron on rat sperm chromatin integrity', *Iranian journal of reproductive medicine*, 12: 343.
31. Meng, Z., Tian, S., Yan, J., Jia, M., Yan, S., Li, R., ... & Zhou, Z. (2019). Effects of perinatal exposure to BPA, BPF and BPAF on liver function in male mouse offspring involving in oxidative damage and metabolic disorder. *Environmental pollution*, 247, 935-943.
32. Mentor, A., Wänn, M., Brunström, B., Jönsson, M., & Mattsson, A. (2020). Bisphenol AF and bisphenol F induce similar feminizing effects in chicken embryo testis as bisphenol A. *Toxicological Sciences*, 178(2), 239-250.
33. Moreman, J., Lee, O., Trznadel, M., David, A., Kudoh, T., & Tyler, C. R. (2017). Acute toxicity, teratogenic, and estrogenic effects of bisphenol A and its alternative replacements bisphenol S, bisphenol F, and bisphenol AF in zebrafish embryo-larvae. *Environmental science & technology*, 51(21), 12796-12805.
34. National Institute of Health, National Library of Medicine, National Center for Biotechnology Information, (2022). <https://pubchem.ncbi.nlm.nih.gov/compound/70699969> Date of Access: 16.06.2022.
35. Ohkawa, H., Nobuko, O., Kunio, Y. (1979). 'Assay for lipid peroxides in animal tissues by thiobarbituric acid reaction', *Analytical biochemistry*, 95: 351-58.
36. Pandey, K. B., & Rizvi, S. I. (2010). Markers of oxidative stress in erythrocytes and plasma during aging in humans. *Oxidative medicine and cellular longevity*, 3(1), 2-12.
37. Rahaiee, S., Moini, S., Hashemi, M., & Shojaosadati, S. A. (2015). Evaluation of antioxidant activities of bioactive compounds and various extracts obtained from saffron (*Crocus sativus* L.): a review. *Journal of Food Science and Technology*, 52(4), 1881-1888.
38. Rehfeld, A., Andersson, A. M., & Skakkebaek, N. E. (2020). Bisphenol A diglycidyl ether (BADGE) and bisphenol analogs, but not bisphenol A (BPA), activate the CatSper Ca<sup>2+</sup> channel in human sperm. *Frontiers in Endocrinology*, 11, 324.
39. Riaz, A., Pasha, I., Sharif, M. K., & Javaria, S. (2021). Bisphenol A and its Analogues: Human Exposure and Biological Effects-A Review. *Pakistan Journal of Scientific & Industrial Research Series A: Physical Sciences*, 64(2), 173-190. <https://doi.org/10.52763/PJSIR.PHYS.SCI.64.2.2021.173.190>
40. Sadeghnia, H.R., Hamideh, S., Fatemeh, F., Hossein, H. (2017). 'Neuroprotective effect of safranal, an active ingredient of *Crocus sativus*, in a rat model of transient cerebral ischemia', *Folia Neuropathol*, 55: 206-13.
41. Samarghandian, S., Azimi-Nezhad, M., & Samini, F. (2015). Preventive effect of safranal against oxidative damage in aged male rat brain. *Experimental Animals*, 64(1), 65-71.
42. Sarangarajan, R., Meera, S., Rukkumani, R., Sankar, P., & Anuradha, G. (2017). Antioxidants: Friend or foe?. *Asian Pacific Journal of Tropical Medicine*, 10(12), 1111-1116.
43. Schneider, M., Forster, H., Boersma, A., Seiler, A., Wehnes, H., Sinowatz, F., ... & Conrad, M. (2009). Mitochondrial glutathione peroxidase 4 disruption causes male infertility. *The FASEB journal*, 23(9), 3233-3242.
44. Shi, J., Zhihao, J., Sai, Z., Ming, Li., Jing, Z., Yixing, F., Jie, Y., Bing, S. (2015). 'Long-term effects of bisphenol AF (BISFENOL AF) on hormonal balance and genes of hypothalamus-pituitary-gonad axis and liver of zebra (*Danio rerio*), and the impact on offspring', *Chemosphere*, 128: 252-57.
45. Siracusa, J.S., Lei, Y., Emily, M., Shenuxan, L., Xiaozhong, Y. (2018). 'Effects of bisphenol A and its analogs on reproductive health: A mini review', *Reproductive toxicology*, 79: 96-123.
46. Song, M., Liang, D., Liang, Y., Chen, M., Wang, F., Wang, H., & Jiang, G. (2014). Assessing developmental toxicity and estrogenic activity of halogenated bisphenol A on zebrafish (*Danio rerio*). *Chemosphere*, 112, 275-281.
47. Sutherland, V. L., Johnson, C. L., McIntyre, B., Cunney, H., Turner, K., Foster, P. M., & Elmore, S. A. (2019). Reproductive and pathology assessment of bisphenol AF. *Reproductive Toxicology*, 88, 19-20.
48. Tian, F., Li, Q., Shi, L., Li, J., Shi, M., Zhu, Y., ... & Ge, R. S. (2022). In utero bisphenol AF exposure causes fetal Leydig cell dysfunction and induces multinucleated gonocytes by generating oxidative stress and reducing the SIRT1/PGC1 $\alpha$  signals. *Toxicology and Applied Pharmacology*, 116069.
49. Ullah, A., Pirzada, M., Jahan, S., Ullah, H., & Khan, M. J. (2019). Bisphenol A analogues bisphenol B, bisphenol F, and bisphenol S induce oxidative stress, disrupt daily sperm production, and damage DNA in rat spermatozoa: A comparative in vitro and in vivo study. *Toxicology and Industrial Health*, 35(4), 294-303.
50. United States Environmental Protection Agency (EPA), (22 April, 2010). Toxicological Priority Index (ToxPi) as a Platform for Incorporation of Exposure Data for Chemical Prioritization. <https://www.epa.gov/chemical-research/toxicological-priority-index-platform-incorporation-exposure-data-chemical>
51. Vaez, A., Mohammad, M., Shahnaz, R. (2014). 'Impact of saffron on rat sperm membrane integrity and spermatogenesis status', *Advanced biomedical research*, 3.
52. Wang, H. F., Liu, M., Li, N., Luo, T., Zheng, L. P., & Zeng, X. H. (2016). Bisphenol a impairs mature sperm functions by a CatSper-relevant mechanism. *Toxicological Sciences*, 152(1), 145-154.
53. Wu, Di., Chun-Jie, H., Xiao-Fei, J., Zhi-Ming, D., Shou-Xin, Z., Yi-Liang, M., Li-Jun, H. (2019). 'Bisphenol AF compromises blood-testis barrier integrity and sperm quality in mice', *Chemosphere*, 237: 124410.
54. Xiao, X., Mruk, D. D., Wong, C. K., & Yan Cheng, C. (2014). Germ cell transport across the seminiferous epitheli-

um during spermatogenesis. *Physiology*, 29(4), 286-298.

55. Yang, X., Yuchen, L., Jia, L., Minjie, C., Di, P., Yong, L., Maoyong, S., Jie, Z., Guibin, J. (2016). 'Exposure to Bisphenol AF disrupts sex hormone levels and vitellogenin expression in zebra', *Environmental toxicology*, 31: 285-94.

56. Ye, L., Su, Z. J., & Ge, R. S. (2011). Inhibitors of testosterone biosynthetic and metabolic activation enzymes. *Molecules*, 16(12), 9983-10001.

57. Yu, Y., Xin, X., Ma, F., Li, X., Wang, Y., Zhu, Q., Chen, H., Li, H., & Ge, R. S. (2022). Bisphenol AF blocks Leydig cell regeneration from stem cells in male rats. *Environmental Pollution*, 298, 118825.

58. Yusoff, N. A., Budin, S. B., & Taib, I. S. (2017). Pesticide exposures induce male-mediated reproductive toxicity: A review. *J. Agric. Sci*, 9, 122-135.

59. Zhang, Y., Yong, Z., Jianyou, G., Haifeng, C., Sha, L. (2018). 'Anticancer activity of safranin against colon carcinoma is due to induction of apoptosis and G2/M cell cycle arrest mediated by suppression of mTOR/PI3K/Akt pathway', *Journal of BU ON: official journal of the Balkan Union of Oncology*, 23: 574.