

PAPER DETAILS

TITLE: Early-onset neurolupus: A challenge for pediatricians

AUTHORS: Safa BARIS,Elif KARAKOÇAYDINER,Ahmet ÖZEN,Melissa KAÇMAZ,Medya

NAMAR,Nurdan YILDIZ,Dilsat TURKDOGAN,Isil BARLAN

PAGES: 105-108

ORIGINAL PDF URL: <https://dergipark.org.tr/tr/download/article-file/470501>

Early-onset neurolupus: A challenge for pediatricians

Erken başlangıçlı nörolupus: Pediatriye zor tanı

Safa BARIŞ, Elif KARAKOÇ-AYDINER, Ahmet ÖZEN, Melissa KAÇMAZ, Medya NAMAR, Nurdan YILDIZ, Dilşat TÜRKDOĞAN, Işıl BARLAN

ABSTRACT

Systemic lupus erythematosus (SLE) is a challenge for pediatricians due to the heterogeneity of its clinical manifestations and the rarity of the disorder in this age group. Neuropsychiatric SLE (NPSLE) was defined especially in adult patients and the clinical course of this manifestation is still not clearly defined in the pediatric age group. We, here report a five-year old girl presenting with extensive maculopapular skin lesions, oral ulcers and neuropsychiatric symptoms. She had elevated titers of anti-nuclear antibody (ANA), Anti-ds-DNA, anti-histone antibodies and complement levels. Serum coxsackie and cytomegalovirus (CMV) IgM tests were positive, as well. Magnetic resonance imaging (MRI) of the brain demonstrated extended cerebral and cerebellar atrophy. Pediatricians should be attentive to the possibility of neurolupus for patients with neurological problems despite a young age at presentation. Appropriate therapy is a challenging task.

Keywords: Neuropsychiatric lupus, Pediatrics, CMV, Coxsackie

ÖZET

Sistemik lupus eritromatözis (SLE) çocukluk çağında nadir görülmesinin yanında, değişik klinik bulgular ile karşımıza çıkabilmekte ve bu nedenle tanı konulmasında zorluk yaşanmaktadır. Nörolupus erişkin hastalarda daha iyi tanımlanmış klinik tablo iken, çocuk yaş grubunda daha nadir olarak görülür. Beş yaşında kız hasta, yaygın makülopapüler cilt lezyonları, oral ülser, nöropsikiyatrik semptomlar ile kliniğimize başvurdu. Antinükleer antikor (ANA), Anti-ds-DNA ve anti-histon antikor pozitifliğinin yanında, kompleman değerlerinde düşüklük saptandı. Serum coxsackie ve sitomegalovirus (CMV) IgM testleri eş zamanlı pozitif bulundu. Kraniyal magnetik rezonans görüntüleme (MRG)'de serebral ve serebellar atrofi gözlemlendi. Bu olgu sunumuyla, erken dönemde nörolojik bulgular ile SLE'nin klinikte karşımıza çıkabileceği ve viral enfeksiyonların hastalığın patogenezinde rol alabileceği hatırlatılmak istenmiştir.

Anahtar kelimeler: Nöropsikiyatrik lupus, Çocuk, CMV, Coxsackie

Safa Barış (✉), Ahmet Özen, Işıl Barlan

Sub-department of Pediatric Allergy and Immunology, Department of Child Health and Pediatrics, School of Medicine, Marmara University, Istanbul, Turkey
e-mail:safabaris@hotmail.com

Melissa Kaçmaz, Medya Namar

Department of Child Health and Pediatrics, School of Medicine, Marmara University, Istanbul, Turkey

Nurdan Yıldız, Elif Karakoç-Aydiner

Department of Pediatric Nephrology, School of Medicine, Marmara University, Istanbul, Turkey

Dilşat Türkdoğan

Department of Pediatric Neurology, School of Medicine, Marmara University, Istanbul, Turkey

Submitted/Gönderilme: 11.12.2014

Accepted/Kabul: 27.01.2015

Introduction

Systemic lupus erythematosus (SLE) is a chronic autoimmune disease with various system manifestations characterized by episodes of flares and remissions. The median age at onset of symptoms in pediatric SLE is between 11-12 years, with a female predominance being pronounced after puberty [1]. Neuropsychiatric manifestations can occur in 22-95% of pediatric cases, being much less frequent as an initial presenting symptom [2]. Symptoms of central nervous system (CNS) involvement range from poor school performance, depressive moods and difficulty to concentrate up to seizures, psychosis and stroke. The presence of specific antibodies to neurons, or intracytoplasmic parts of neurons (anti ribosomal P, anti Ro; SS-A or anti-La; SS-B) may support CNS involvement [3].

A role in the occurrence or the exacerbation of SLE has been suggested for infections with various viral pathogens

including Epstein-Barr virus (EBV), cytomegalovirus (CMV) and parvovirus B19 [4]. However, an argument concerning the mechanisms involved is unresolved. We, hereby describe a 5-year-old girl with an atypical presentation of neuropsychiatric SLE.

Case Report

A five-year-old girl was admitted to our hospital showing signs of lethargy, lack of verbal communication, inability to walk, loss of sleep and appetite for 2 days. She was reported to have had a febrile episode and weight loss (8 kg) during the previous 2 months. The family reported skin rashes, which initially appeared on cheeks two months ago, with extension to upper and lower extremities including the palms and soles; these were unresponsive to topical steroids.

Physical examination revealed oral ulcers; on the palate, buccal mucosa and tongue, in addition to macules and papules on cheeks, palms and soles (Figure 1 A-C). Vital signs were within the normal range (respiratory rate: 18/min., heart rate: 105/min, blood pressure: 92/62 mmHg) except for a sub-febrile body temperature (37.8°C). Neurological examination at first glance showed irritability, lack of speech and eye contact with a depressed mood. She had bilateral spasticity and brisk deep tendon reflexes in the lower extremities, ankle clonus and a positive Babinski response. Her past medical history revealed normal developmental milestones. Biochemical examination revealed leukopenia ($3100/\text{mm}^3$ ($<5000/\text{mm}^3$)), lymphopenia ($1100/\text{mm}^3$ ($<1500/\text{mm}^3$)), anemia (Hb: 8.4 mg/dl and MCV: 75 FL) and thrombocytopenia (PLT: $65.000/\text{mm}^3$). Acute phase reactants were remarkably elevated (ESR: 134 mm/hour, CRP: 17 mg/dl (<5 mg/dl)). Coagulation parameters were normal. Serum electrolytes and renal function tests were all within the normal range while, liver enzymes (AST: 164 IU, ALT: 78 IU) were high and serum albumin low (albumin: 2.9 mg/dl). Urine analyses and sediment showed no proteinuria, hematuria or cellular casts at admission. A lumbar puncture

was performed, showing normal cerebrospinal fluid (CSF) protein and glucose levels and negative culture (bacterial culture, mycobacterium and fungus) results. CSF polymerase chain reaction (PCR) testing for Herpes virus, enterovirus and tuberculosis were also negative. Blood cultures for aerobic and anaerobic bacteria, Brucella spot and Wright agglutination and Quantiferon tests were all negative. Serum IgM titers for Herpes virus type I and II, enterovirus, parvovirus B19, Ebstein - Barr virus were all negative. Meanwhile, antibodies against CMV, coxsackie A and B viruses were positive with weak titers. Based on these findings, a viral infection was not thought to explain the whole clinical picture. Therefore, in order to search for a suspected neurological involvement of SLE autoimmune markers were checked. Immune fluorescence assay revealed positive ANA dilution at 1/160 titration with a homogenous pattern. In addition, rheumatoid factor (134 UI/ml positive (<20 UI/ml)), anti-ds DNA and anti-histone antibodies were found to be positive. Screening of antiphospholipid antibodies including lupus anticoagulant, the Venereal Disease Research Laboratory (VDRL), IgM and IgG tests, anticardiolipin, antiphospholipid and anti beta2 glycoprotein and anti-Smith antibodies were all negative. Serum complement levels were in the low range (C3:0.17 g/L (<0.75 g/L), C4:0.03 (<0.1 g/L). A 24-hour urinary protein excretion test was performed, with a normal result (3.8 mg/ m^2/hr) initially, which turned out be elevated in the following week (20 mg/ m^2/hr). Magnetic resonance imaging (MRI) of brain showed diffuse cerebral and cerebellar atrophy, whereas MRI angiography and diffusion were within normal limits (Figure 2). Minimal left ventricular dilatation without effusion was detected in echocardiography in the presence of a normal cardiothoracic ratio, electrocardiogram and CK-MB. A renal biopsy revealed type 4 diffuse proliferative glomerulonephritis. She received pulse methylprednisolone treatment at a dose of 30 mg/kg/day for five consecutive days, followed by oral prednisone 2mg/kg/day, with a

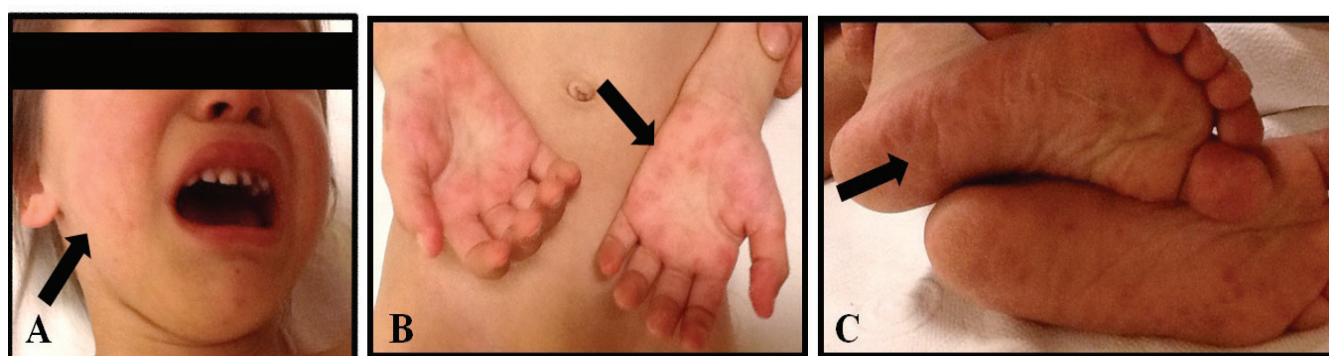


Figure 1A-C. Exanthema of the skin A: face, B: palms, C: soles.

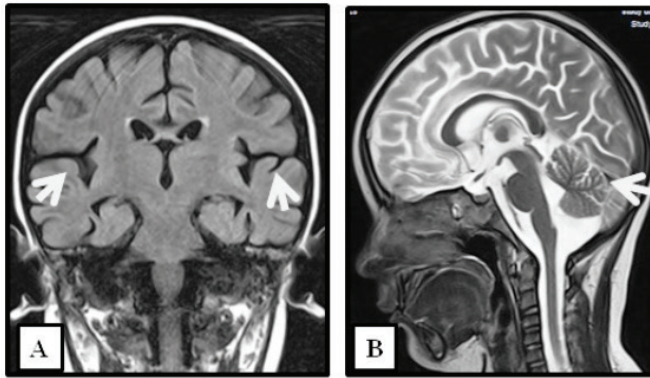


Figure 2A-B. Atrophy of A: the cerebrum and B: the cerebellum on the magnetic resonance imaging of the brain.

tapering scheme thereafter, the maintenance of which did not reveal any significant neurological improvement. At that point a high dose intravenous immunoglobulin (1gr/kg/day for twice) along with cyclophosphamide (at a cumulative dose of 160 mg/kg) was started. Interestingly, there was a prompt improvement in her neurological symptoms right after IVIG infusion; she was able to communicate verbally, manage comprehensive tasks and maintain an erect position. At the end of the 2nd week of treatment the fever and rash had subsided, she was able to speak fluently and walk with help. In addition to immunosuppressive treatment, hydroxychloroquine (3mg/kg/day) was used for skin involvement. In line with the resolution of clinical findings, a decrease in acute phase reactants and increase in serum complement levels were noted.

Discussion

Neuropsychiatric SLE (NPSLE) refers to neurological and psychiatric syndromes occurring in patients with lupus at any time during the course of the disease, not attributable to other causes [5]. The condition is considered in the differential diagnosis of many conditions in pediatric practice. Among the diagnostic procedures autoantibodies serve only as clues in addition to nonspecific findings in neurological imaging. Since no single test is diagnostic for NPSLE, the clinician should be extremely careful at the initial evaluation to look for any possible neurological symptoms, which may be quite subtle. Depending on the part of the CNS involved, symptoms and manifestations are variable and can occur in 22-95% of pediatric cases. However, they are rare as an initial presenting complaint [2, 6]. Our patient, five-year old female, is interesting in that her disease started at quite an early age. Despite vigorous treatment, the response was partial, with some neurological sequela.

In the absence of a high index of suspicion, detection of

IgM antibodies to coxsackie A, B and CMV in the setting of a presentation suggestive of a viral illness might have obscured the diagnosis of lupus at the outset. This finding per se, obviously, is not likely to explain the whole clinical picture. In this patient, however, it is not known whether this finding had an implication in terms of a possible role of these viruses in the induction or aggravation of the immune process or simply related to cross-reactivity with high levels of rheumatoid factor [7].

It has been suggested that several factors including vasculitis, apoptosis, production of autoantibodies to neuronal antigens, to ribosomes or phospholipids and inflammations secondary to the local cytokine production play role in the pathogenesis of neuropsychiatric SLE. Specific antibodies directed at neurons and intracytoplasmic parts of neurons (anti-ribosomal P, anti Ro; SS-A or anti-La; SS-B) may be related to CNS involvement [3]. It is noteworthy that these antibodies in our patient were negative.

Recently, systemic or chilblain lupus manifesting in early childhood have been reported. These were caused by heterozygous mutations in the genes encoding 3' repair exonuclease (TREX1) or the phosphohydrolase sterile alpha motif domain and HD domain containing protein 1 (SAMHD1). TREX1 is the major intracellular DNase with specificity for single-stranded DNA. TREX1 deficiency leads to an accumulation of intracellular nucleic acids. It is hypothesized that these nucleic acids act as danger signals and activate innate immune sensors, leading to a type 1 interferon response that favors the development of autoimmunity. Biallelic or heterozygous de novo TREX1 mutations cause Aicardi Goutieres syndrome, an inflammatory leukoencephalopathy that features signs of systemic autoimmunity [8, 9]. For this reason, cutaneous or systemic lupus findings with early onset should be thought of as type 1 interferonopathies. In this regard, we plan to investigate the causative gene mutation in our patient.

In patients with pediatric lupus with a younger onset anti-ribosomal antibodies have previously been found to be specifically associated with depression and psychosis [10]. Although, lympho-cytotoxic antibodies (LCAs) have been suggested as a marker in patients especially with cognitive and visual spatial defects [11] none of these qualified as a diagnostic test for neuropsychiatric SLE in current practice. In addition to these markers, marked lymphopenia was mentioned as an independent risk factor associated with a neuropsychiatric manifestation, and this was also apparent in our patient at the initial presentation [12]. The role of advanced neuroimaging modalities such as single photon

emission computed tomography (SPECT) to uncover structural and metabolic abnormalities in brain regions having a normal appearance on conventional MRI has also been examined, but with no further assistance in diagnosis or prognosis of neurolupus [13].

Atypical manifestations of SLE at presentation and early onset kidney or CNS diseases have been associated with poor outcomes [14]. Hence, the management of patients with lupus nephritis or NPSLE includes aggressive immunosuppressive therapy. For refractory NPSLE, intravenous immunoglobulin, plasmapheresis, and rituximab have been used successfully [15, 16]. Indeed, the patient presented here initially received five cycles of pulsed steroid, with no significant improvement. Interestingly, a prompt response in CNS symptoms was achieved by the infusion of a high dose IVIG. Meanwhile, nephritis was treated with long term steroids and concomitant cyclophosphamide.

In conclusion, SLE in a young child presenting with neurological symptoms is unusual, and can only be diagnosed on the basis of a high index of suspicion. A watchfull monitoring with serial clinical examinations can uncover subtle alterations which aid in making the diagnosis. High doses of IVIG in our patient appeared beneficial for the neurological symptoms, which had responded poorly to conventional therapy. The optimal treatment strategies for this rare disease in childhood deserve further attention.

References

1. Descloux E, Durieu I, Cochat P, et al. Influence of age at disease onset in the outcome of paediatric systemic lupus erythematosus. *Rheumatology (Oxford)* 2009; 48: 779-84.
2. Ferraria N, Rocha S, Fernandes VS, et al. Juvenile systemic lupus erythematosus with primary neuropsychiatric presentation. *BMJ Case Rep* 2013; 2013: 1 - 4. doi: 10.1136/bcr-2012-008270.
3. Sibbitt WL Jr, Brandt JR, Johnson CR, et al. The incidence and prevalence of neuropsychiatric syndromes in pediatric onset systemic lupus erythematosus. *J Rheumatol* 2002; 29: 1536-42.
4. Kasapcopur O, Ergul Y, Kutlug S, et al. Systemic lupus erythematosus due to Epstein-Barr virus or Epstein-Barr virus infection provoking acute exacerbation of systemic lupus erythematosus? *Rheumatol Int* 2006; 26: 765-7.
5. Fietta P, Fietta P, Delsante G. Psychiatric and neuropsychological manifestations of systemic lupus erythematosus. *Acta Biomed* 2011; 82: 97-114.
6. Yu HH, Lee JH, Wang LC, et al. Neuropsychiatric manifestations in pediatric systemic lupus erythematosus: a 20-year study. *Lupus* 2006; 15: 651-7. doi:10.1177/0961203313502110.
7. Pérez-Mercado AE, Vilá-Pérez S. Cytomegalovirus as a trigger for systemic lupus erythematosus. *J Clin Rheumatol* 2010; 16: 335-7. doi: 10.1097/RHU.0b013e3181f4cf52
8. Abdel-Nasser AM, Ghaleb RM, Mahmoud JA, et al. Association of anti-ribosomal P protein antibodies with neuropsychiatric and other manifestations of systemic lupus erythematosus. *Clin Rheumatol* 2008; 27: 1377-85. doi: 10.1007/s10067-008-0921-1.
9. Günther C, Hillebrand M, Brunk J, Lee-Kirsch MA. Systemic involvement in TREX1-associated familial chilblain lupus. *J Am Acad Dermatol* 2013; 69: 179-81. doi:10.1016/j.jaad.2013.04.020.
10. Lee-Kirsch MA. Nucleic acid metabolism and systemic autoimmunity revisited. *Arthritis Rheum* 2010; 62: 1208-12. doi: 10.1002/art.27372.
11. Denburg SD, Behmann SA, Carbotte RM, et al. Lymphocyte antigens in neuropsychiatric systemic lupus erythematosus. Relationship of lymphocyte antibody specificities to clinical disease. *Arthritis Rheum* 1994; 37: 369-75.
12. Yu HH, Wang LC, Lee JH, et al. Lymphopenia is associated with neuropsychiatric manifestations and disease activity in paediatric systemic lupus erythematosus patients. *Rheumatology (Oxford)*. 2007; 46: 1492-94.
13. Russo R, Gilday D, Laxer RM, et al. Single photon emission computed tomography scanning in childhood systemic lupus erythematosus. *J Rheumatol* 1998; 25: 576-82.
14. Taddio A, Rossetto E, Rosé CD, et al. Prognostic impact of atypical presentation in pediatric systemic lupus erythematosus: results from a multicenter study. *J Pediatr* 2010; 156: 972-7. doi: 10.1016/j.jpeds.2009.12.022.
15. Popescu A, Kao AH. Neuropsychiatric systemic lupus erythematosus. *Curr Neuropsychopharmacol* 2011; 9: 449-57. doi: 10.2174/157015911796557984.
16. Fanouriakis A, Boumpas DT, Bertsias GK. Pathogenesis and treatment of CNS lupus. *Curr Opin Rheumatol* 2013; 25: 577-83. doi: 10.1097/BOR.0b013e3283636eaf1.